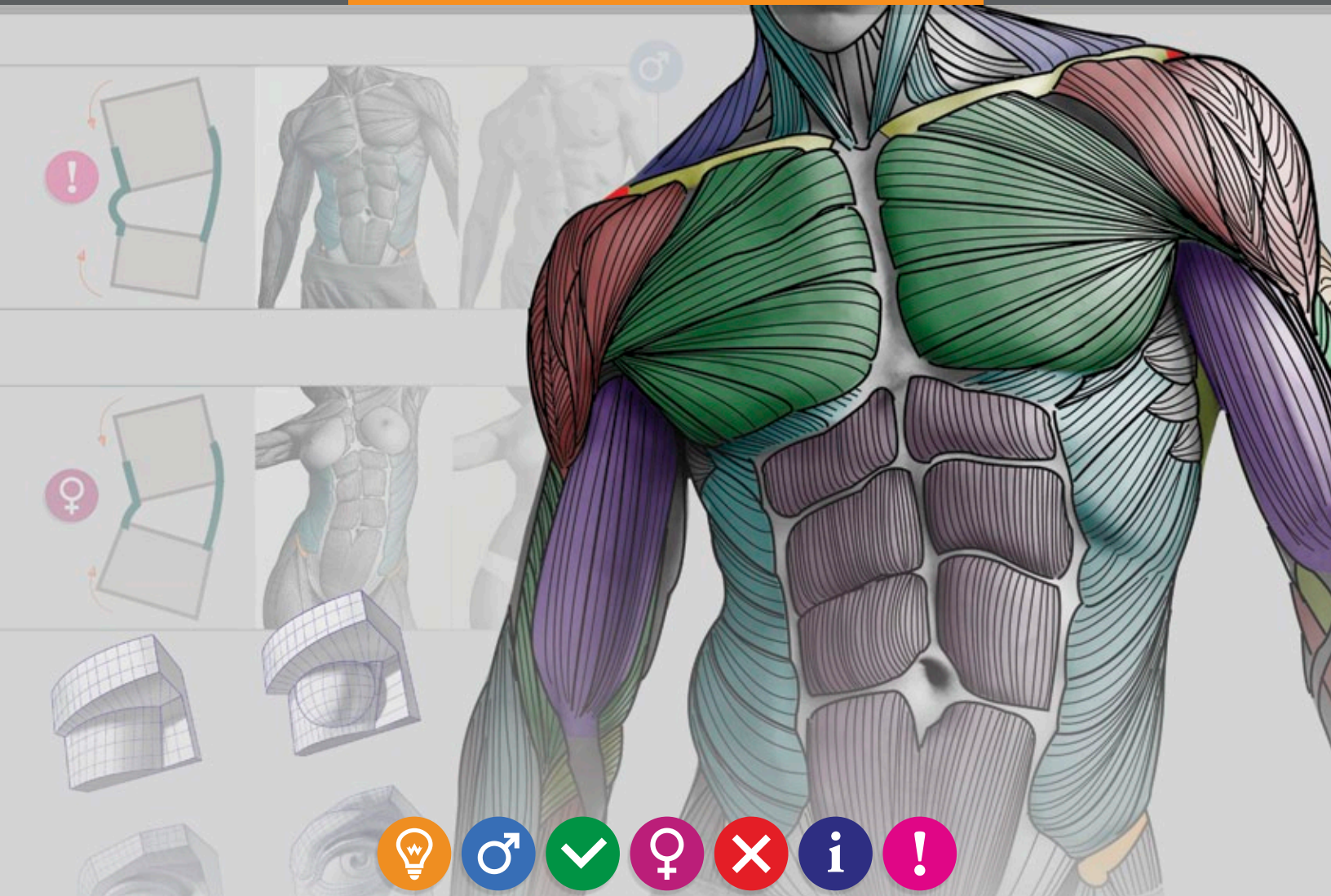


ULDIS ZARINS
WITH
SANDIS KONDRATS

ANATOMY FOR SCULPTORS

UNDERSTANDING THE HUMAN FIGURE



FOR PERSONAL USE ONLY OF GOMESH KARNCHANAPAYAP, 10/56 TOWNPLUS RAMA 9 KRUNGTHEP KREETHA, BANGKOK 10240
ALL RIGHTS RESERVED BY EXONICUS LLC

www.ebook777.com

ULDIS ZARINS
WITH
SANDIS KONDRATS

ANATOMY_{FOR} SCULPTORS

UNDERSTANDING THE HUMAN FIGURE

2014

Author and Designer: Uldis Zarins
Project Director: Sandis Kondrats
Layout and Graphic Designer: Edgars Vegners
Photography: Sabina Grams
Editor: Johannah Larsen
Proofreading and Editing: Monika Hanley
3D scanning: Chris Rawlinson (3dscanstore.com)
3D sculpting: Sergio Alessandro Servillo (page 99)

Copyright 2014 EXONICUS, LLC

All rights reserved. This book is protected by copyright.
No part of this book may be reproduced in any form or by any means, including photocopying, or utilized by any information storage and retrieval system without written permission from the copyright owner.

Printed in USA

First Edition, 2014

The publishers have made every effort to trace the copyright holders for borrowed material. If they have inadvertently overlooked any, they will be pleased to make the necessary arrangements at the first opportunity.

To purchase additional copies of this book,
call our customer service department at (310) 869-9952
Visit anatomy4sculptors.com

ABOUT, HISTORY, BACKGROUND

High Hopes

At the beginning of the 1990s, on the ruins of the USSR, in the newly formed Latvian nation, a young person, named Uldis Zarins, full of ideals and hopes, dreamed of becoming a sculptor. In 1994, he was accepted to the Art College of Riga. Studies were difficult and competition was fierce, but they resulted in satisfaction. Every day he replicated famous classical Greek portraits, busts, and figures in clay. The outlook prevailed, that frequent replication of antique sculptures would facilitate the understanding of form creation. After only half a year, Uldis understood that eyes, of course, adapt, and hands become more agile; however, understanding of the form did not materialize.

The Cheek of the Amazon

One day, when replicating the head of the Amazon portrait of famous sculptor Polykleitos, he ran into a problem: How to construct a cheek? It was clear that the form was not just a sphere, but several complicated forms combined. He thought: "It would be great to understand what these forms are and how they go together!"

Teachers only discouraged, saying: "Study, research, measure!" – But what to measure, when there aren't even any corners, nor facets!? A teacher answered: "Study anatomy, maybe you'll get by somehow."

First Anatomy Studies

A modeling teacher told Uldis: "If you want to understand everything, here is a human skull and anatomy book. Study and create an écorché for us!" Uldis decided to create a bust with shoulders. All of its muscles were in place, however, the sculpture looked bad. The main thing was that his understanding of the form had not increased one bit! In the place of the form, he had studied muscles.

In digging through a mountain of anatomy books, Uldis realized that they were all meant for painters and drawers. He found that all of these books were equally boring, with scant, chaotic drawings. "No one, it turns out, has thought about sculptors!" Uldis found only one anatomy book, which only slightly touched on the form -- Gottfried Bammes' *Der nackte Mensch*. Then he asked himself the question: "Why are there so few pictures in the books and so much text!"

Academy Studies

After college, Uldis enrolled in the Art Academy of Latvia (Latvijas Makslas Akadēmija). There, same as in college, emphasis was placed on exercises, not on the understanding of how to create the form. Each time Uldis created a new sculpture, he made preparations, not only to arrange the frame and the edge, but also drew a small paper sketch where he could analyze the form in an understandable way.

Over the course of several years, drawings, sketches, anatomy books and successful photographs were accrued. Uldis began to notice, that the sketches he had created, as well as images, were in high demand among colleagues. He often heard the suggestion that he should collect them all and publish a book, which would be a composite of form analysis, as well as fundamental information about anatomy that sculptors would need to know. This was how Uldis came up with the idea for the creation of the book.

Kickstarter

Years went by and Uldis created the website anatomy4sculptors.com, a proportion calculator, and Facebook page, where he publishes anatomy reference images and his drawings. On the Facebook page, Uldis engaged in conversations and tested the ways of explaining the human anatomy. In the spring of 2013, with the help of friend Sandis Kondrats, a Kickstarter campaign was organized, creating an international team, with whose help Uldis realized his dream of publishing the book, *Anatomy for Sculptors*. During the project development phase, Sandis and Uldis were joined by friends from Latvia, Sabina Grams and Edgars Vegners, who contributed with their expertise in Graphic Design and Photography. With much help from Sandis' brother Janis Kondrats, we were able to create a unique subscription system on the website to engage and test the book's content with the project supporters. As English is a second language for Uldis and Sandis, the assistance of editors and proofreaders, Monika Hanley and Johannah Larsen, was indispensable. Friendships, created through the project with Chris Rawlinson and Sergio Alessandro Servillo, filled in the blanks with 3D scans and sculpt reference materials. The Shutterstock service, which supplied Uldis with a lot of great artwork to build on the book's content, was also a great help. Thanks to the friends of the international sand sculpting community, with whom Uldis and Sandis had conversations about the book during their travels over the course of the year, which was a great help in the book's development process. The support of the Seattle Latvian community was very special while working on the project. Also, without the support and understanding of the families and friends of Uldis and Sandis, this project would not have been possible.

Finally, the book has come into physical form after hard and passionate work over the course of 20 years, since Uldis came up with the dream of creating such a book. It took him 11 years of classical art studies, over 200 international sculpting festivals, symposiums and exhibitions in 9 years and the past 4 years spent on reading books, researching human anatomy, and creating illustrations for this book to come to life.


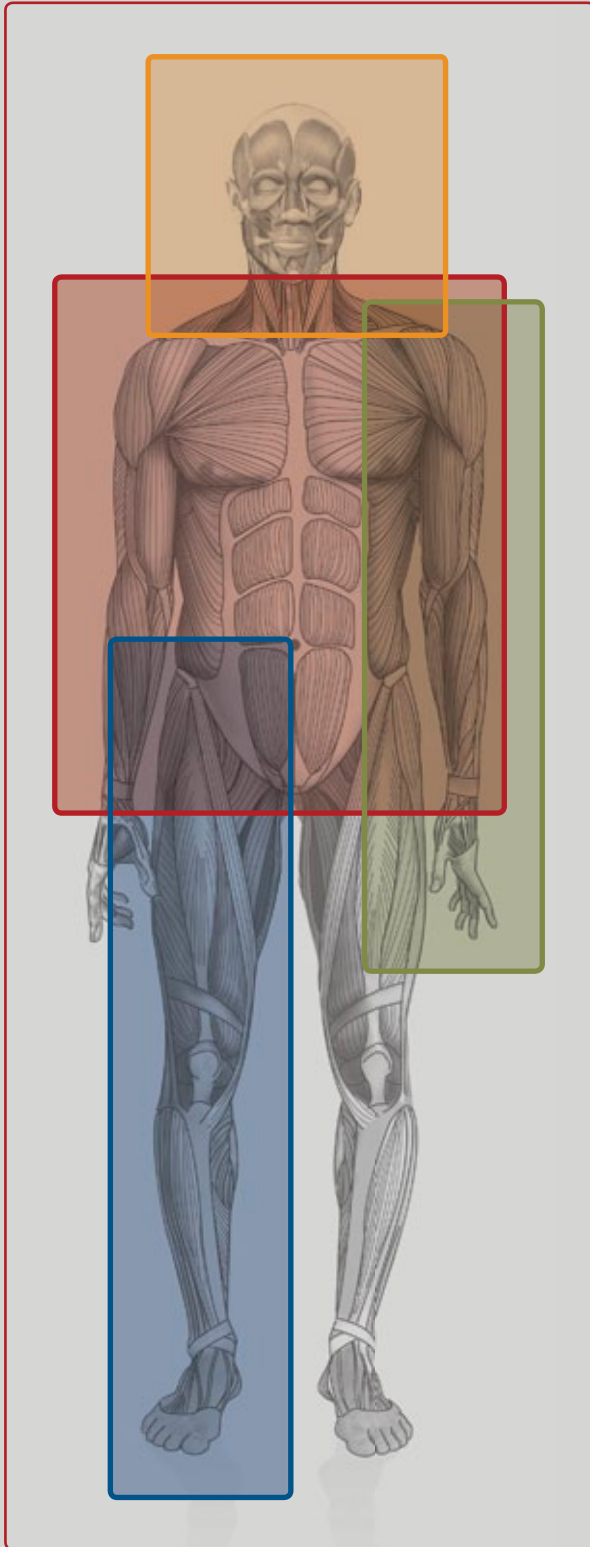
SUMMARY

FIGURE & TORSO	7	UPPER LIMB	143
SKELETON	8-12	HAND AND WRIST MUSCLES	144-145
MALE VS FEMALE SHAPES	13-14	HAND AND WRIST BONES	146
SILHOUETTE	15	MUSCLES OF UPPER LIMB	147
CONTRAPPOSTO	16	SUPINATION AND PRONATION	148-153
LAZY "S"	17	PARTIALLY FLEXED ARM	154
MOVABLE MASSES	18-19	BICEPS AND TRICEPS	155-159
REALISTIC TO SIMPLIFIED	20-21	BRACHIALIS AND CORACOBRAHIALIS	160-161
ANGULAR RELATIONSHIP	22	BRACHIORADIALIS AND EXTENSOR CARPI	
HORIZONTAL CROSS SECTIONS	23	RADIALIS LONGUS	162-163
ÉCORCHÉ AND REAL	24-25	ANCONEUS, EXTENSOR CARPI ULNARIS,	
MUSCLES AND LANDMARK POINTS	26-27	EXTENSOR DIGITI MINIMI AND EXTENSOR	
ABDOMINAL MUSCLES	28-29	DIGITORUM	164
MOST IMPORTANT MUSCLES	30-32	SUPINATION AND PRONATION	165
CLAVICLE	33	FLEXOR MUSCLES	166-168
CHEST MUSCLES	34-36	ABDUCTOR POLLICIS LONGUS AND EXTENSOR	
FEMALE BREAST	37-40	POLLICIS BREVIS	169
SHOULDER MUSCLE	41-45	ULNA	170
TRAPEZIUS MUSCLE	46-47	ARMS CONNECTION	171
SERRATUS ANTERIOR	48-49	BLOCKING OUT ARM	172-173
BROADEST MUSCLE OF THE BACK	50-51	HANDY TIPS	174-175
GREAT ROUND MUSCLE, LITTLE ROUND MUSCLE		FINGERS	176
AND INFRASPINATUS MUSCLE	52	PROPORTIONS	177
ABDOMINAL EXTERNAL OBLIQUE MUSCLE	53	HAND	178
HIPS	54	SHAPING HAND AND FINGERS	179
BUTT	55	HAND MOVEMENTS	180
SUBCUTANEOUS FAT PADS	56-59	WRIST POSITIONS	181
OBESE PROPORTIONAL CHANGES	60-61	FINGERS	182
FAT ACCUMULATION	62	AGING HANDS	184
3D SCAN	63-71		
ARMS REFERENCE	72-88	LOWER LIMB	185
SHOULDER BLADES	89	BONES	186-187
PROPORTIONS	90-92	MUSCLES	188-189
		3D SCAN	190-191
HEAD & NECK	93	BONY LANDMARKS	192-194
SKULL BONES	94	MALE LEG SHAPES	195
MUSCLES	95-97	QUADS	196
SKULL	98-99	SARTORIUS MUSCLE	197
HEAD SHAPE AND MASSES	100	ADDUCTOR MUSCLES OF THE HIP	198
BABY HEAD	101	FLEXORS OF THE THIGH	199
HEAD SHAPE	102	CALVES	200-201
EYES	103-109	EXTENSOR DIGITORUM LONGUS AND TIBIALIS	
JAW	110	ANTERIOR MUSCLES	202
MOUTH	111-116	PERONEUS BREVIS AND PERONEUS LONGUS	
PLATYSMA MUSCLE	117	MUSCLES	203
STERNOCLEIDOMASTOID MUSCLE	118	TIPS	204
NECK MUSCLES	119-120	CROSS SECTION	205
EAR	121	KNEE MECHANICS	206
NOSE	122-123	THE KNEE	207
FACIAL MUSCLES	124	3D SCAN	208-210
WRINKLES	125	FEMALE LEGS	211
PROPORTIONS	126-130	LEG SHAPES	212
GENDER DIFFERENCES	131	3D SCAN	213
EMOTIONS	132-142	TRAVERSING	214
		ADDITIONAL SHAPES	215
		FOOT MUSCLES	216
		FOOT SHAPES	217-219
		3D SCAN	220-221
		BABY FEET	222

THANKS TO
KICKSTARTER
AND 384 SUPPORTERS FROM ALL OVER THE WORLD!

SPECIAL THANK YOU:

Aiman Akhtar
Alexander Jack Ware
Amazin' Walter
Amy Medford and Leonid Siveriver
Andrew Plumb
Barbara C Brown
Bassanimation
Bert Adams
Brent Baxter
Carlos NCT
Damon Langlois
Digital Double
Dominic Qwek
Douglas Heitz
Dr. Patricia Beckmann Wells and Petey
Electric Geisha LLC
Elisabeth
Frost Holliman
Gerhard Schellert
Hasan Bajramovic
J. Quincy
Jason Hill
Jeanne Young
Jeff Strong
Jerome Ranft
Jessica Dru
Jino van Bruinessen
Josh Ruiz
Karen Jean Fralich
Kasper Appel
Kirk Rademaker
Kristopher Vita
Kurt Papstein
Lee Hutt FNSS
Martijn Rijerse and Hanneke Supply
Martin de Zoete
Miguel Guerrero
Nick Sho Ito and zbrushhangout community
Peet Lee
Peter Redmond
Pucheu-planté cédric
Rachel M. Brown
Raffaele Pisoni
Rob Macko
Roger Geraedts
Rusty Croft
Saitou Takeshi
Sandi "Castle" Stirling
Scott
Solomon Temowo
Steven R. Berkshire
Thomas Stanton
Toban Magee
Warren Marshall
www.Stijgerart.nl
Wyeth Johnson



**FIGURE
& TORSO**

7



**HEAD
& NECK**

93



UPPER LIMB

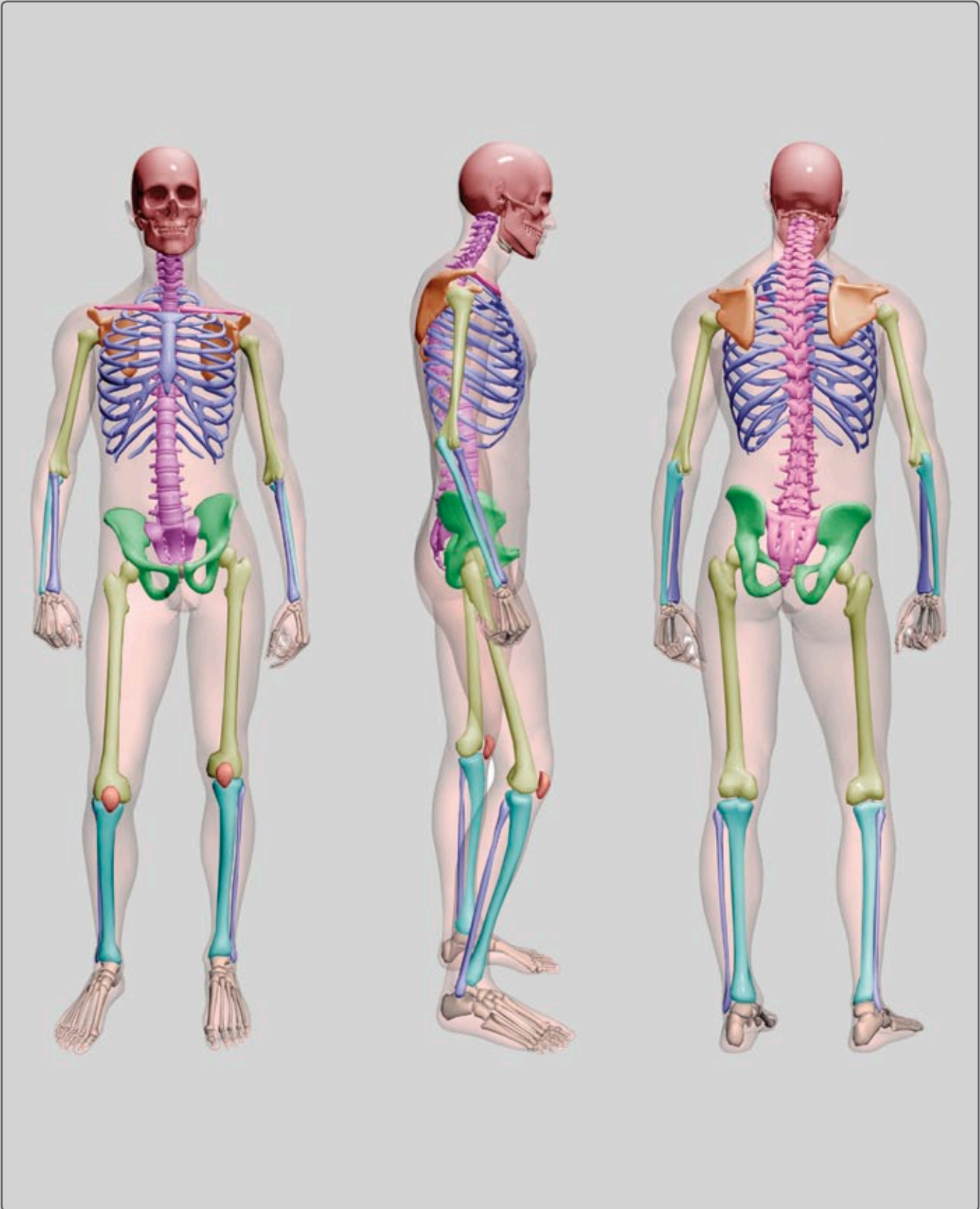
143



LOWER LIMB

185

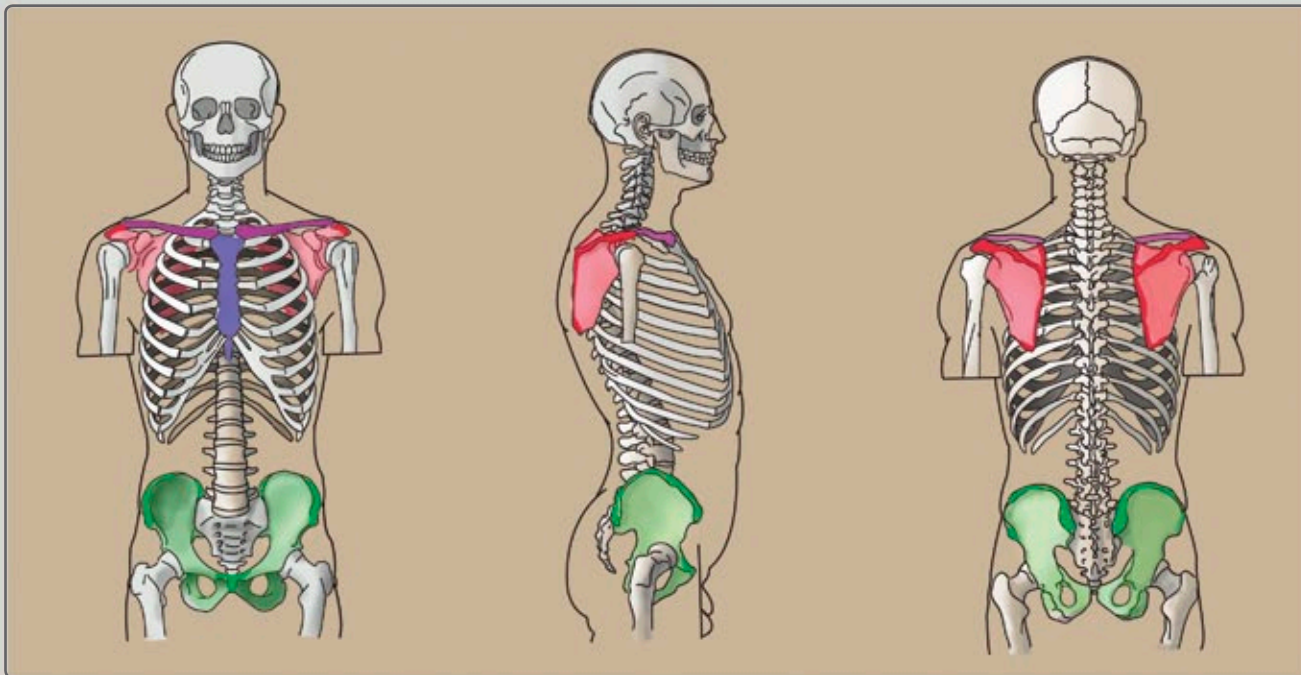
HUMAN SKELETON



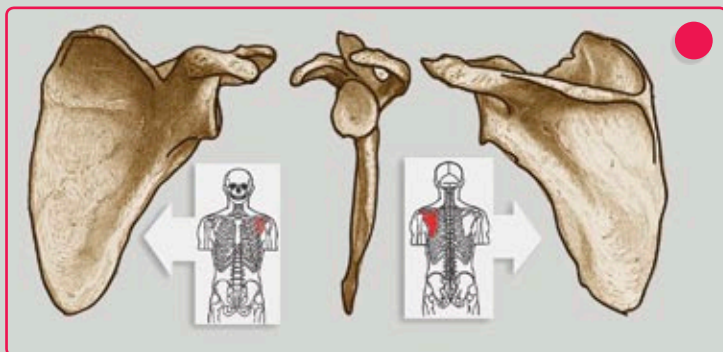
IMPORTANT LANDMARKS OF TORSO



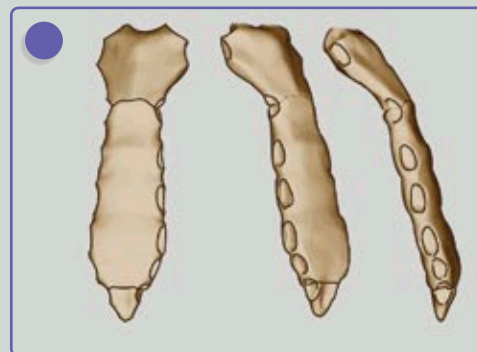
PROMINENT SUBCUTANEOUS PROTRUSIONS – GENERALLY POINTS OF BONE, THOUGH SOMETIMES FORMED BY ENTIRE BONES, ARE CALLED BONY LANDMARKS OR SIMPLY LANDMARKS. THEY MAY SERVE AS IMPORTANT PROPORTIONAL MEASURING POINTS OF THE BODY. LANDMARKS ARE THE KEY TO UNDERSTANDING THE EXACT POSITION OF THE ENTIRE SKELETON, WHICH FOR THE MOST PART IS EMBEDDED IN THE SOFT TISSUES OF THE BODY.



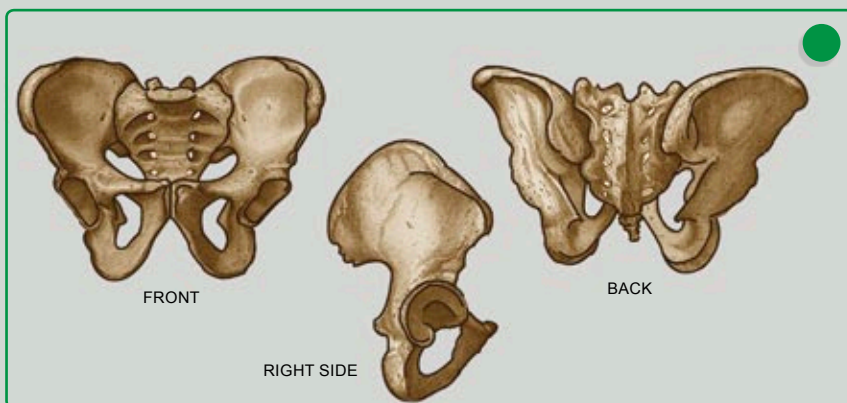
SHOULDER BLADE (SCAPULA)



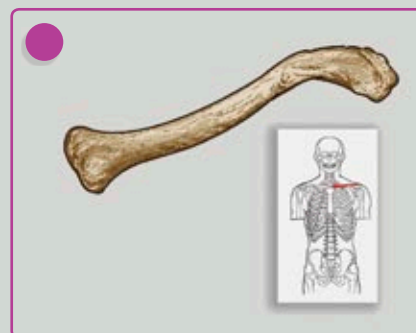CHEST BONE (STERNUM)



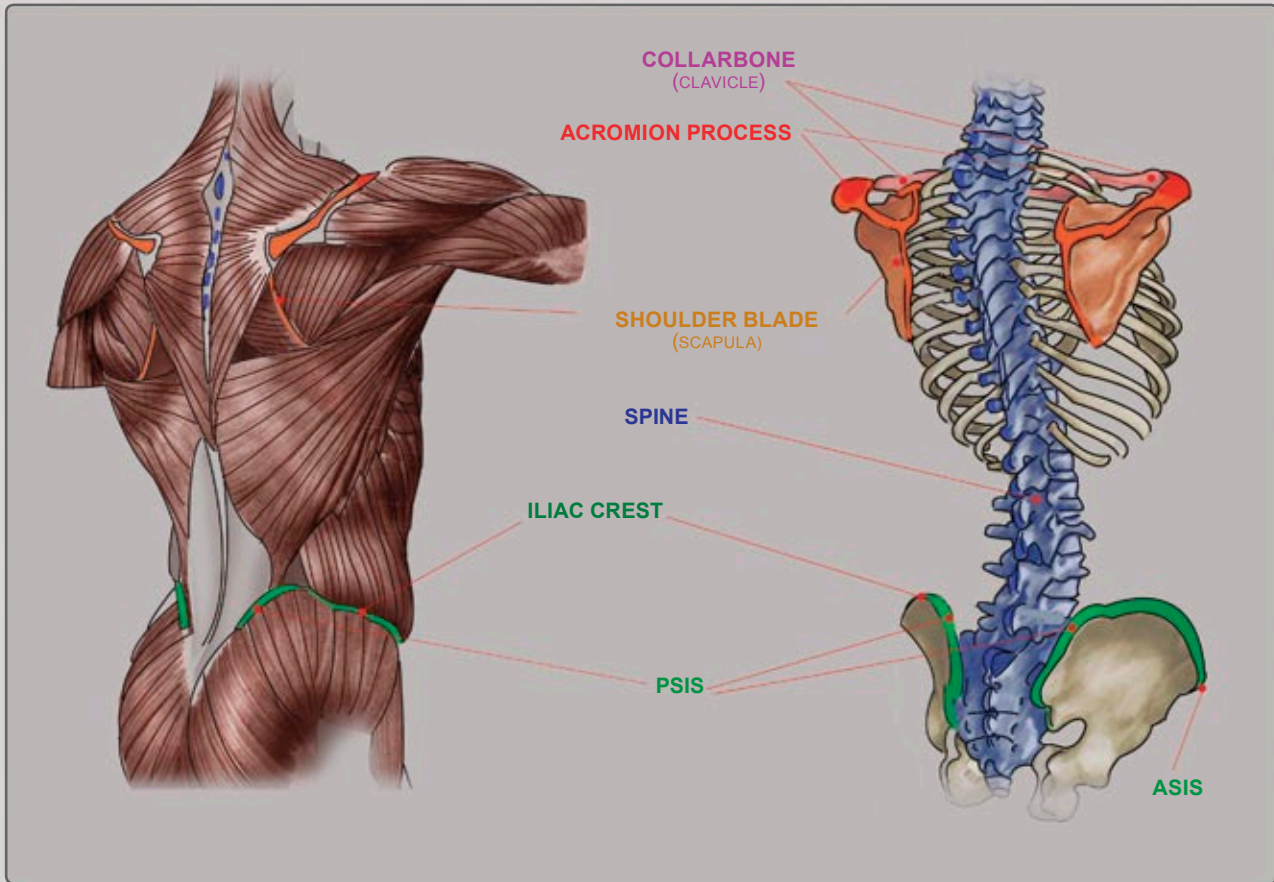
PELVIS



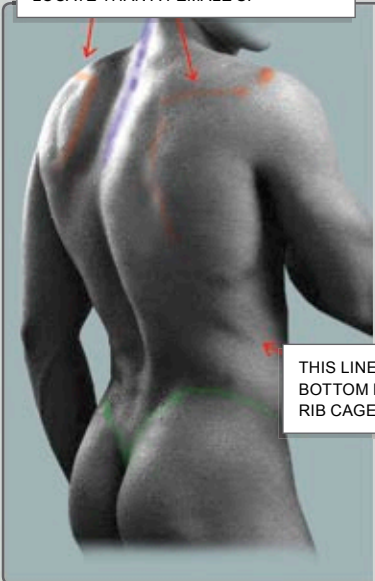
CLAVICLE



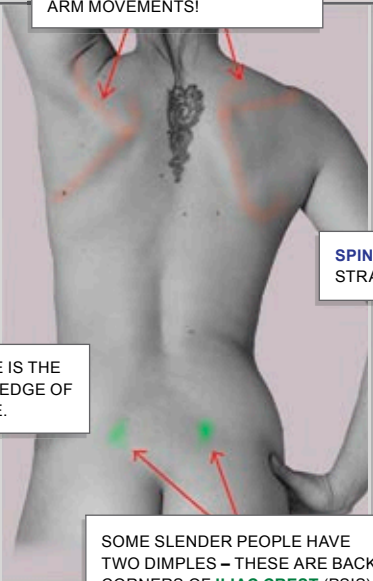
MAIN LANDMARKS OF BACK OF THE TORSO



THE MALE'S **SHOULDER BLADE** IS COVERED BY A THICK LAYER OF MUSCLES AND IS HARDER TO LOCATE THAN A FEMALE'S.



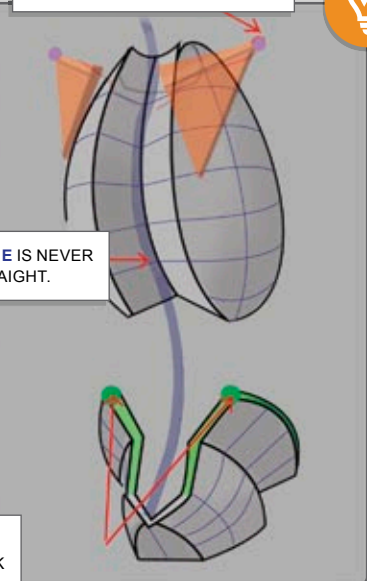
PAY ATTENTION TO POSITION OF **SHOULDER BLADE** DURING ARM MOVEMENTS!



THIS LINE IS THE BOTTOM EDGE OF RIB CAGE.

SOME SLENDER PEOPLE HAVE TWO DIMPLES – THESE ARE BACK CORNERS OF **ILIAC CREST (PSIS)**.

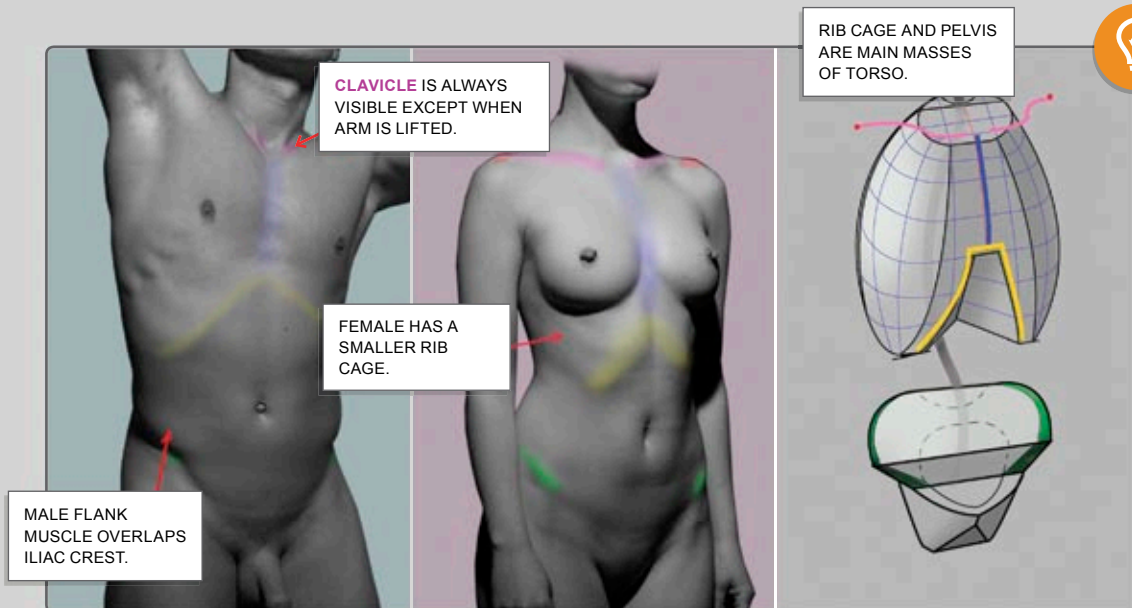
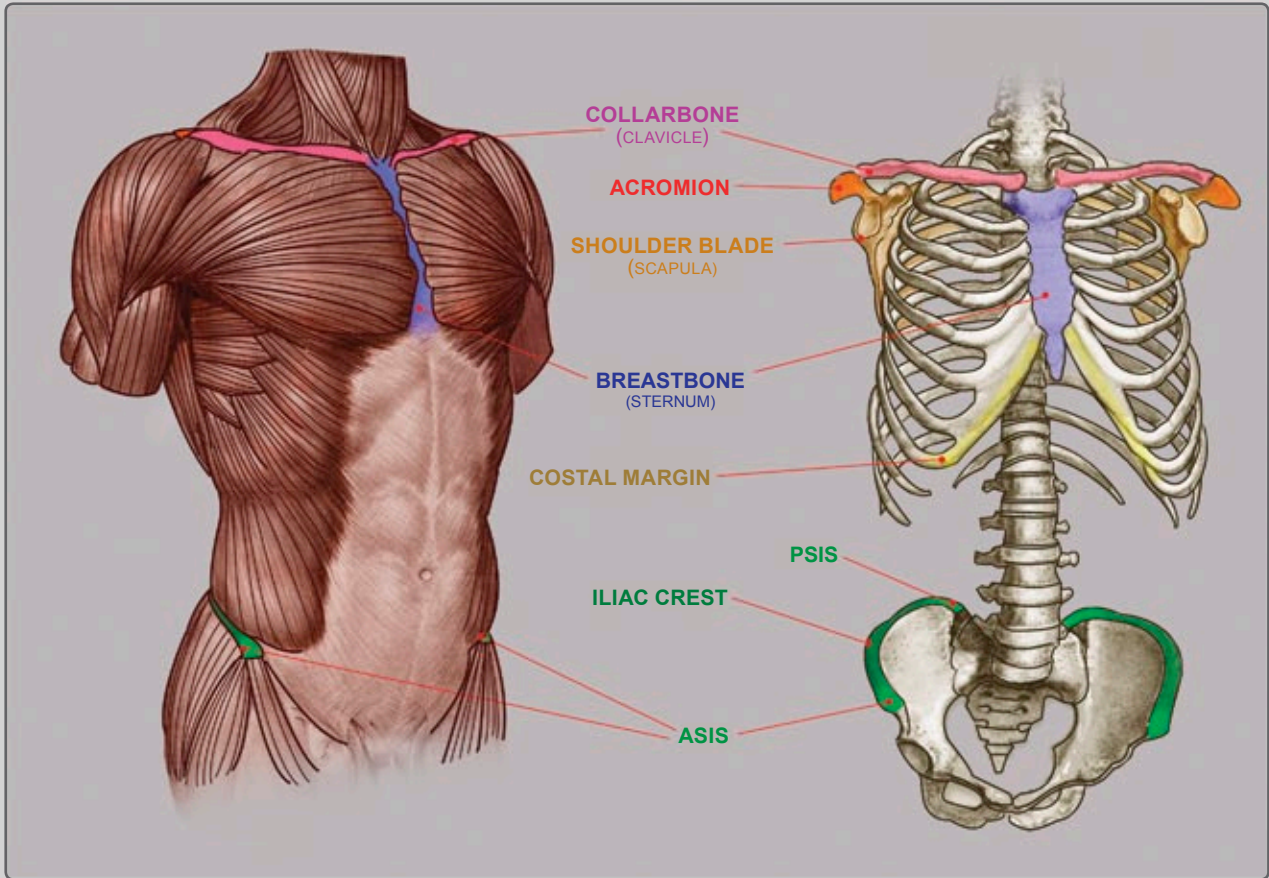
AC JOINT IS WHERE **CLAVICLE** MEETS **ACROMION**.



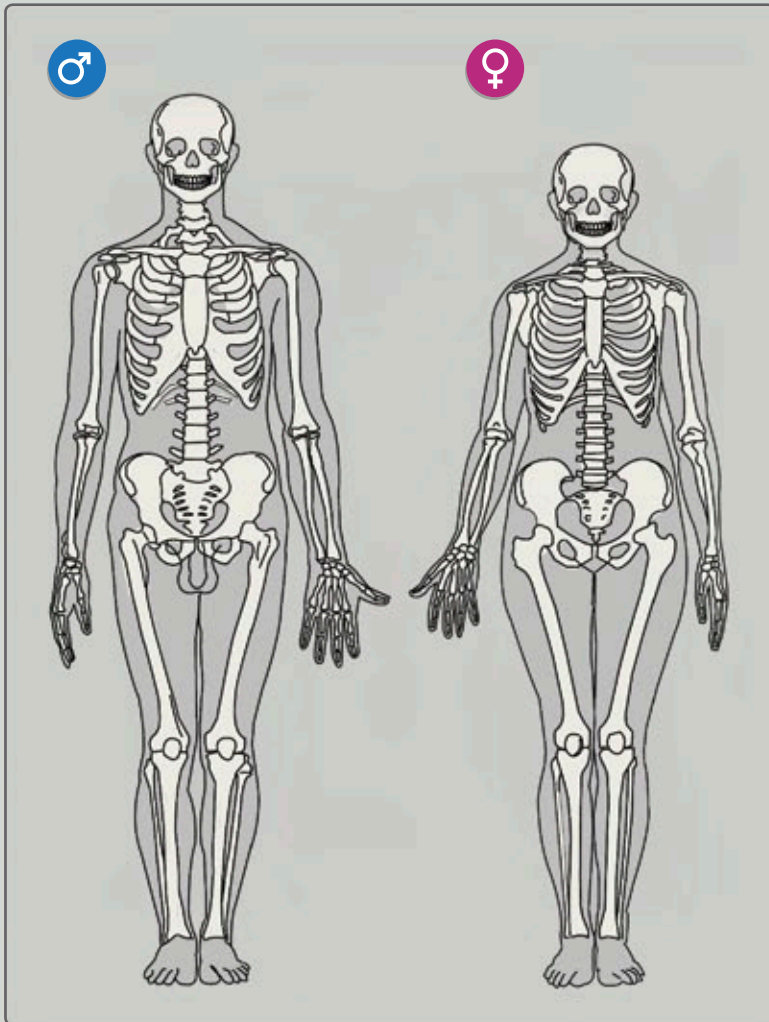
SPINE IS NEVER STRAIGHT.



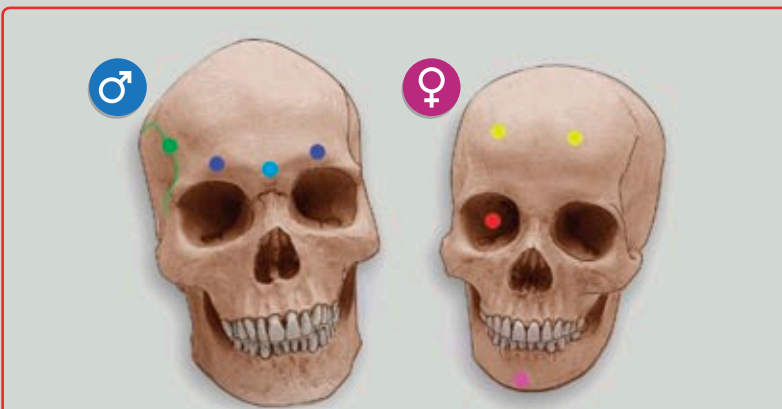
MAIN LANDMARKS OF FRONTAL TORSO



MAIN DIFFERENCES BETWEEN MALE AND FEMALE SKELETONS

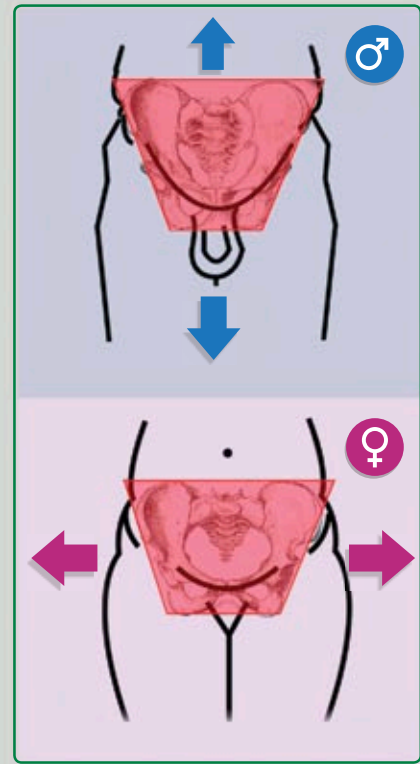


SKULL

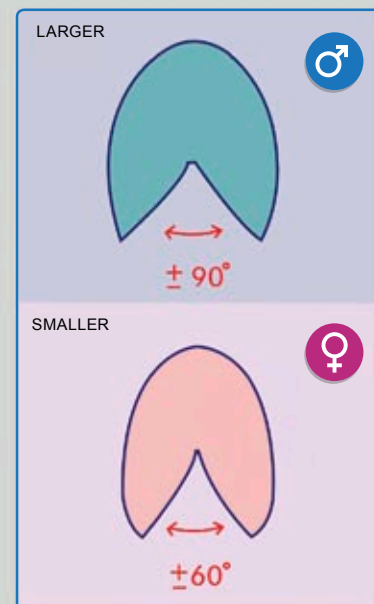


- FOREHEAD:** MALE SKULLS HAVE MORE PROMINENT **GLABELLA** AND **SUPRAORBITAL RIDGES**
- TEMPLE:** MALE SKULLS HAVE MORE PROMINENT **TEMPORAL LINES**
- EYE ORBITS:** FEMALE SKULLS HAVE ROUNDER **ORBITS**
- JAWS:** FEMALE **JAWS** ARE NARROWER AND ROUNDER
- FRONTAL:** FEMALE SKULLS HAVE LARGER **FRONTAL EMINENCES**

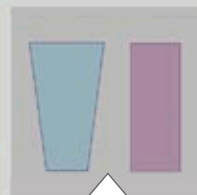
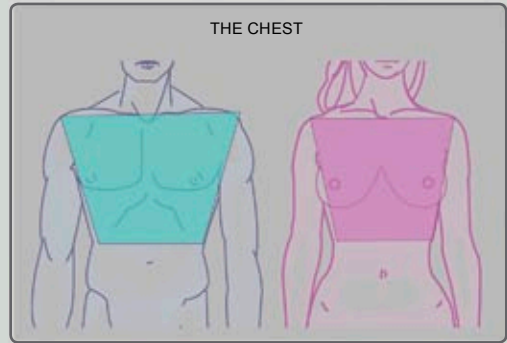
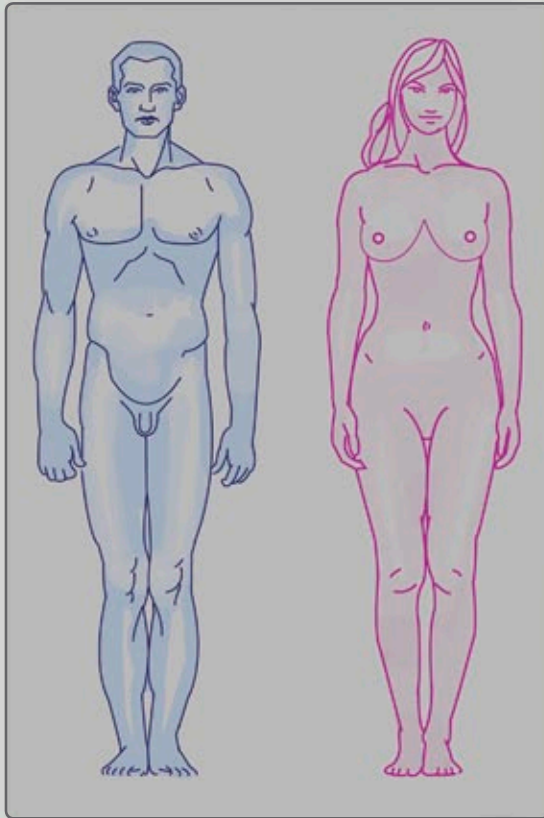
PELVIS



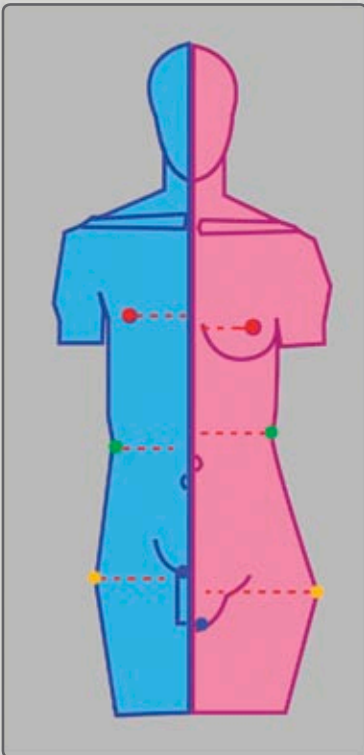
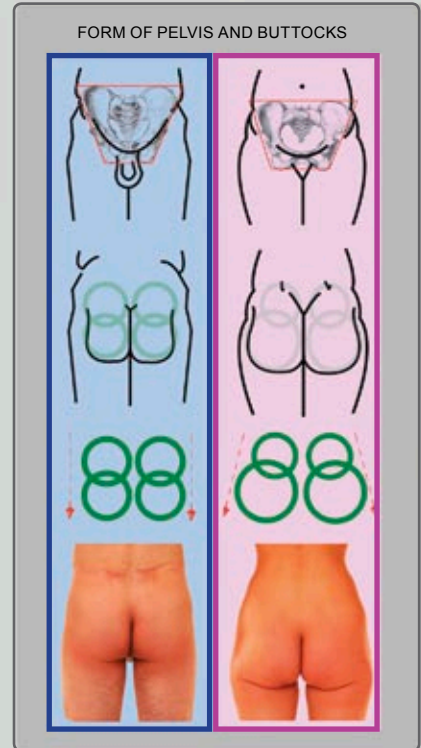
RIB CAGE



MOST IMPORTANT DIFFERENCES BETWEEN MALE AND FEMALE BODY SHAPES

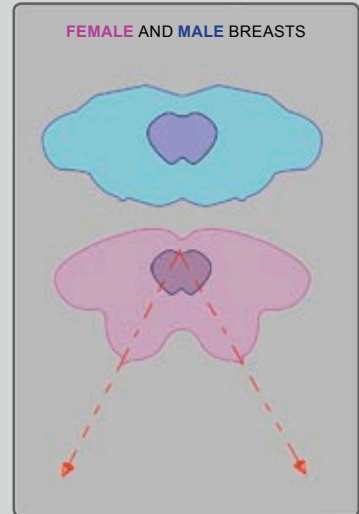
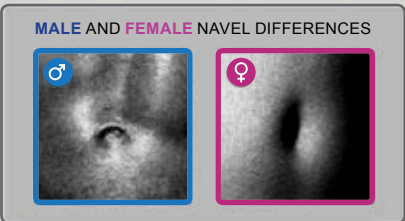


NOTE:
DIFFERENCE IN SILHOUETTE AT SHOULDERS AND HIPS.

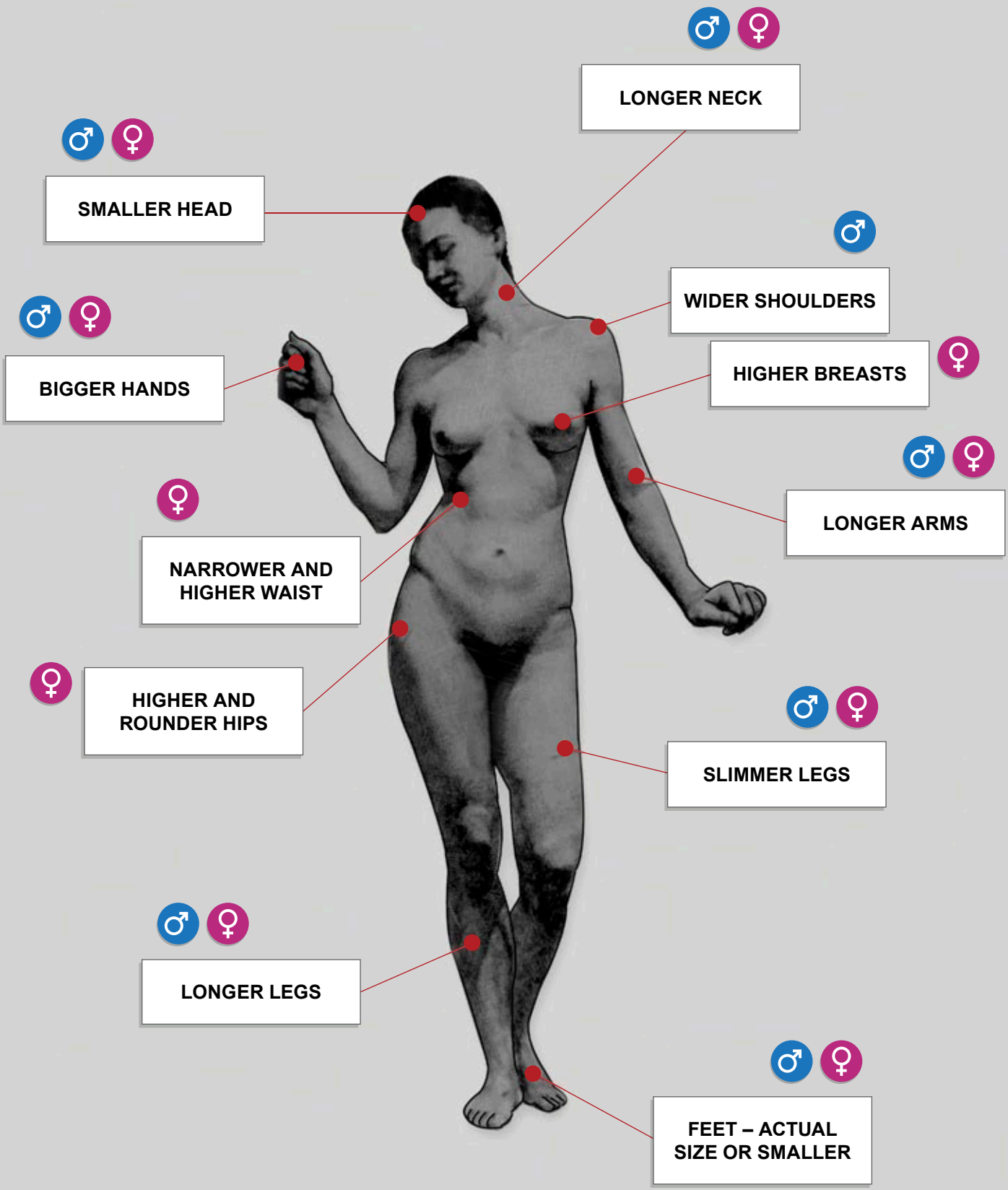


FEMALE FORMS ARE SOFTER AND CURVILINEAR. MALE FORMS ARE MORE ANGULAR.


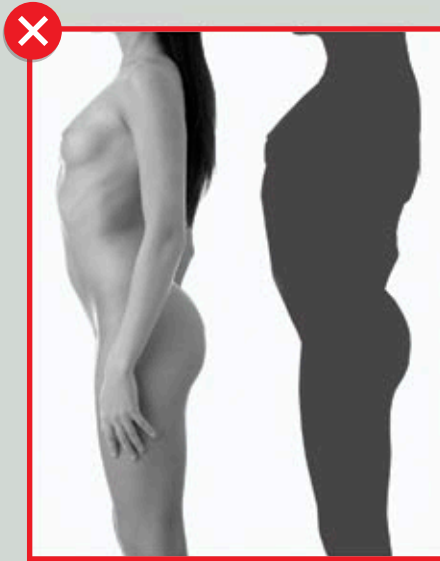
FEMALE HAS SLIGHTLY THICKER SUBCUTANEOUS FAT THAN MALE.





HOW TO MAKE A FIGURE MORE ATTRACTIVE



SILENT KILLER





THE MOST ESSENTIAL ELEMENTS IN FIGURE SCULPTURE NEED TO BE FAR ENOUGH FROM THE BODY. IF YOU CAN'T EASILY DISTINGUISH YOUR CHARACTER BY SILHOUETTE ALONE, THEN RECONSIDER THE COMPOSITION! AN UNCLEAR SILHOUETTE IS THE "SILENT KILLER" OF DESIGN!




ANOTHER KILLER IS **SYMMETRY**! SYMMETRICAL FIGURE SEEMS LIFELESS AND BORING.

CONTRAPPOSTO

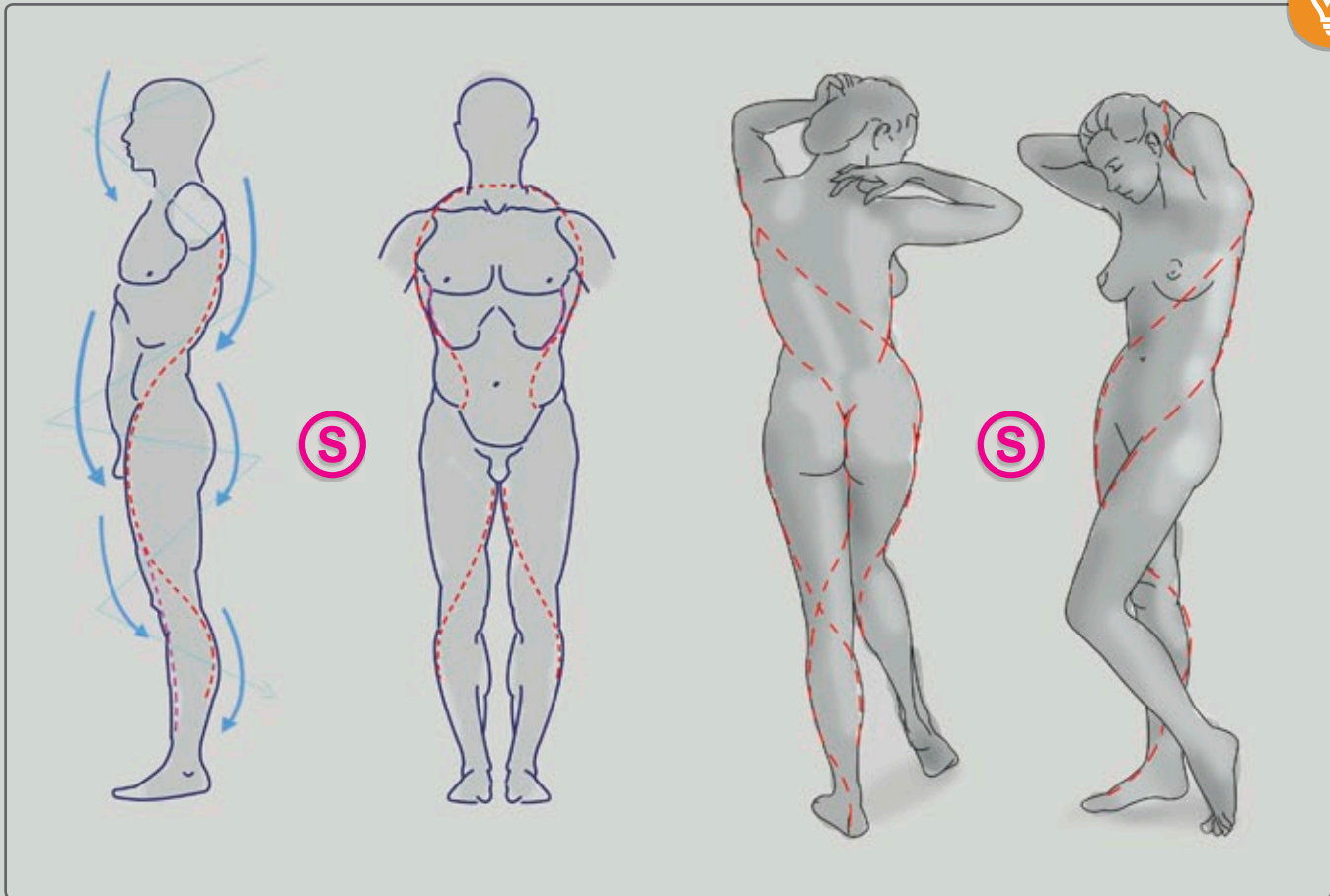
THIS TERM DESCRIBES THE POSITION OF A FIGURE IN WHICH THE HIPS AND LEGS ARE TURNED IN A DIFFERENT DIRECTION FROM THAT OF THE SHOULDERS AND HEAD; THE FIGURE TWISTS ON ITS OWN VERTICAL AXIS. THE FIGURE'S BODY AND POSTURE IS DEPICTED AS A SINUOUS OR SERPENTINE "S" SHAPE.



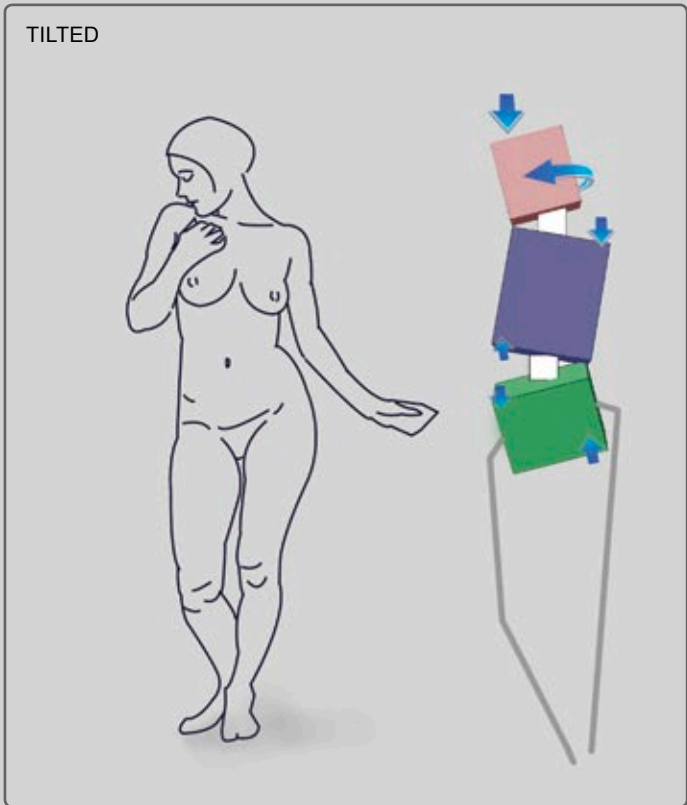
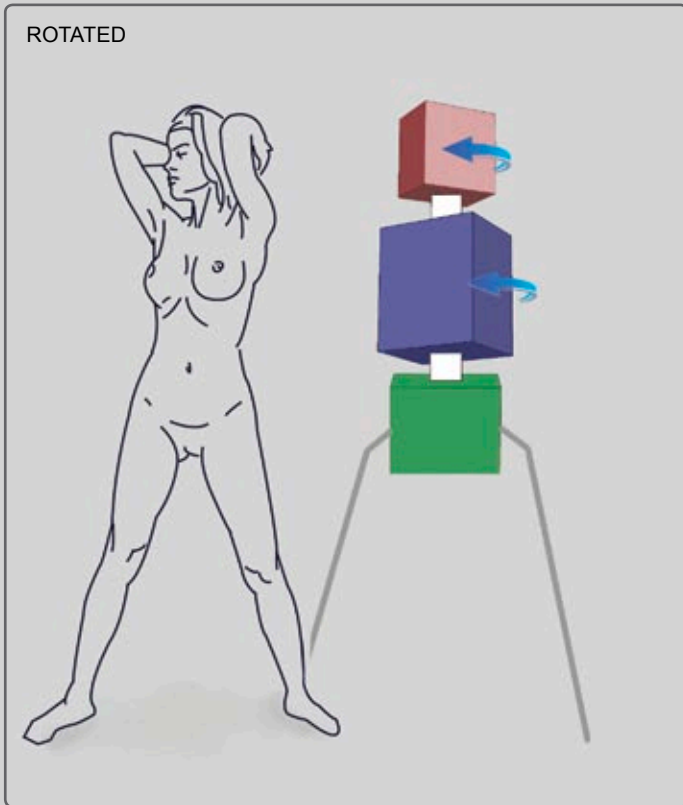
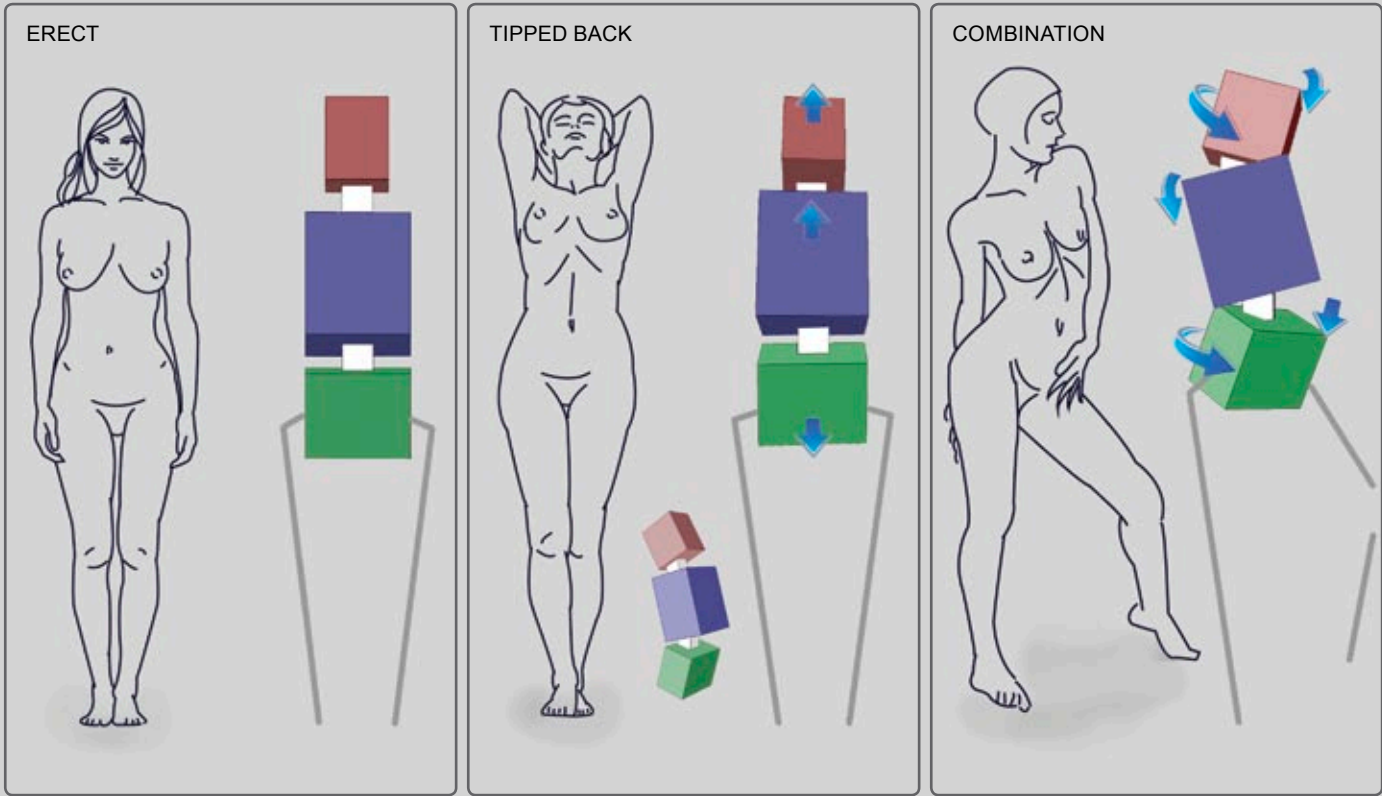
LAZY "S"



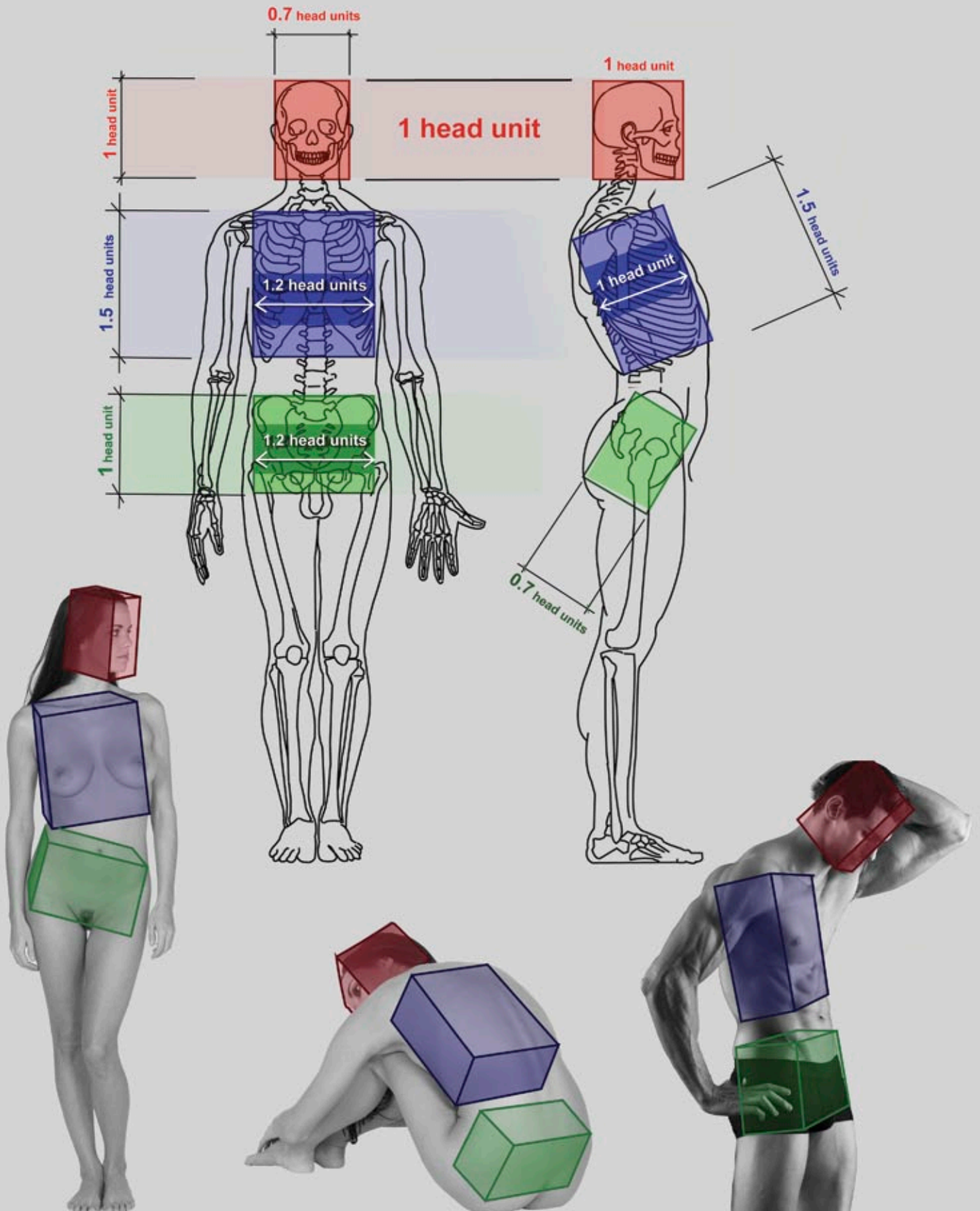
DRAW IMAGINARY S-SHAPED LINES AND BY FOLLOWING THEM, YOU CAN EASILY CONSTRUCT THE CURVES OF THE BODY.



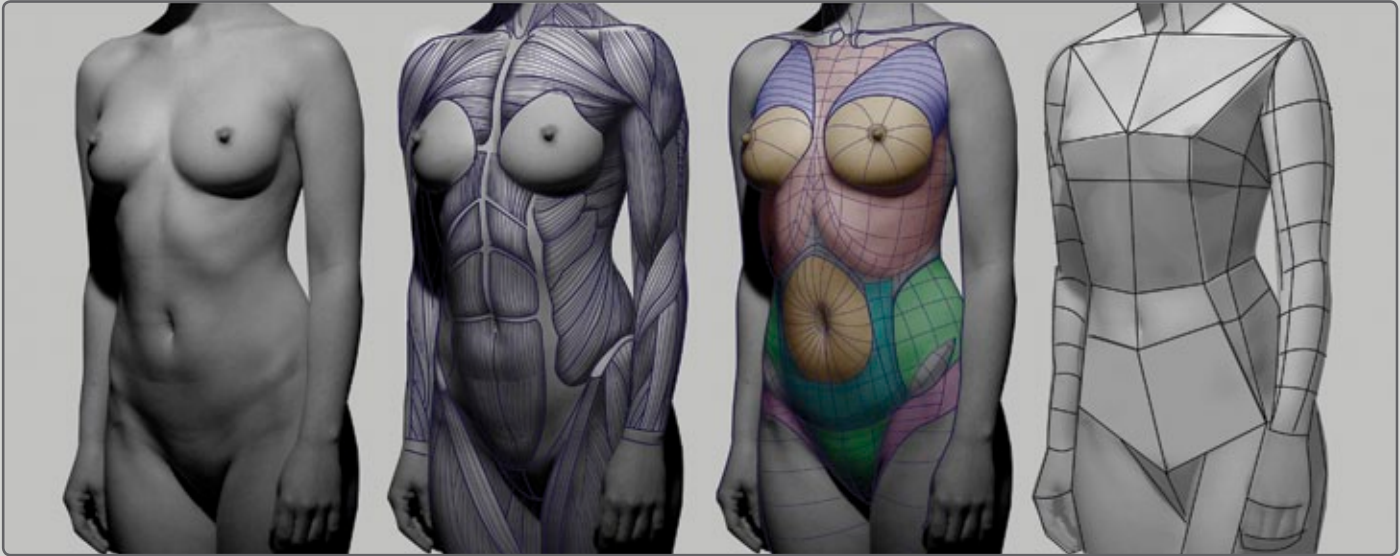
5 POSITION COMBINATIONS OF MOVABLE MASSES



PROPORTIONS IN HEAD UNITS OF MOVABLE MASSES



FEMALE TORSO FROM REALISTIC TO SIMPLIFIED

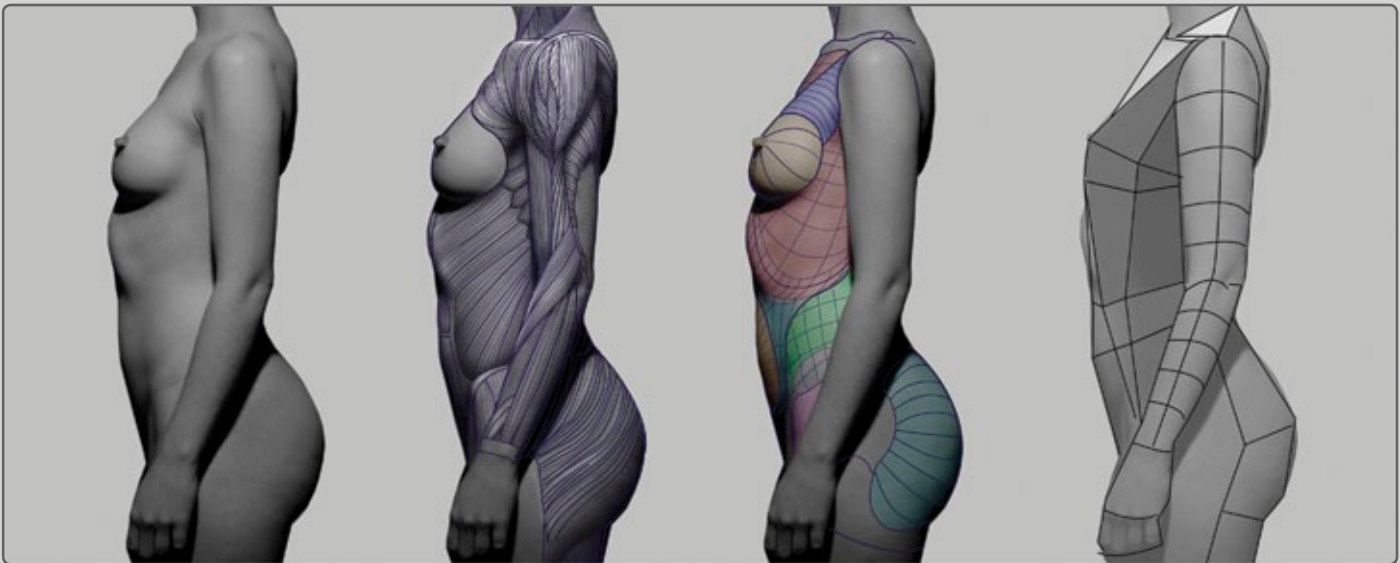


REAL

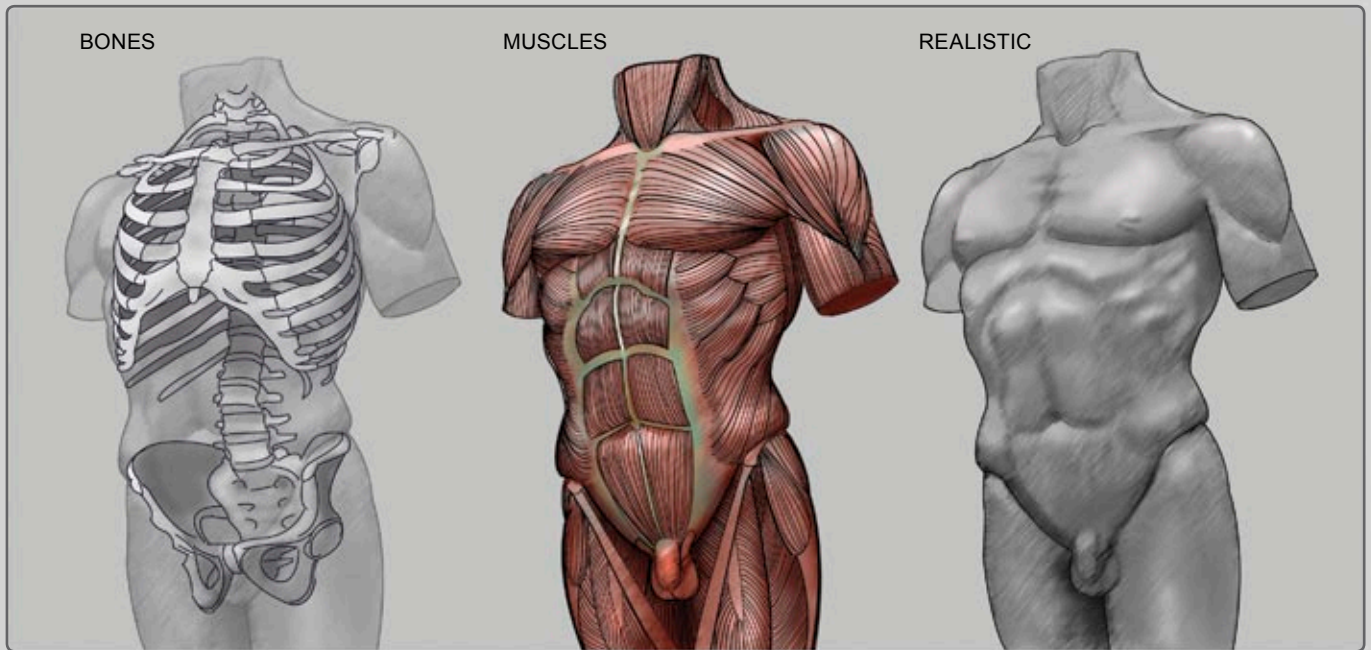
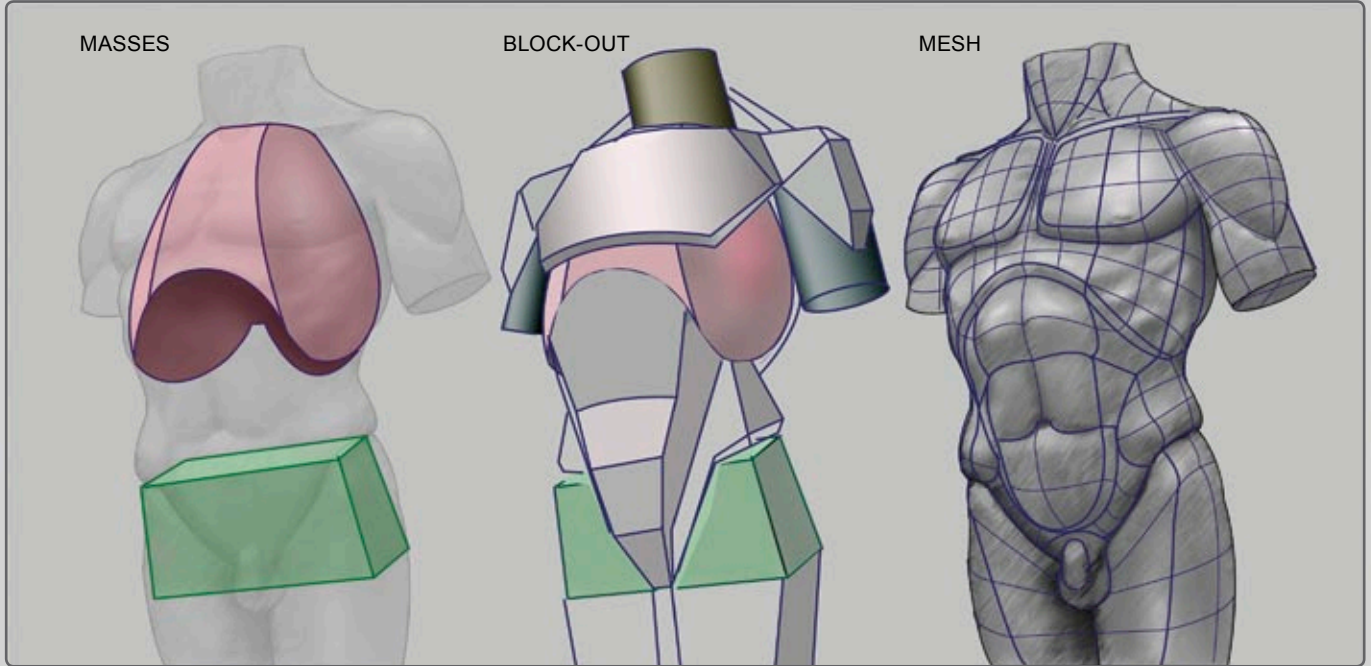
MUSCLES

SHAPES

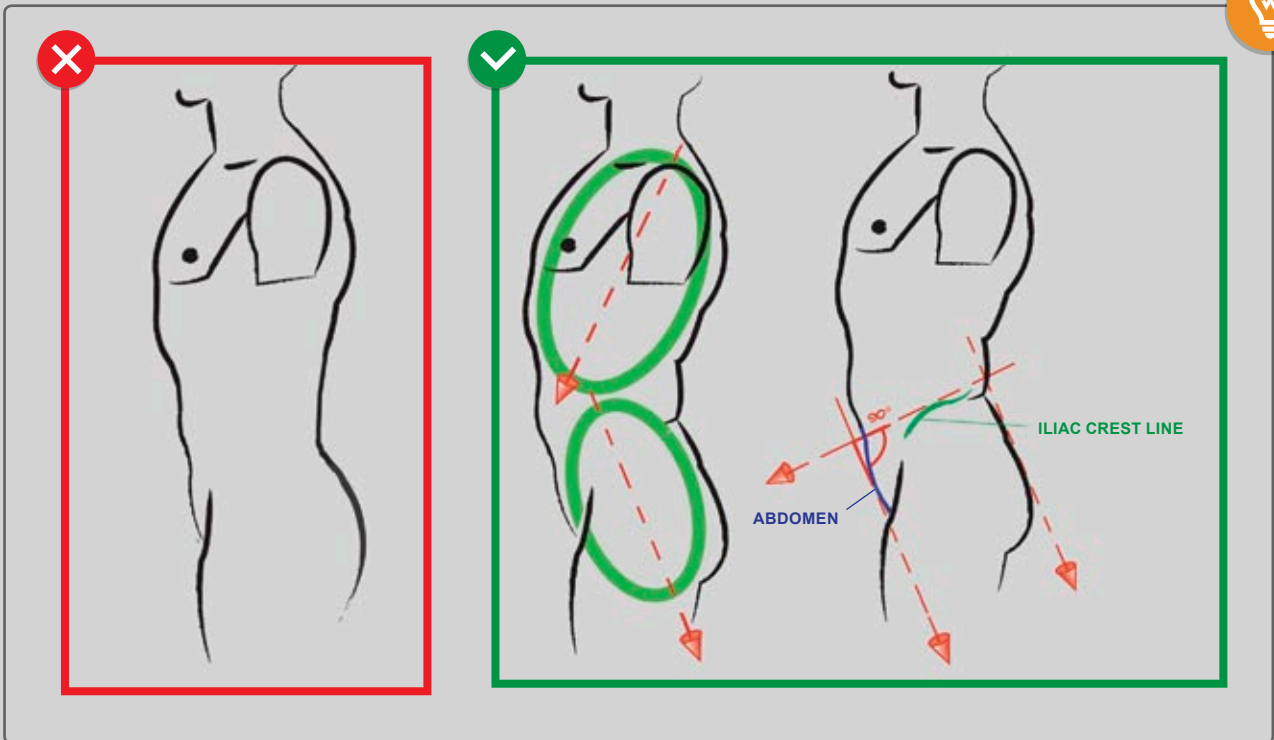
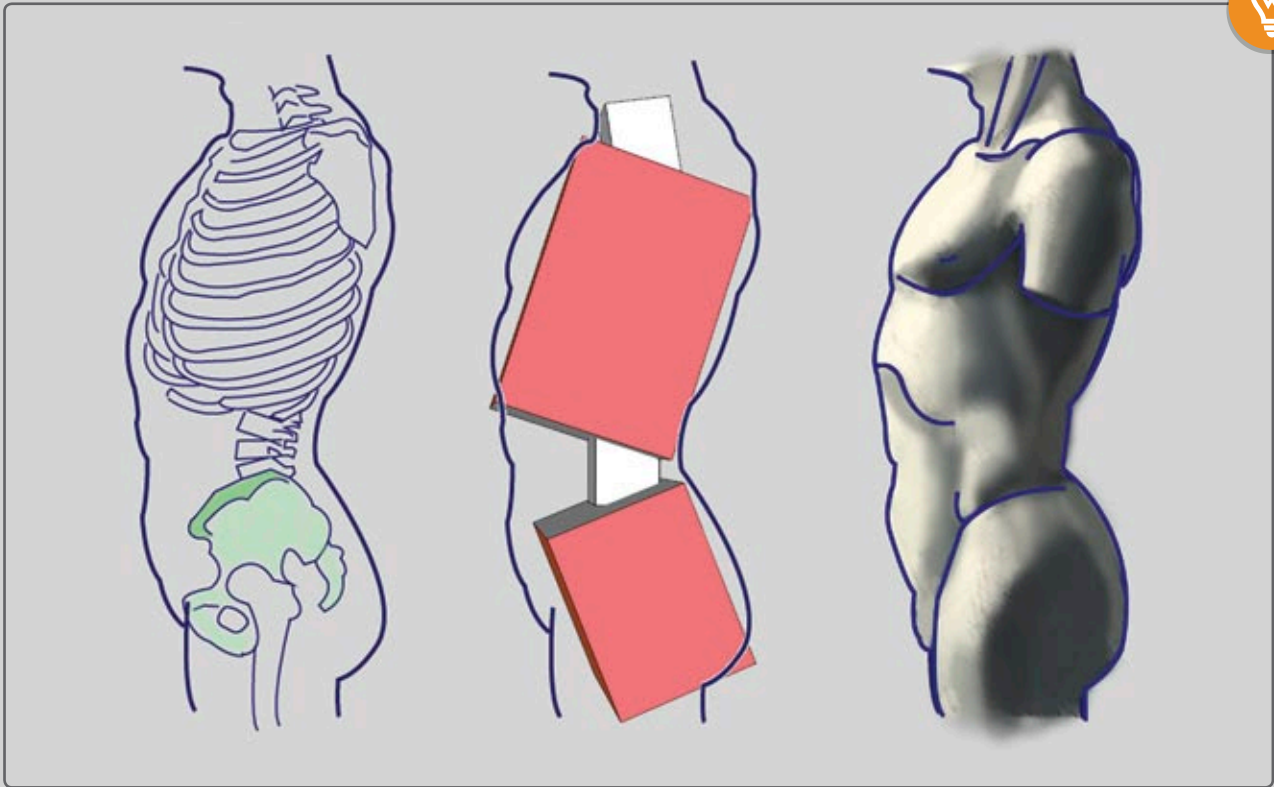
BLOCK-OUT



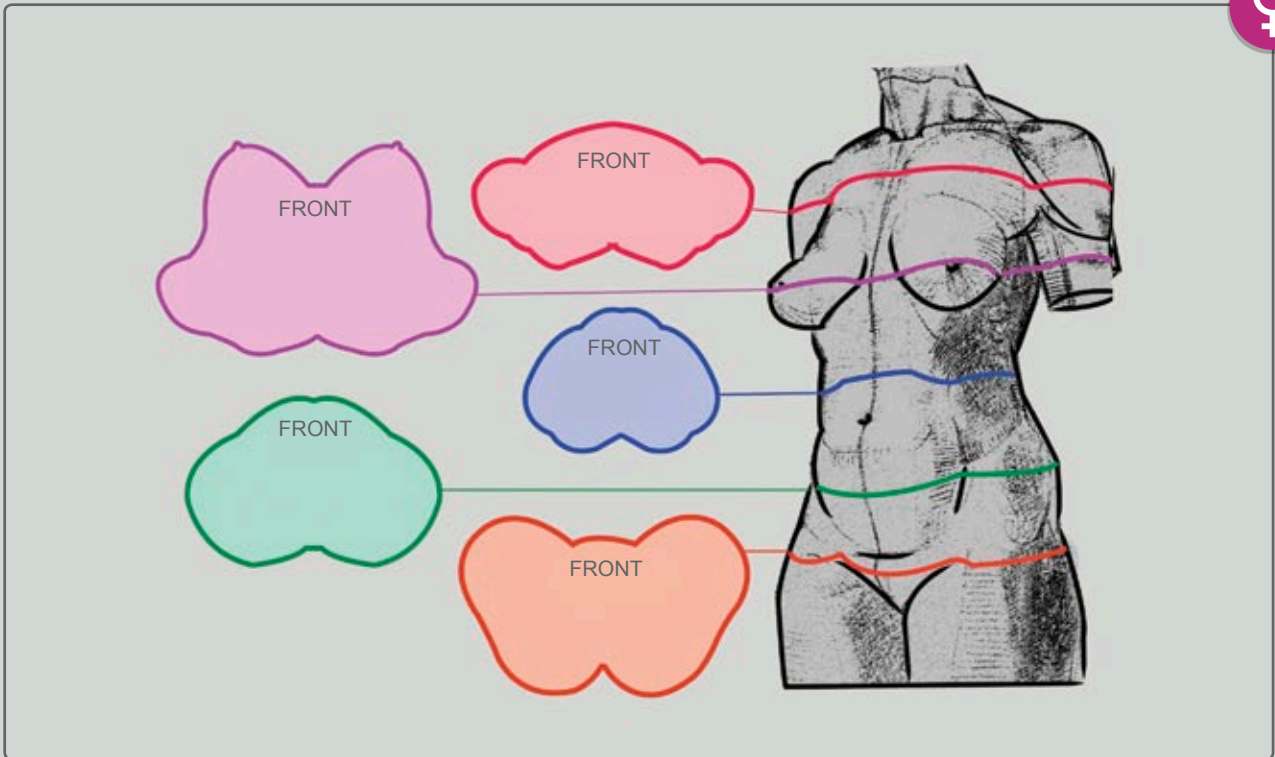
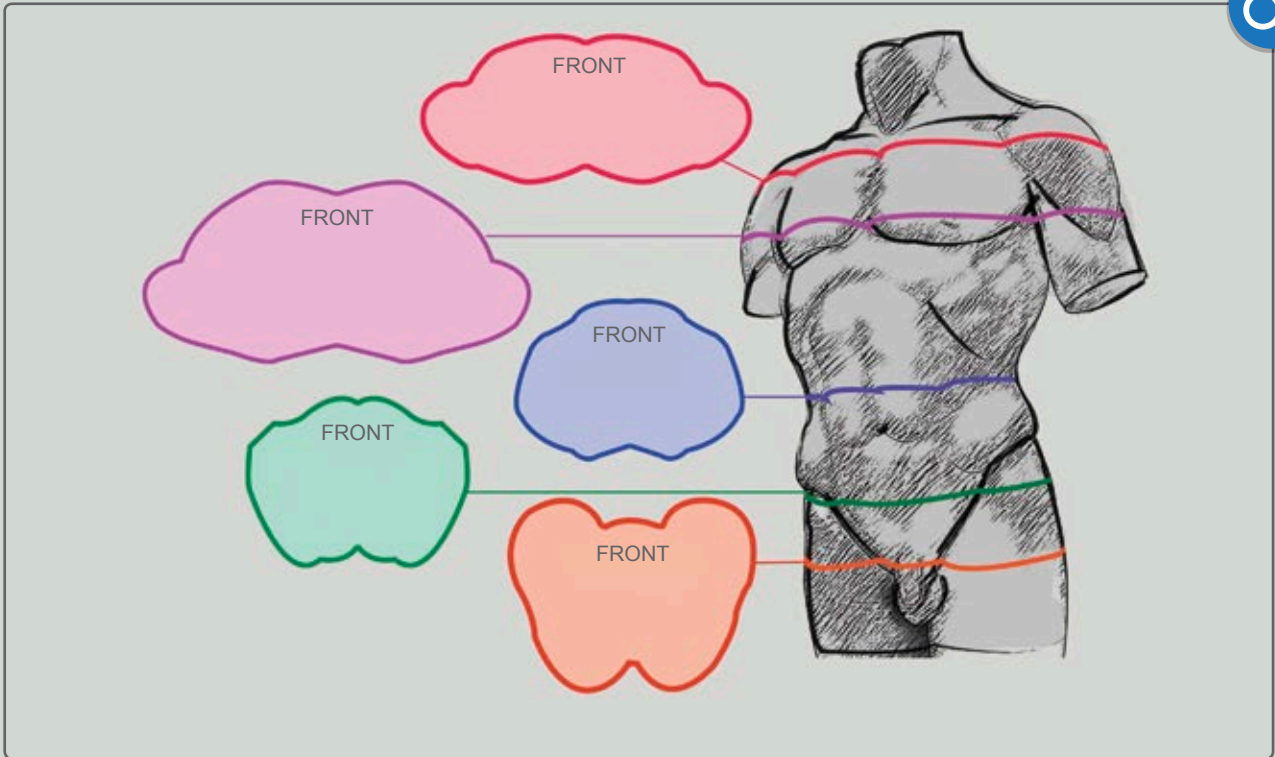
MALE TORSO FROM REALISTIC TO SIMPLIFIED



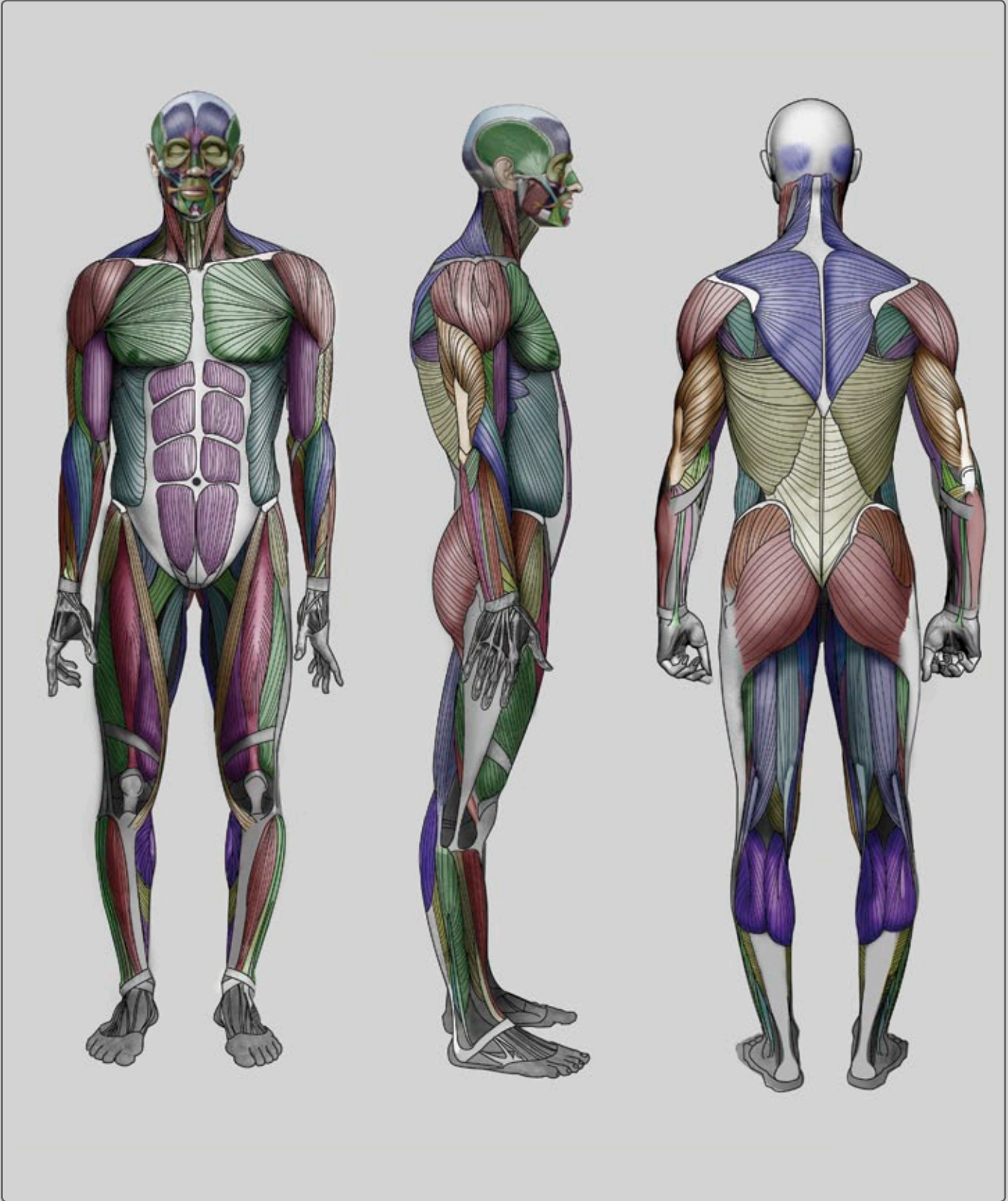
ANGULAR RELATIONSHIP OF MOVABLE MASSES OF TORSO



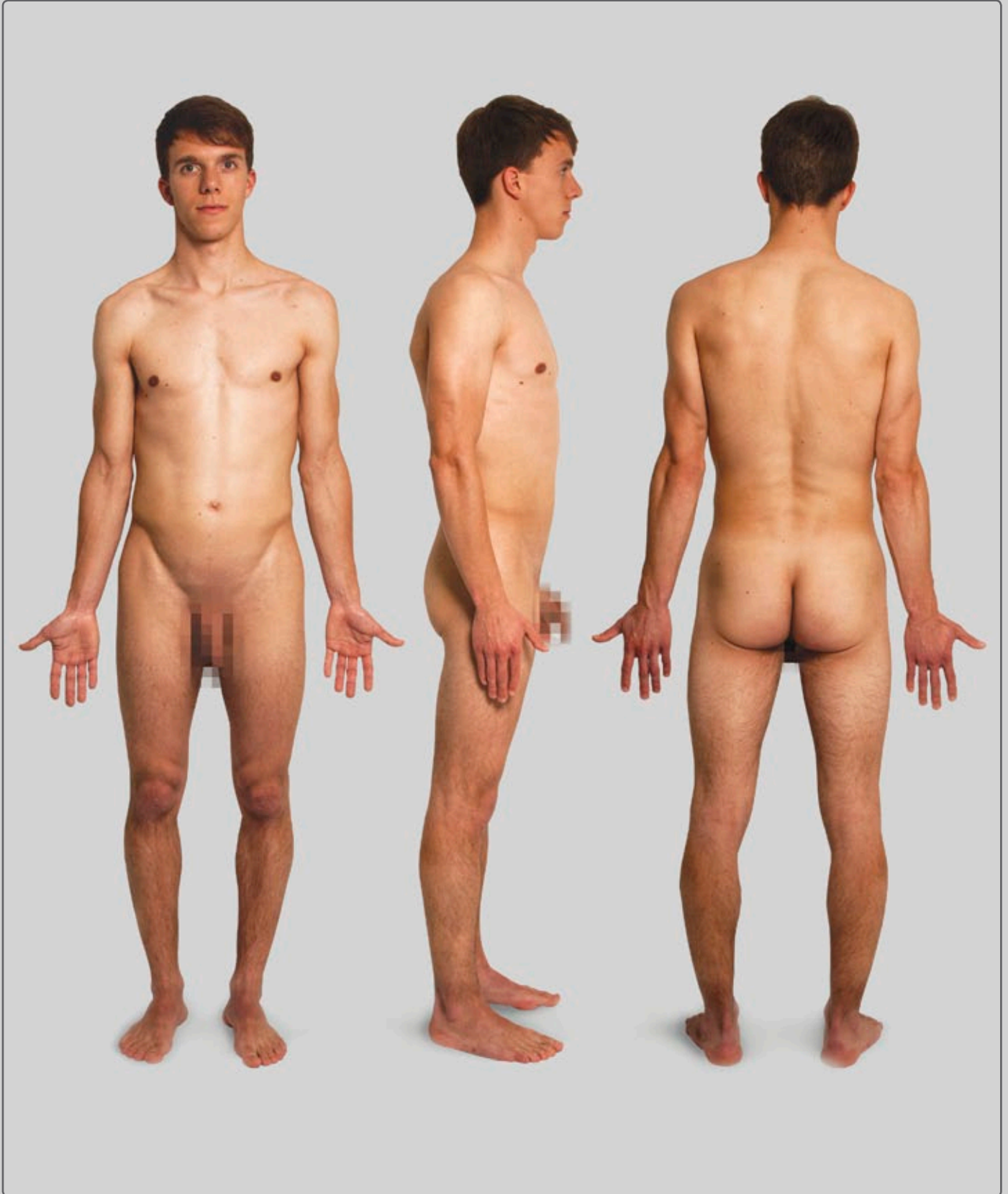HORIZONTAL CROSS SECTIONS OF TORSO



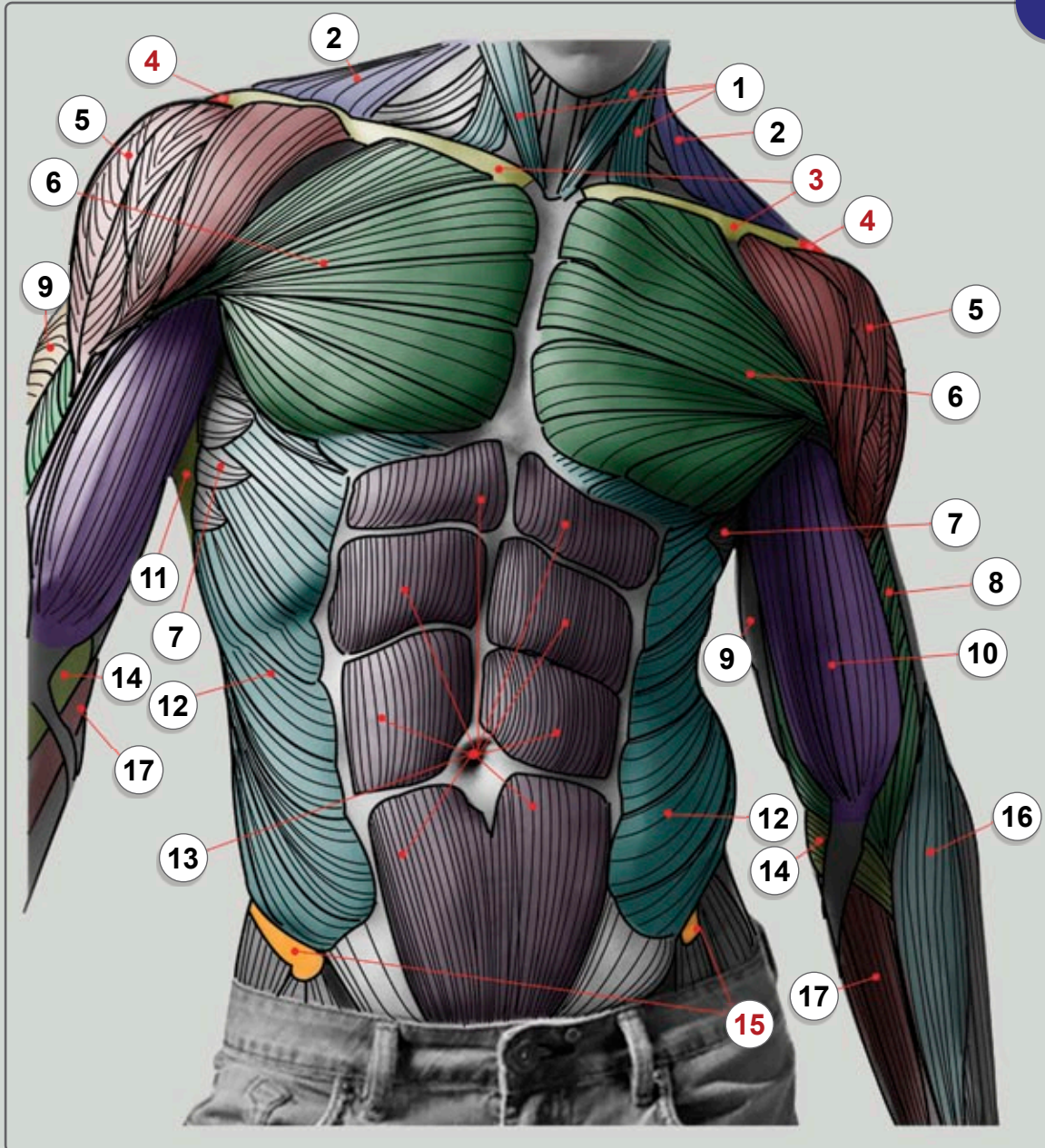
ÉCORCHÉ



MALE FIGURE

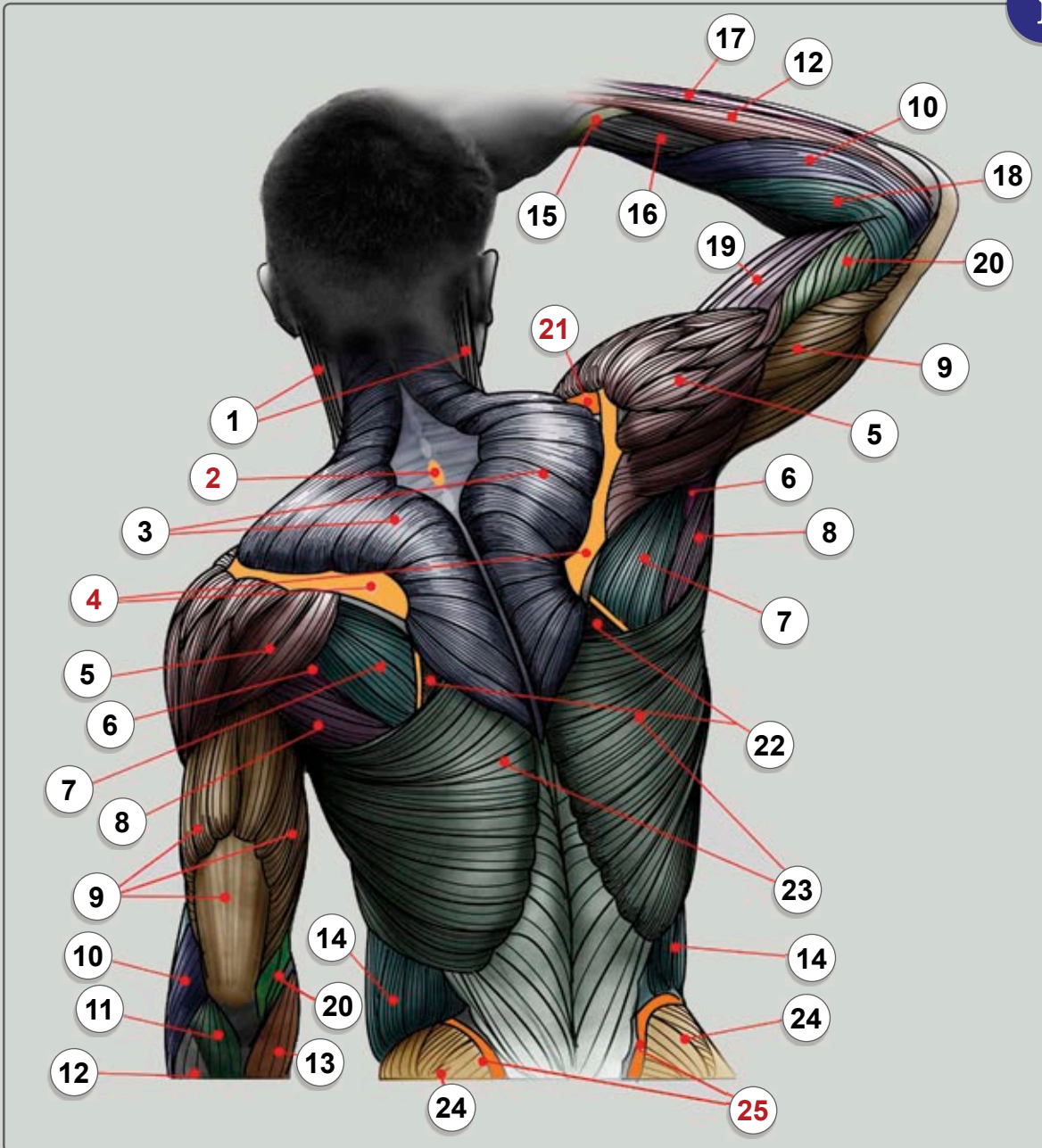


MAIN MUSCLES AND LANDMARK POINTS OF FRONTAL TORSO



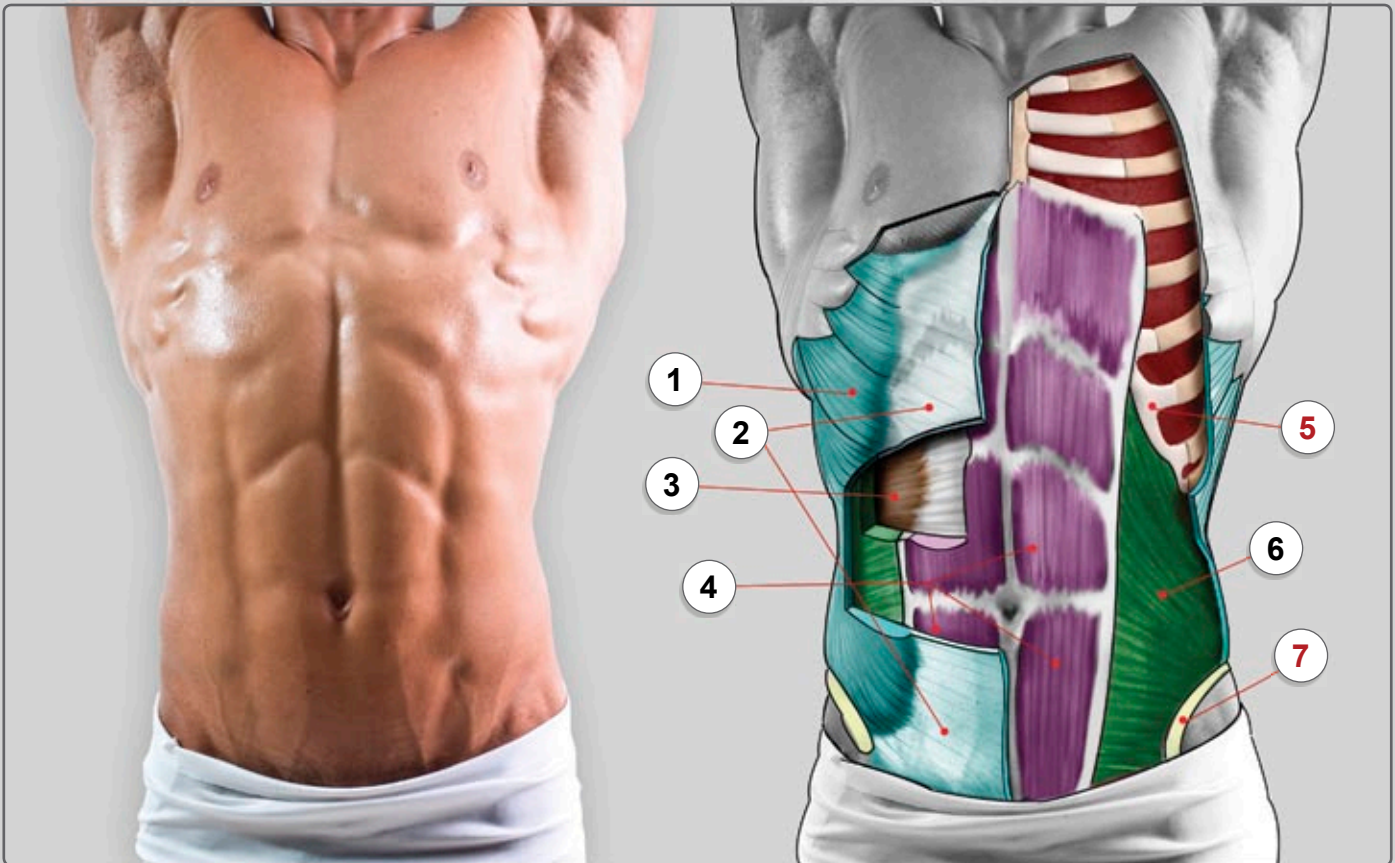
- | | | |
|-----------------------|---------------------|----------------------------------|
| 1 STERNOCLEIDOMASTOID | 7 SERRATUS ANTERIOR | 13 RECTUS ABDOMINIS |
| 2 TRAPEZIUS | 8 BRACHIALIS | 14 PRONATOR TERES |
| 3 CLAVICLE | 9 TRICEPS BRACHII | 15 ANTERIOR SUPERIOR ILIAC SPINE |
| 4 SHOULDER BLADE | 10 BICEPS BRACHII | 16 BRACHIORADIALIS |
| 5 DELTOID | 11 LATISSIMUS DORSI | 17 FLEXOR CARPI RADIALIS |
| 6 PECTORALIS | 12 EXTERNAL OBLIQUE | |

MAIN MUSCLES AND BONES OF THE BACK



- | | | |
|-----------------------|-----------------------------------|-----------------------------------|
| 1 STERNOCLEIDOMASTOID | 10 EXTENSOR CARPI RADIALIS LONGUS | 19 BICEPS BRACHII |
| 2 7TH VERTEBRAE | 11 ANCONEUS | 20 BRACHIALIS |
| 3 TRAPEZIUS | 12 EXTENSOR DIGITORUM | 21 CLAVICLE |
| 4 SPINE OF SCAPULA | 13 FLEXOR CARPI ULNARIS | 22 RHOMBOID MAJOR |
| 5 DELTOID | 14 EXTERNAL OBLIQUE | 23 LATISSIMUS DORSI |
| 6 TERES MINOR | 15 ABDUCTOR POLLICIS LONGUS | 24 GLUTEUS MAXIMUS |
| 7 INFRASPINATUS | 16 EXTENSOR CARPI RADIALIS BREVIS | 25 POSTERIOR SUPERIOR ILIAC SPINE |
| 8 TERES MAJOR | 17 EXTENSOR CARPI ULNARIS | |
| 9 TRICEPS BRACHII | 18 BRACHIORADIALIS | |

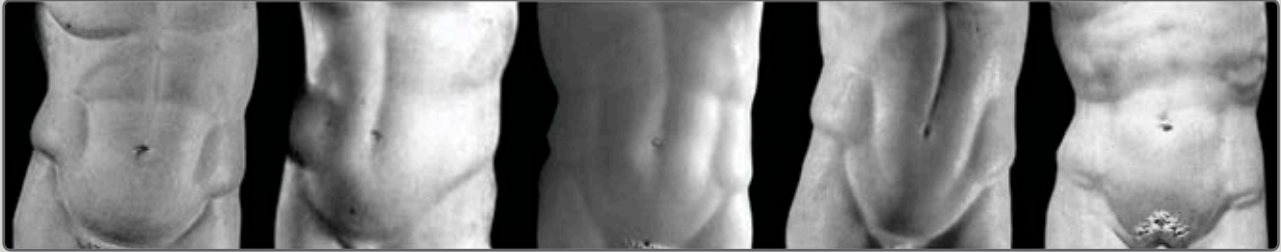ABDOMINAL MUSCLES



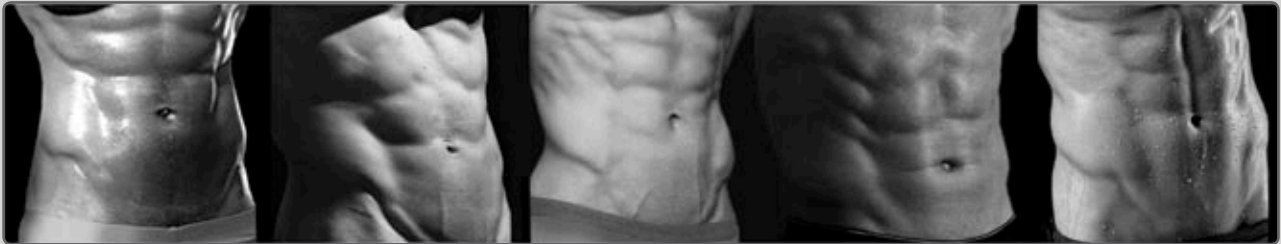
i

- 1 **EXTERNAL OBLIQUE:** LOCATED ON SIDE AND FRONT OF ABDOMEN
- 2 **APONEUROSIS OF EXTERNAL OBLIQUE:** BROAD, FLAT, TENDINOUS PORTION OF **EXTERNAL OBLIQUE** MUSCLE
- 3 **TRANSVERSUS ABDOMINIS:** LOCATED UNDER **OBLIQUES**, IT IS THE DEEPEST OF ABDOMINAL MUSCLES AND WRAPS AROUND SPINE FOR PROTECTION AND STABILITY
- 4 **RECTUS ABDOMINIS:** ALSO KNOWN AS “**ABS**” OR **SIX-PACK** – LOCATED ALONG FRONT OF THE ABDOMEN. THIS IS THE MOST WELL-KNOWN ABDOMINAL MUSCLE
- 5 **RIB CAGE** (THORACIC CAGE OR THORAX)
- 6 **INTERNAL ABDOMINAL OBLIQUE:** LOCATED UNDER **EXTERNAL OBLIQUES** AND RUNS IN THE OPPOSITE DIRECTION
- 7 **WING OF ILIUM** – COMMONLY CALLED “**HIP BONE**” (ILIAC CREST)

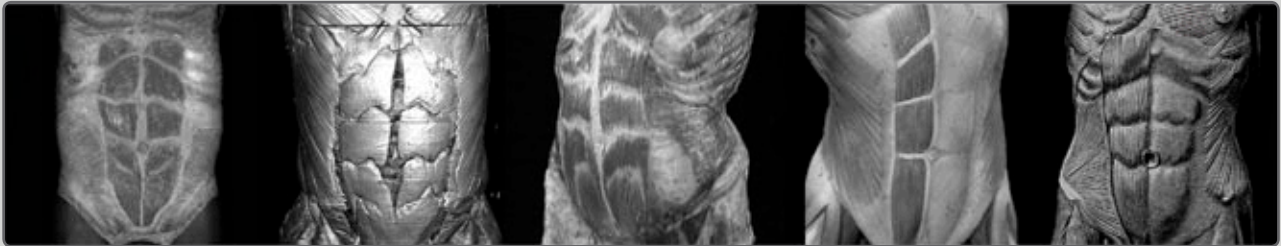IS A “SIX-PACK” REALLY AN “EIGHT-PACK”?



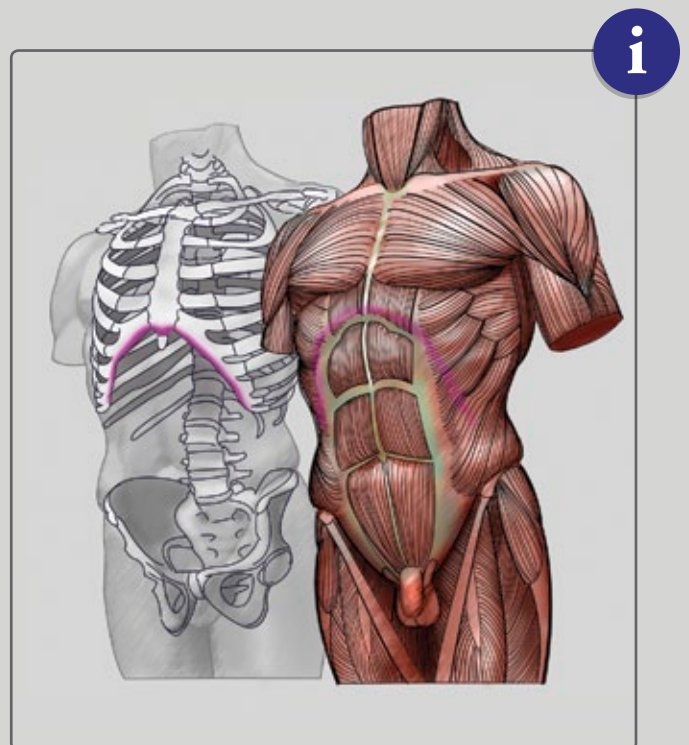
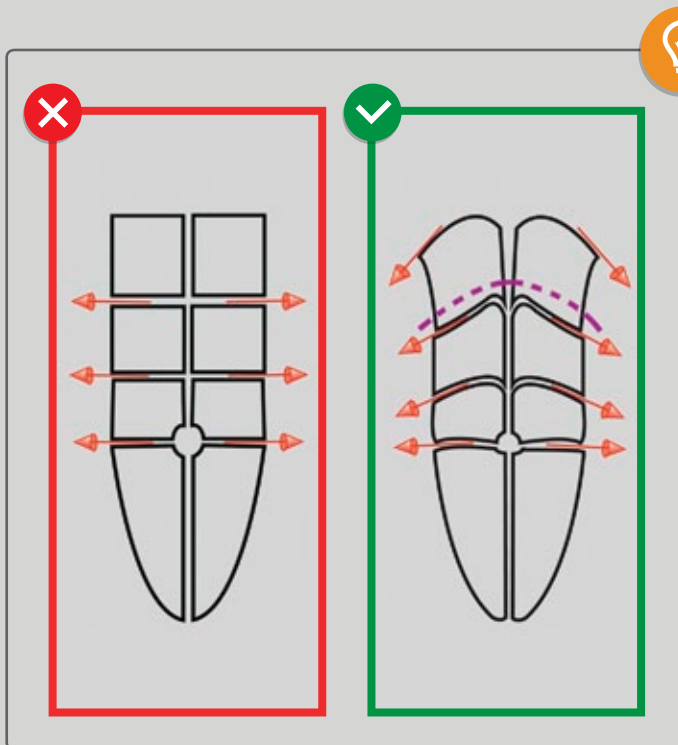
CLASSIC SCULPTURE



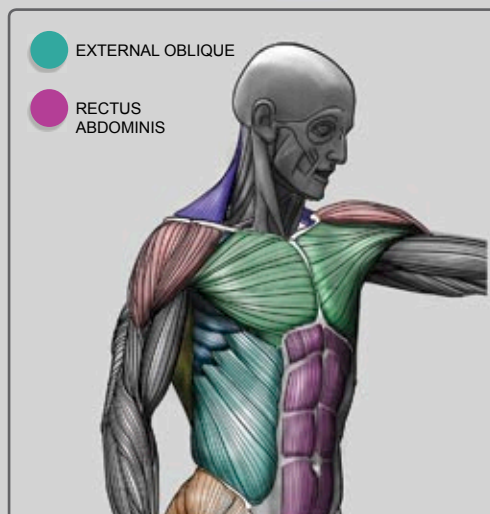
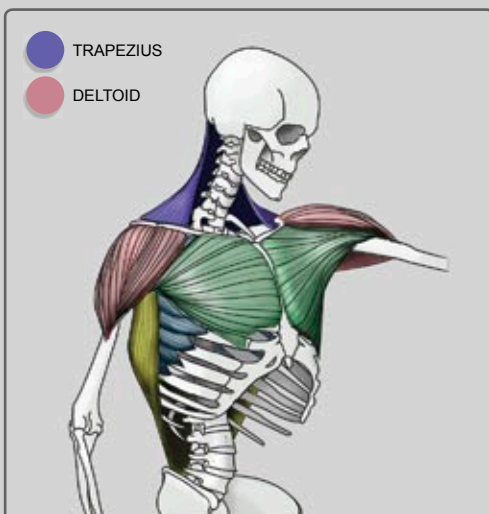
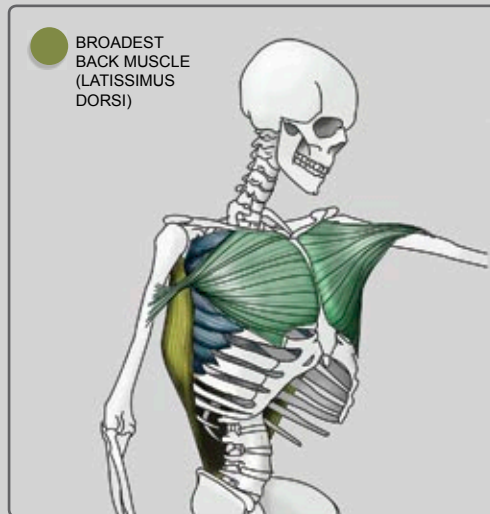
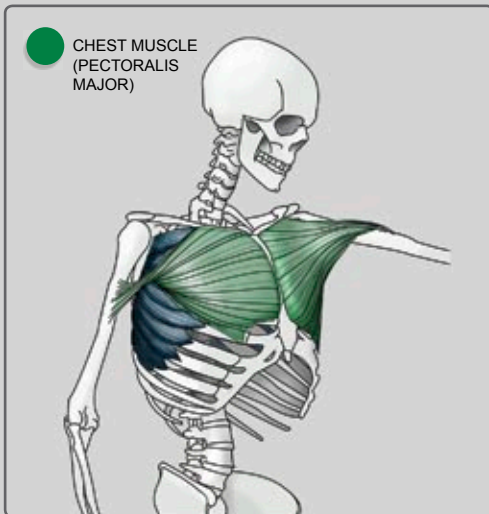
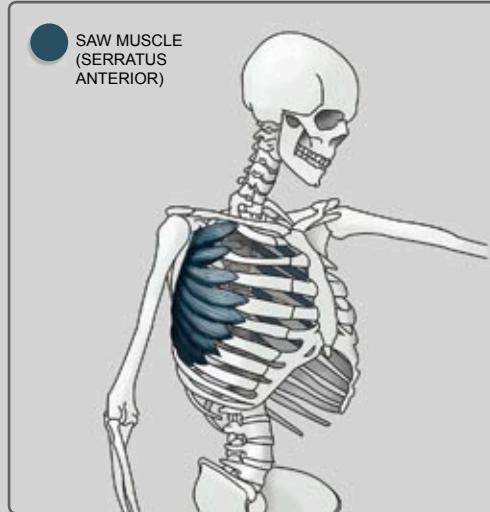
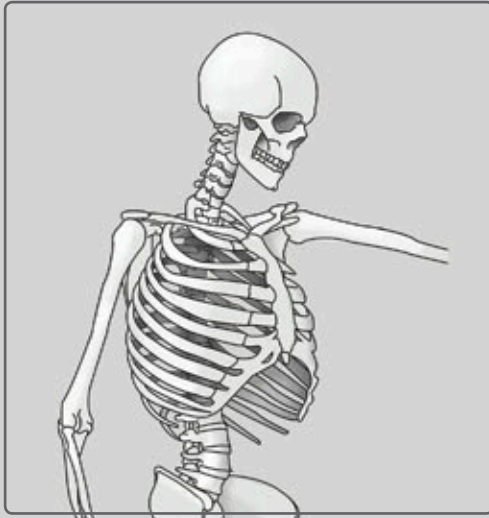
FITNESS



SKINLESS

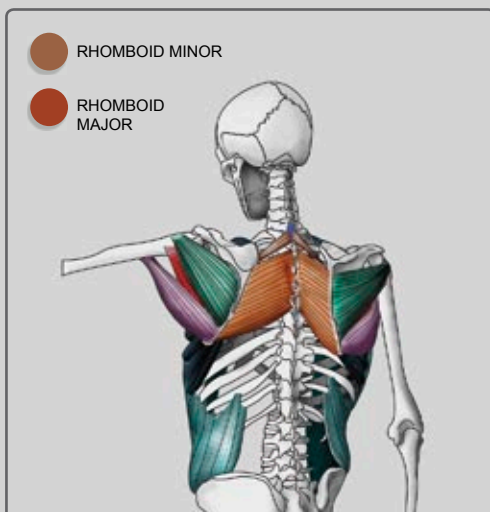
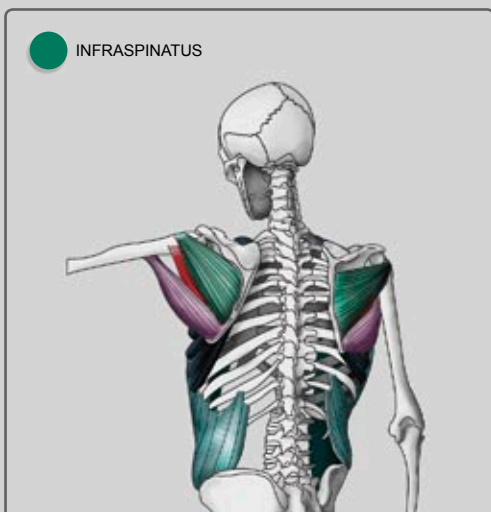
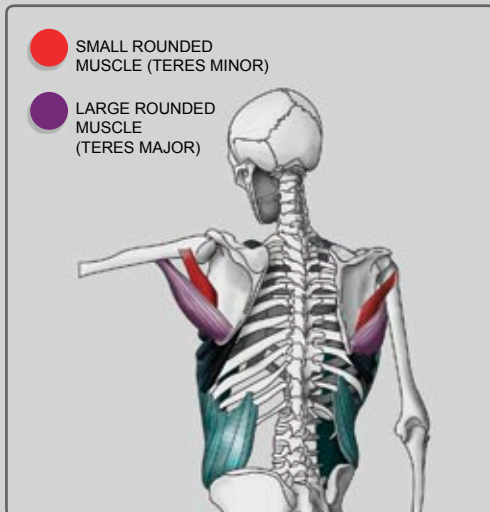
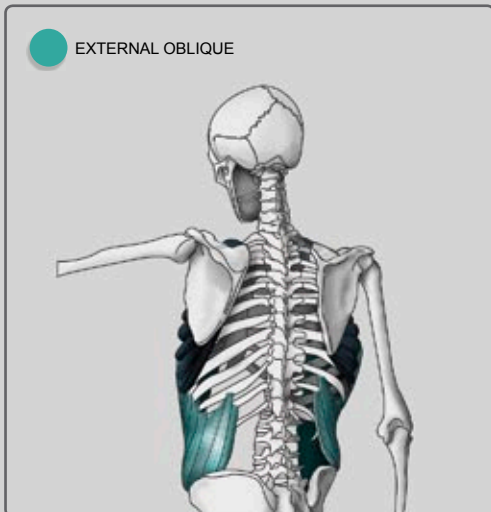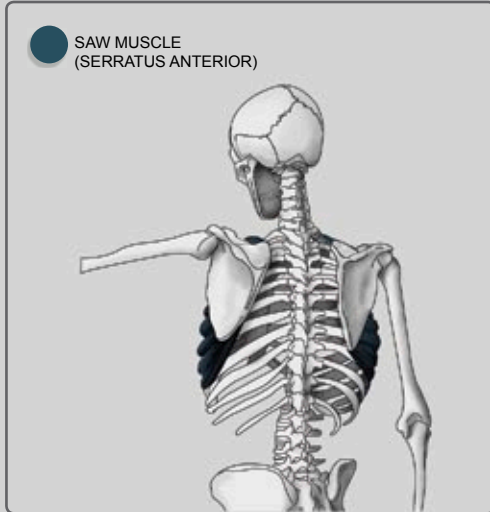
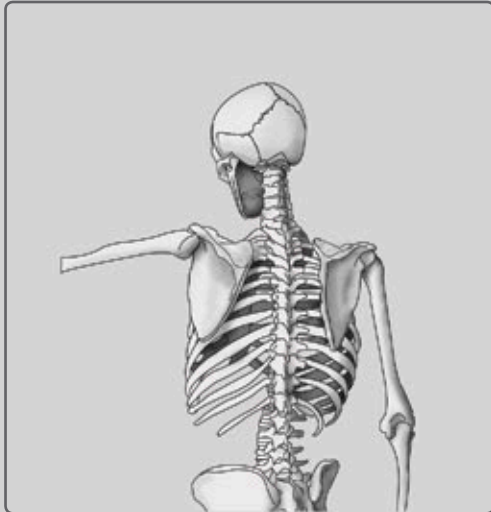


MOST IMPORTANT MUSCLES OF FRONTAL TORSO (LAYER BY LAYER)



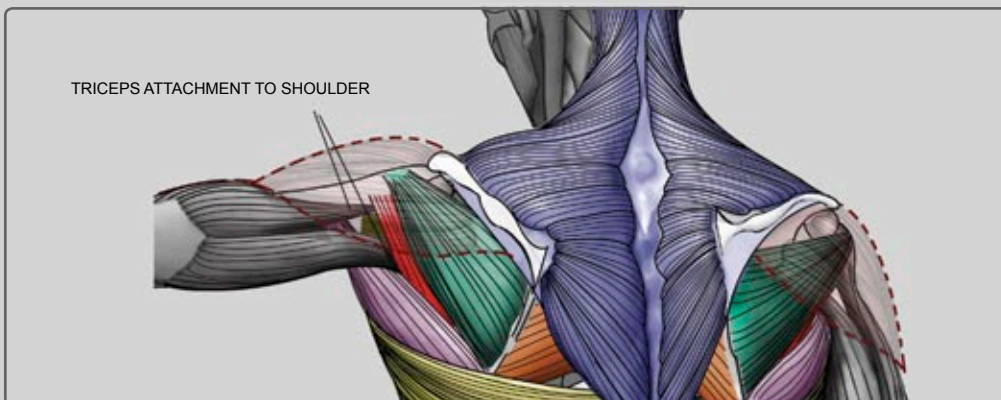
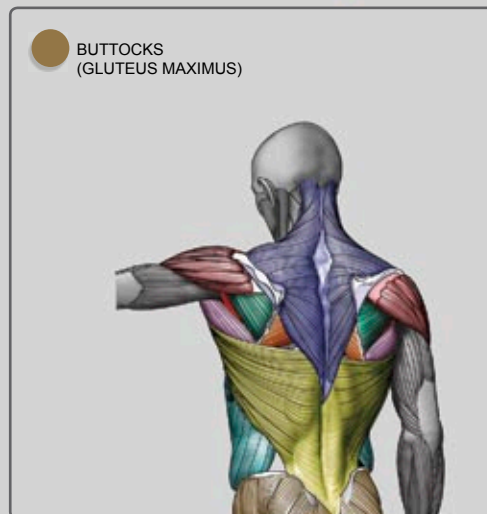
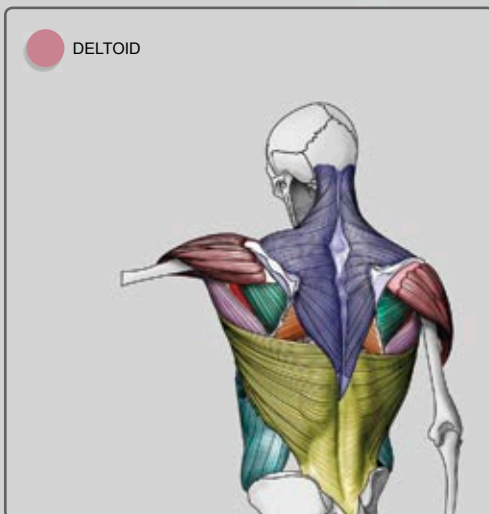
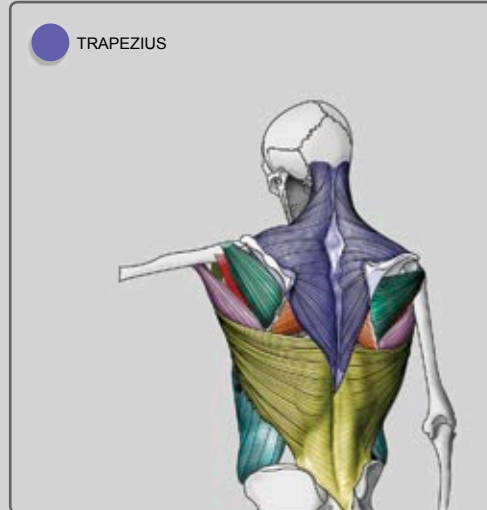
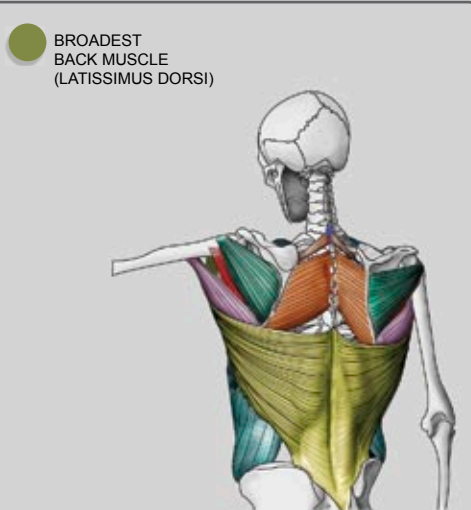
MOST IMPORTANT BACK MUSCLES

(LAYER BY LAYER)

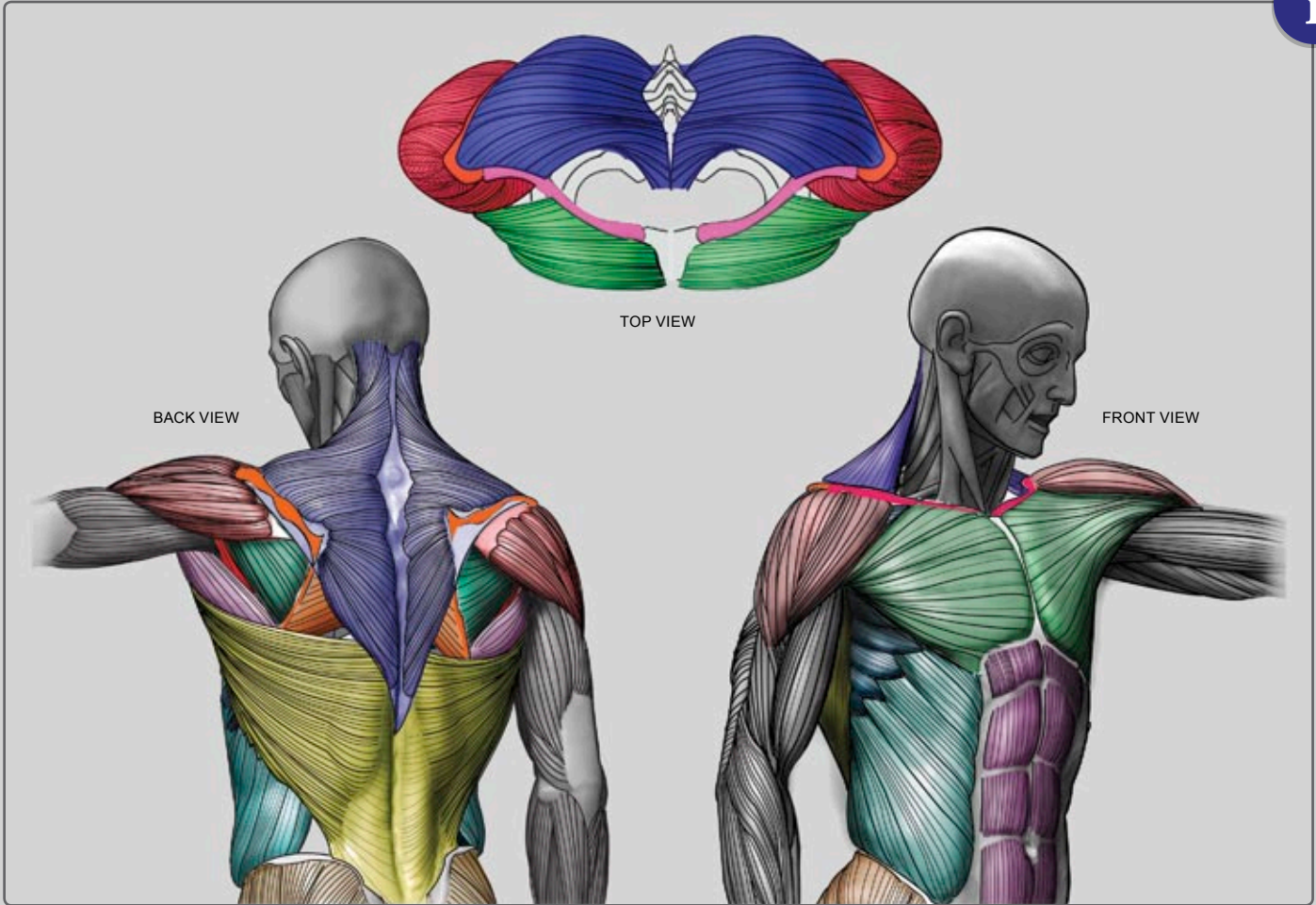


MOST IMPORTANT BACK MUSCLES

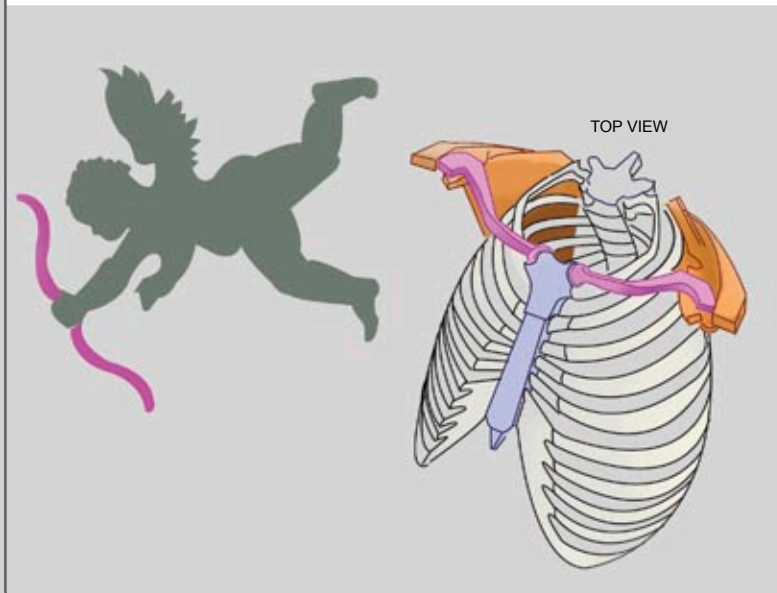
(LAYER BY LAYER)



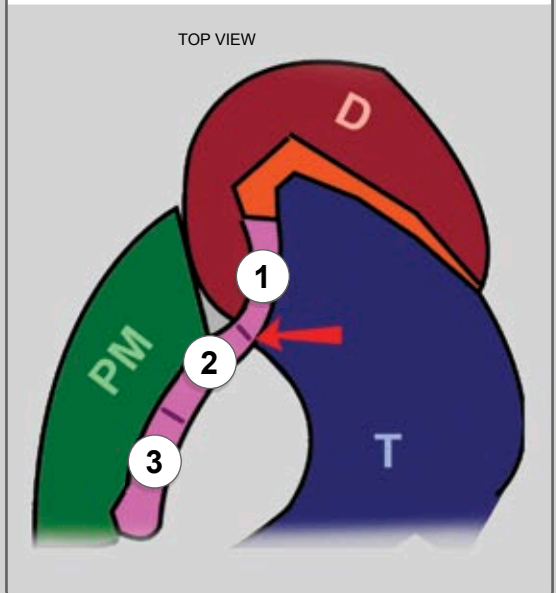
CLAVICLE – SHAPE AND CONNECTIONS



IF YOU LOOK AT THE **CLAVICLE** FROM ABOVE, YOU CAN SEE IT'S AN "S" SHAPE.

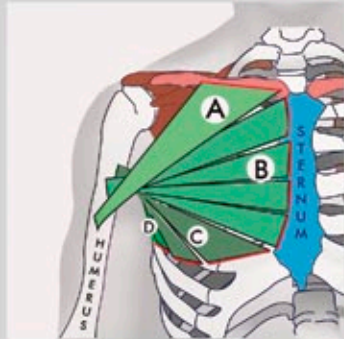


BOTH, **(D)** AND **(T)** CONNECT ON THE LATERAL THIRD OF THE **CLAVICLE**.



GREAT CHEST MUSCLE (PECTORALIS MAJOR)

i



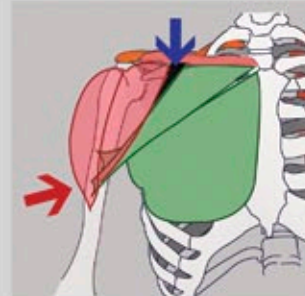
ONE END OF **PM** IS CONNECTED TO THE HUMERUS AND OTHER END CONNECTS:

- A:** TO 3/5 OF **CLAVICLE**
- B:** TO **STERNUM** BONE
- C:** TO **RIBS**
- D:** LYING ON **ABDOMINAL MUSCLES**

A: THIS PORTION IS OFTEN VISIBLE AS SEPARATE PART OF **PM**.

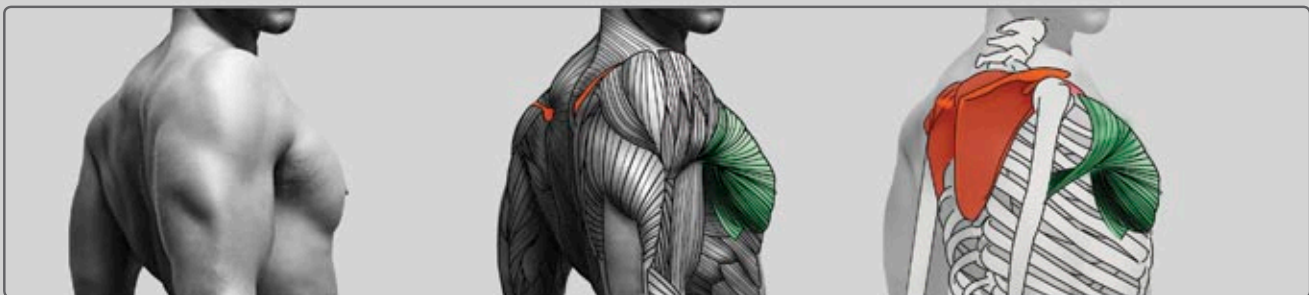
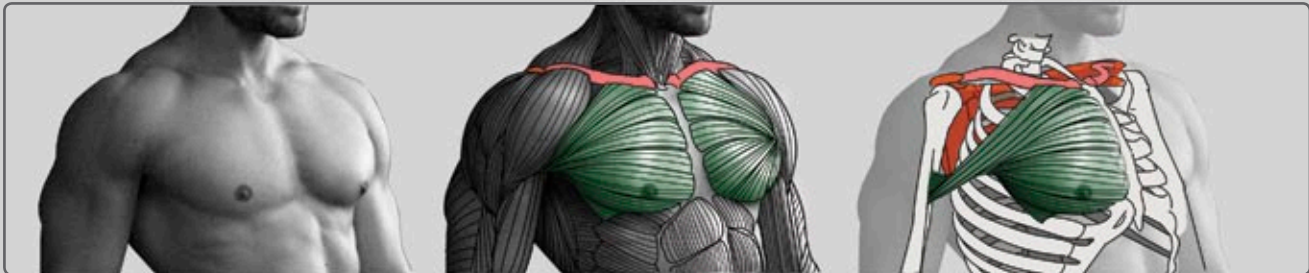
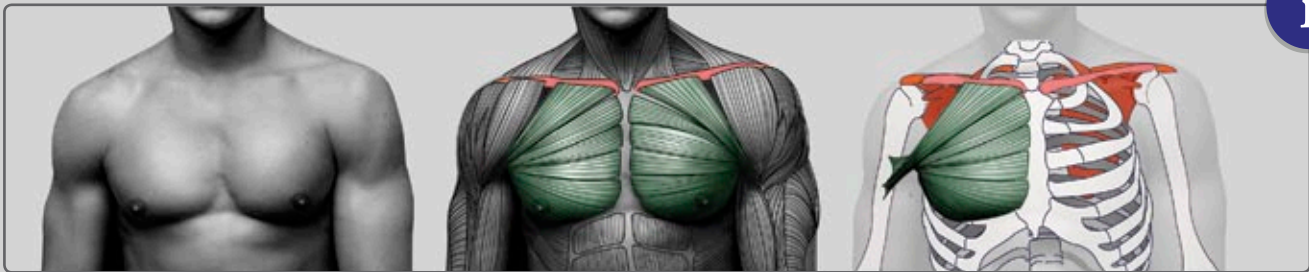
i

HOLLOW AREA BETWEEN PM AND DELTOID IS ALWAYS VISIBLE!

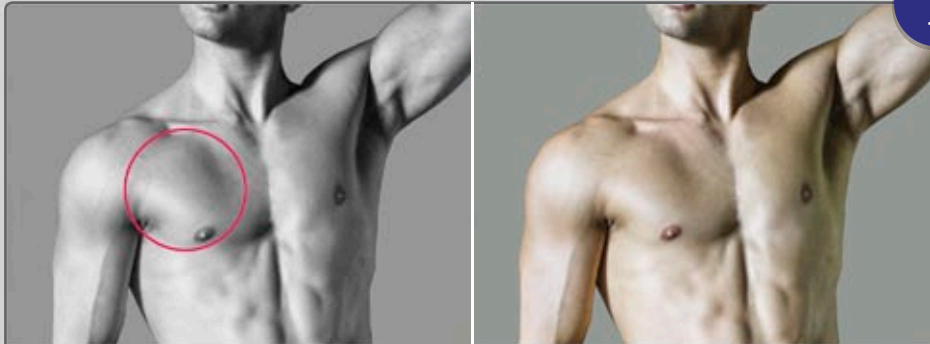


PM IS PARTIALLY COVERED BY DELTOID MUSCLE.

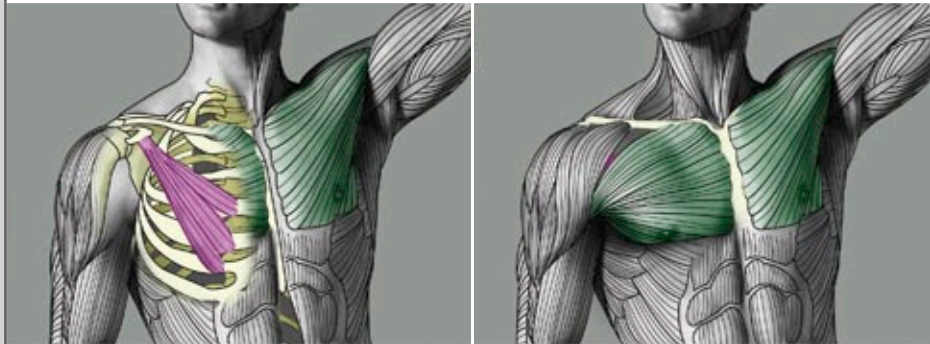
i



WHAT IS THIS BULGE?



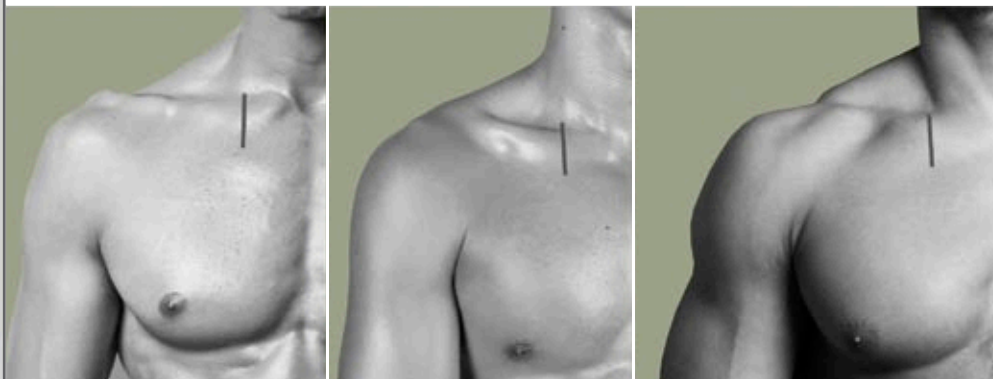
THE **PECTORALIS MINOR** MUSCLE PUSHING **PECTORALIS MAJOR** OUTWARD FROM UNDERNEATH.



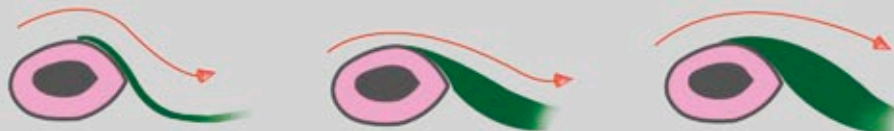ORIGIN: STERNUM ENDS AT 3-5 RIBS
INSERTION: CORACOID PROCESS OF SCAPULA
ACTION: MOVES SHOULDER BLADE FORWARD AND DOWNWARD



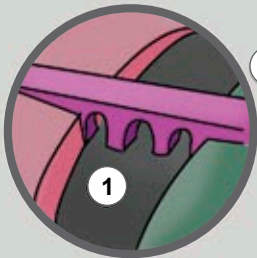
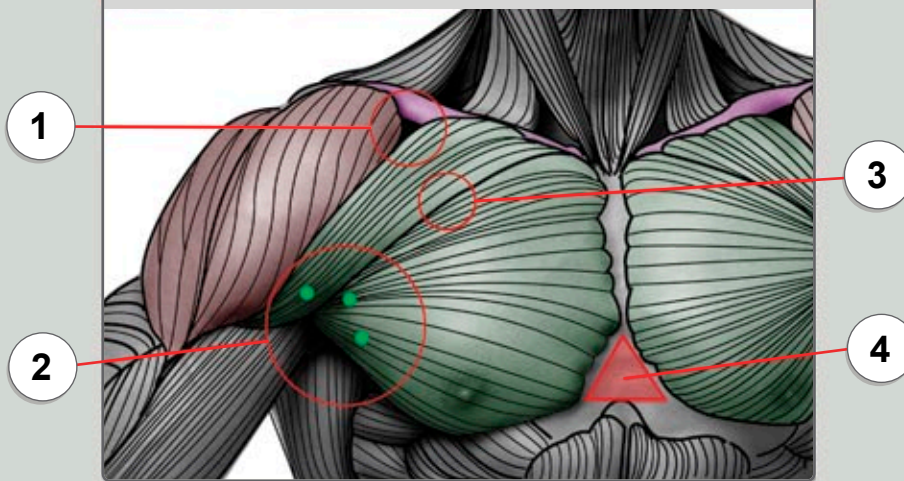
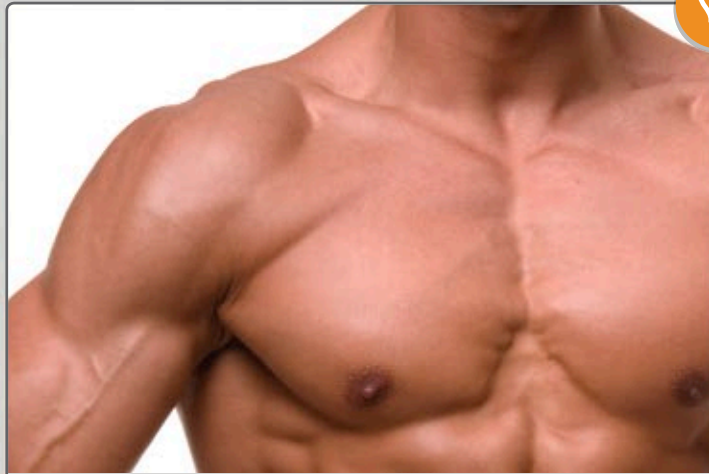AS **CHEST MUSCLES** BECOME MORE DEVELOPED, LESS **COLLAR BONE (CLAVICLE)** IS VISIBLE.



CROSS SECTION OF **COLLAR BONE (CLAVICLE)** AND **CHEST MUSCLE (PECTORALIS MAJOR)**.

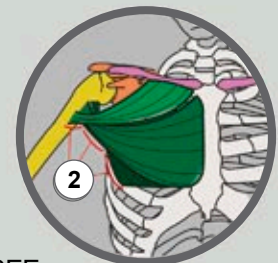


CHEST AND SHOULDER FEATURES



1 **COLLARBONE (CLAVICLE)** IS LIKE A BRIDGE OVER A VALLEY. UNDERNEATH THE COLLARBONE IS THE **INFRACLAVICULAR TRIANGLE (INFRACLAVICULAR FOSSA)**, WHICH IS A PIT BETWEEN **THE CHEST MUSCLE (PECTORALIS MAJOR)** AND **SHOULDER MUSCLE (DELTOID)**. THE **COLLARBONE (CLAVICLE)** IS ALWAYS VISIBLE.

2 EACH BODY ●●● OF **THE CHEST MUSCLE (PECTORALIS MAJOR)** HAS DIFFERENT INSERTIONS ON **THE HUMERUS**. FIBERS CHANGE DIRECTIONS, CROSSING OVER EACH OTHER AND CREATING **MULTIPLE MASSES ON THE EDGE OF THE ARMPIT**.



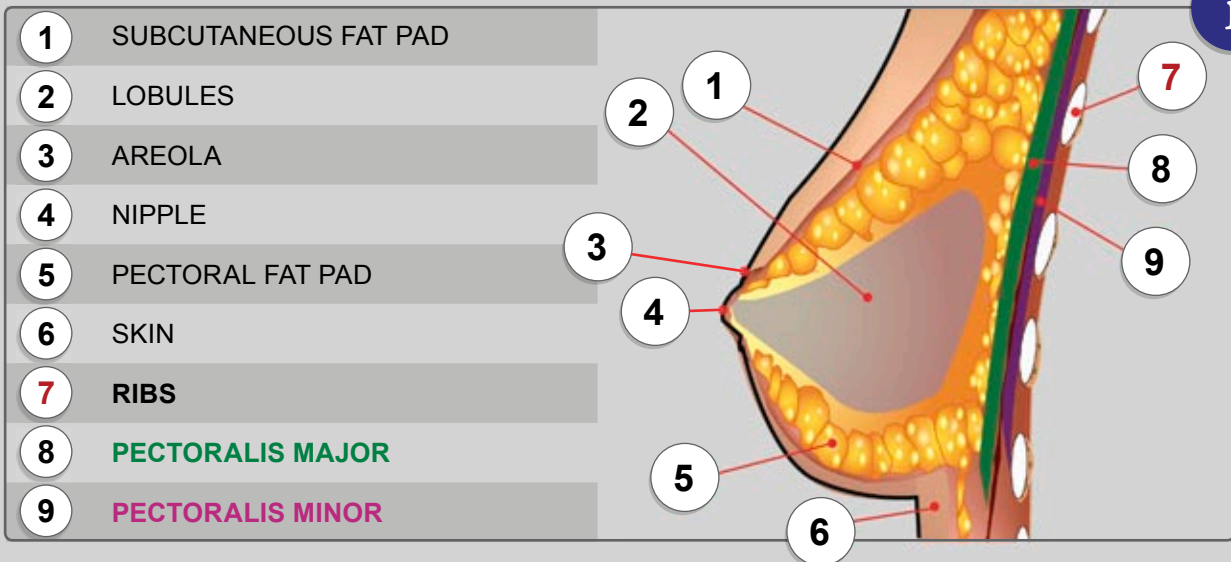
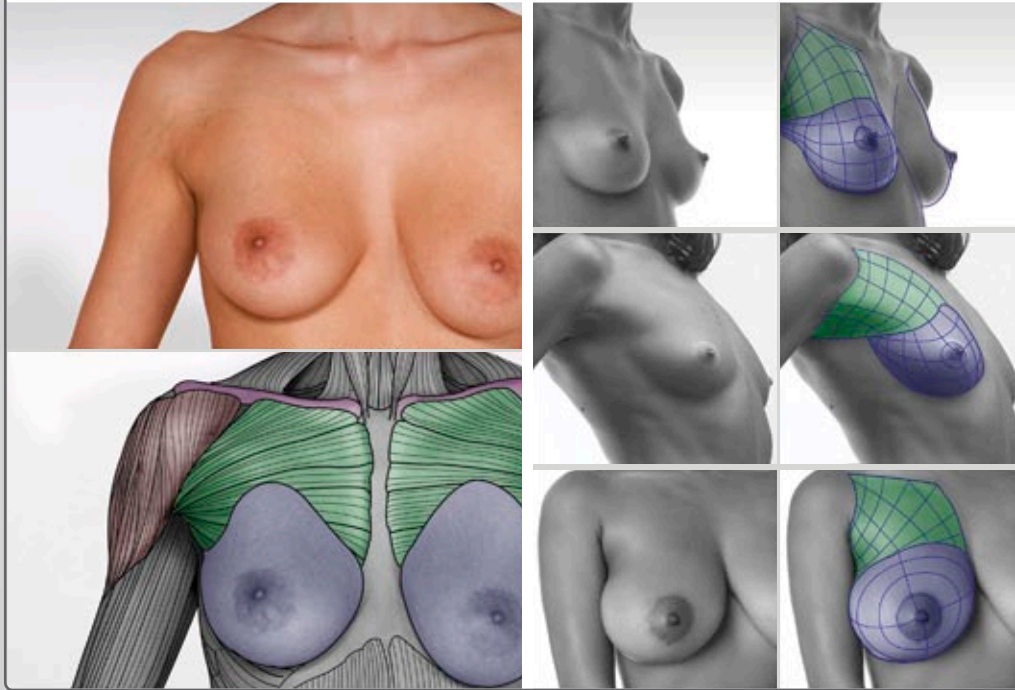
3 SOMETIMES IN VERY MUSCULAR INDIVIDUALS, YOU CAN SEE A SEPARATION BETWEEN THE **CLAVICULAR SECTION** AND **STERNAL SECTION** OF THE **CHEST MUSCLE (PECTORALIS MAJOR)**.

4 **BONY TRIANGLE** BETWEEN **CHEST MUSCLES** AND **ABDOMINAL SIX-PACK**.

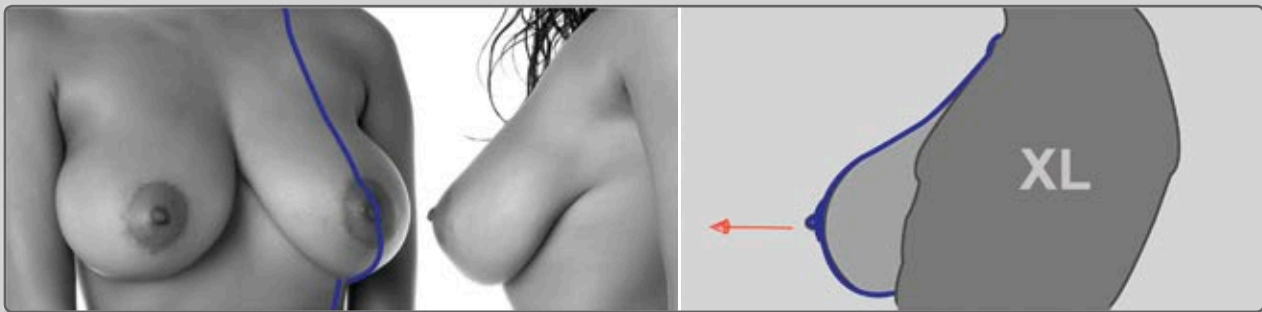
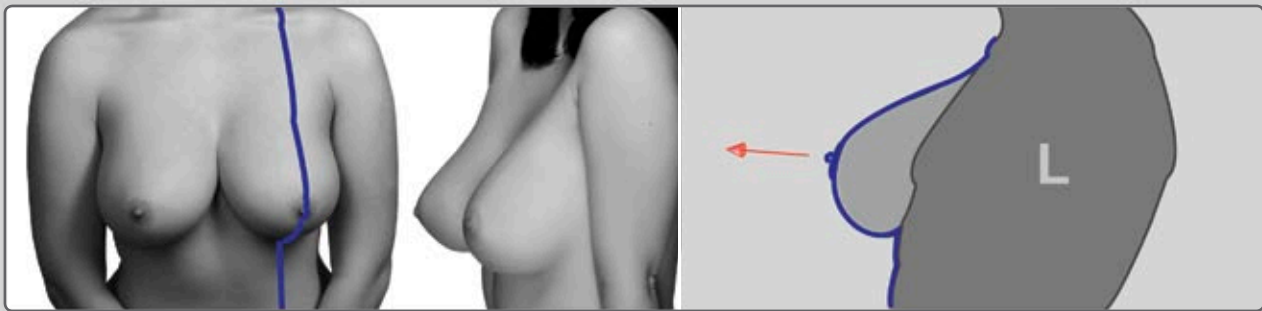
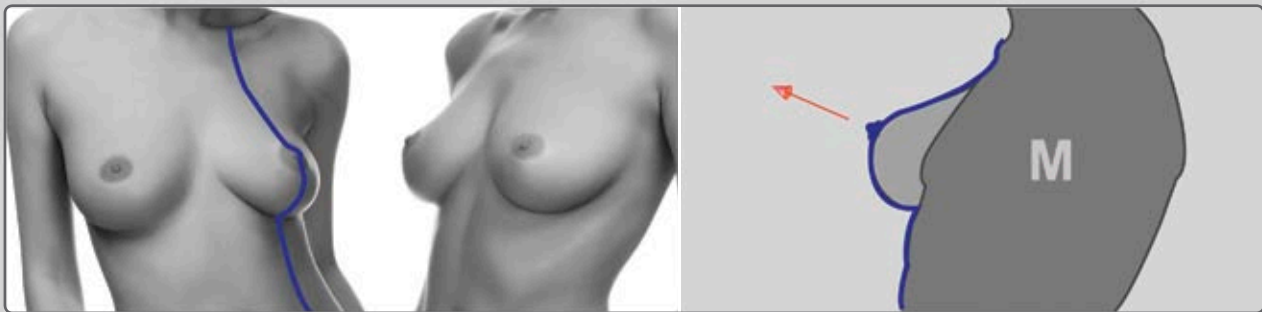
FEMALE BREAST



IMAGINING THE SEPARATION BETWEEN **BREASTS** AND **PECTORAL MUSCLES** MAY HELP YOU SCULPT THEM CORRECTLY.




FEMALE BREAST ANGLES VARY DEPENDING ON SHAPE AND SIZE



BREAST VOLUME AND POSITIONING

ALTHOUGH THE SHAPE CHANGES, VOLUME REMAINS CONSTANT.



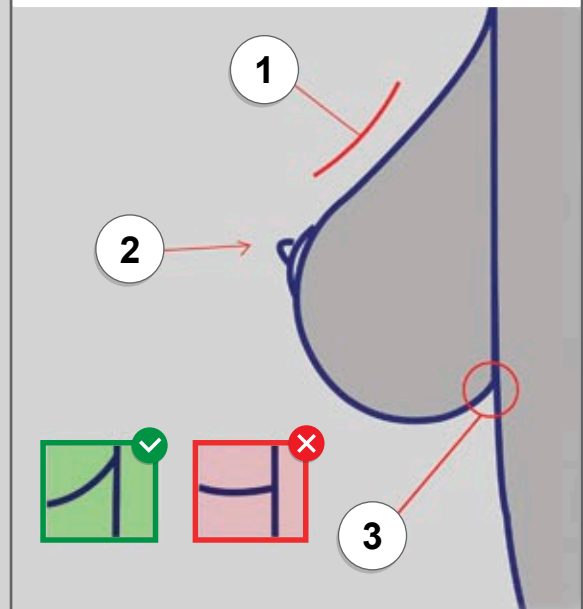
i



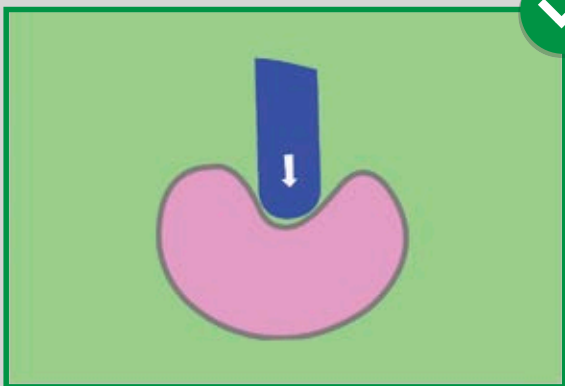
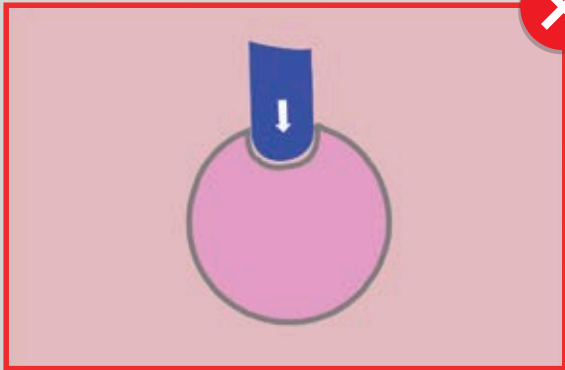
THE LARGER THE BREASTS, THE MORE THEY ARE SHAPED BY GRAVITY WHEN A WOMAN IS LYING ON HER BACK.




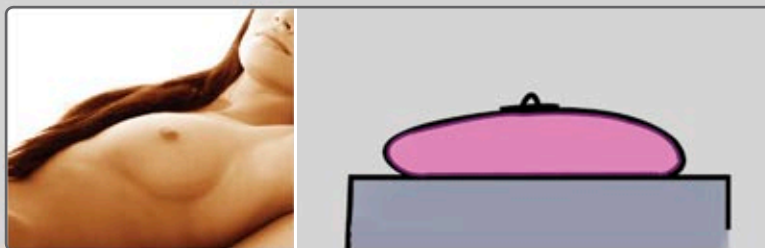

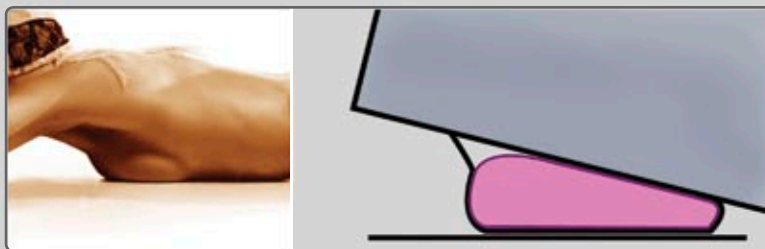


3 TIPS ON HOW TO MAKE FEMALE BREASTS LOOK YOUTHFUL.



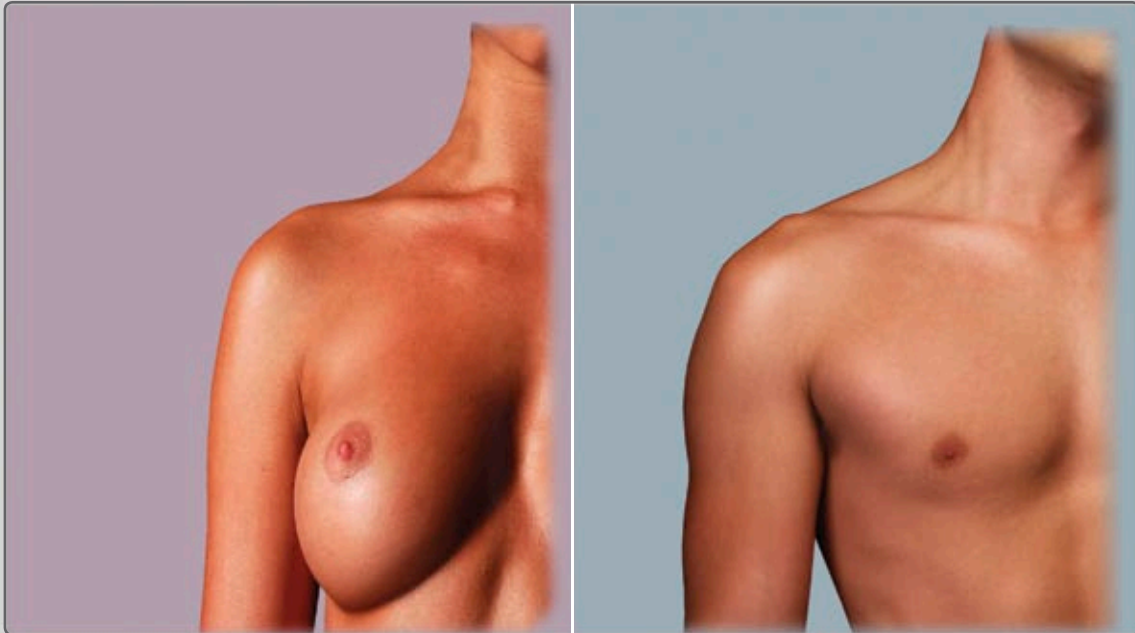
- 1 TOP SIDE: STRAIGHT OR CONCAVE, BUT NEVER CONVEX
- 2 NIPPLE POINTS UPWARD
- 3 LIFT LOWER BORDER WHERE BREAST CONNECTS TO CHEST WALL



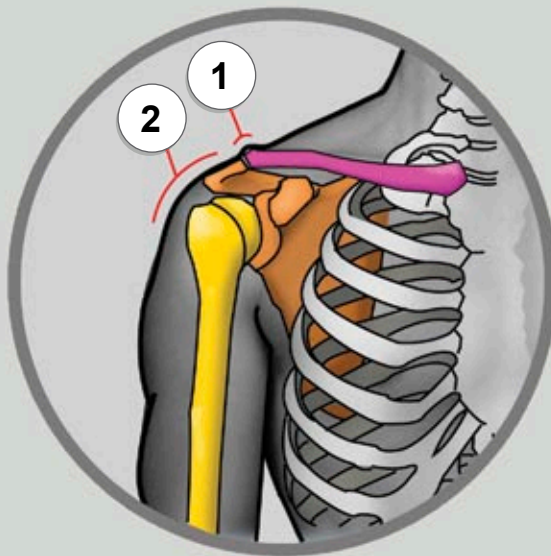
WEIGHT AND MASS DISTRIBUTION OF FEMALE BREAST



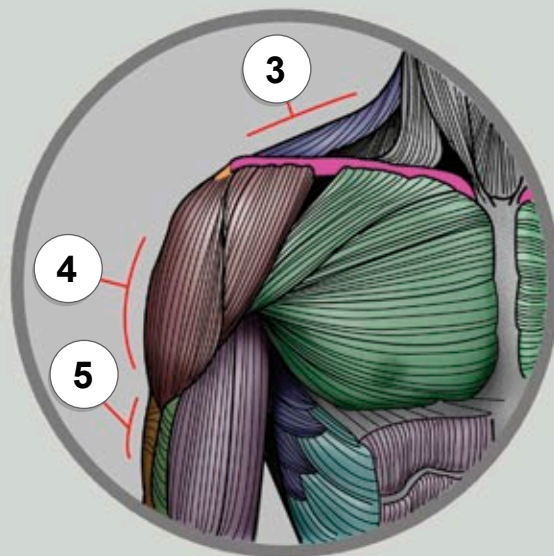
WHAT CREATES A SHOULDER'S SILHOUETTE?



BONES

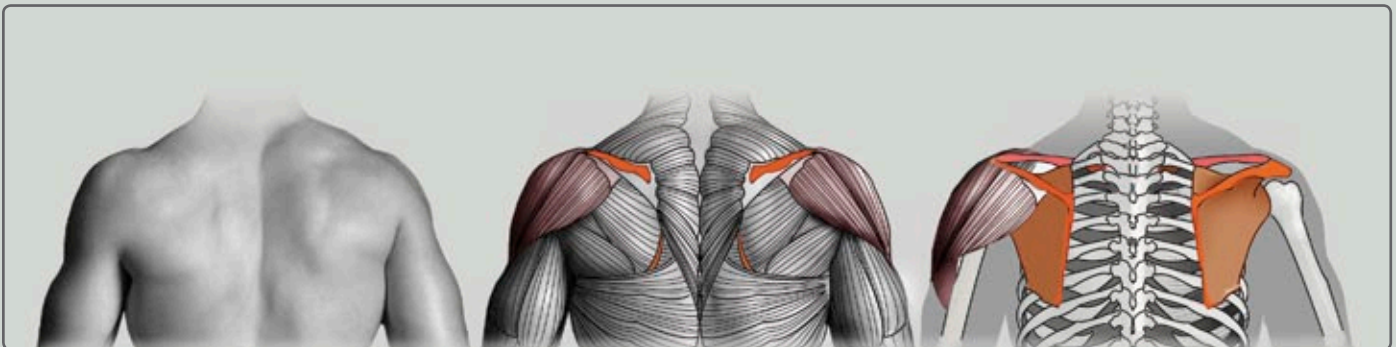
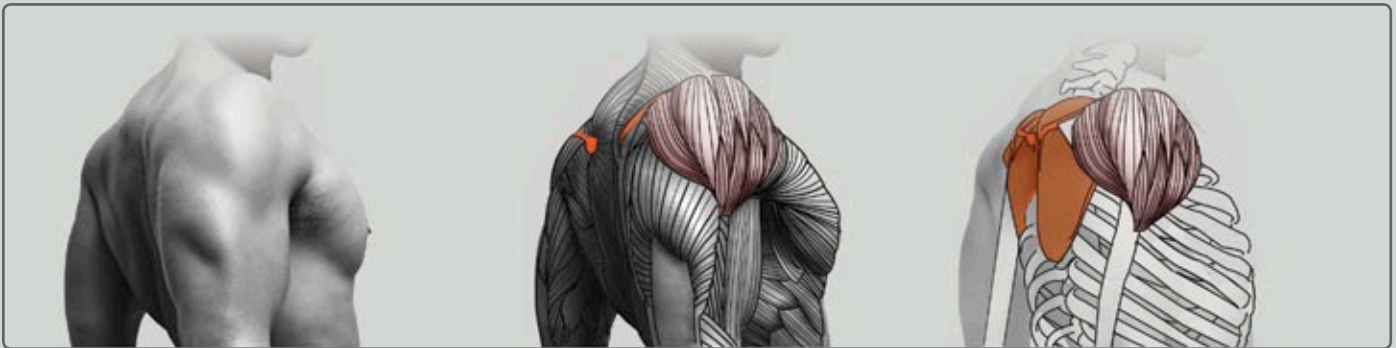
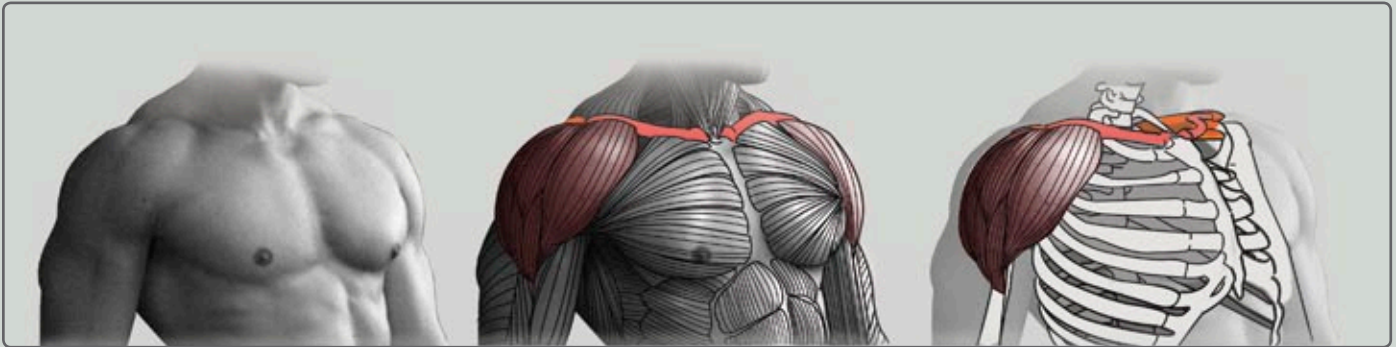
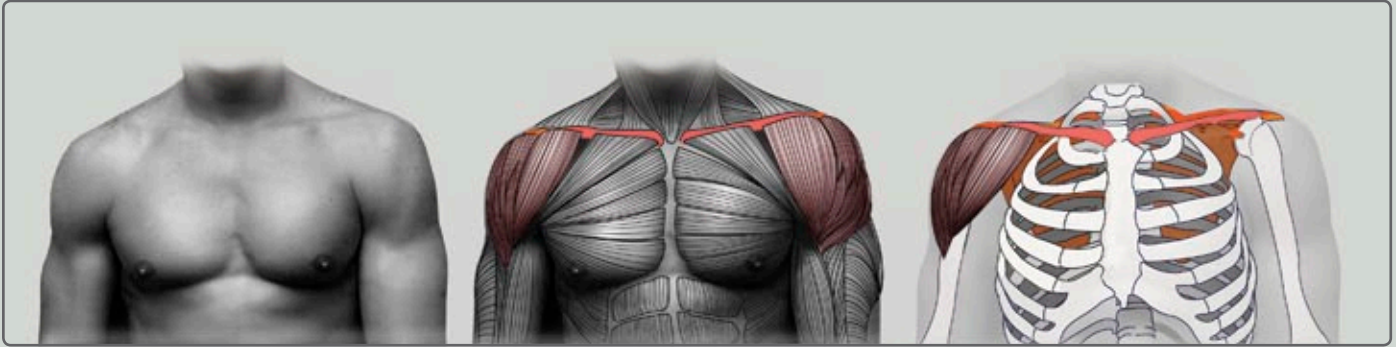


MUSCLES

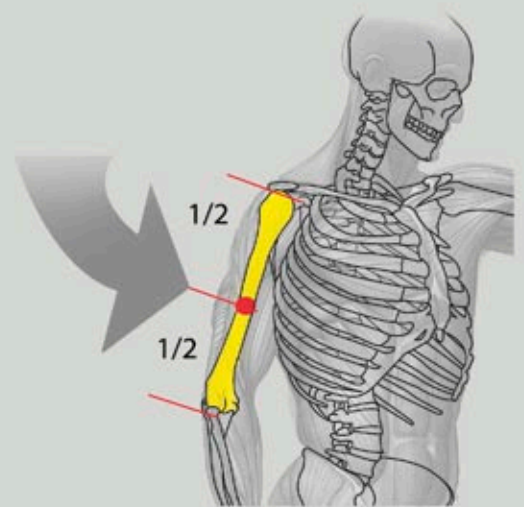
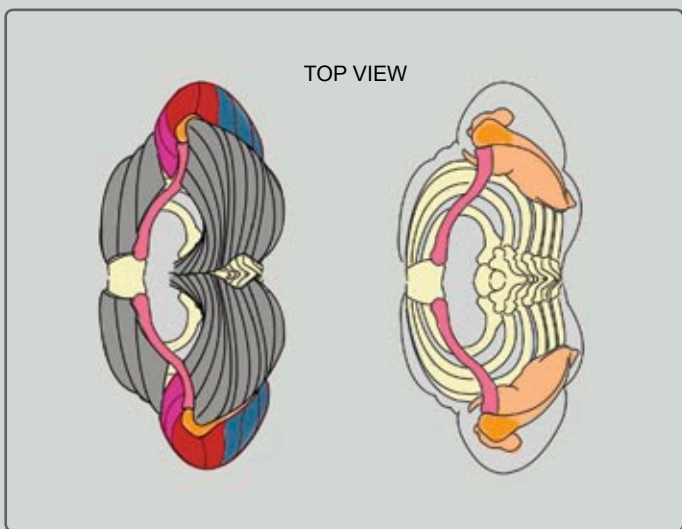
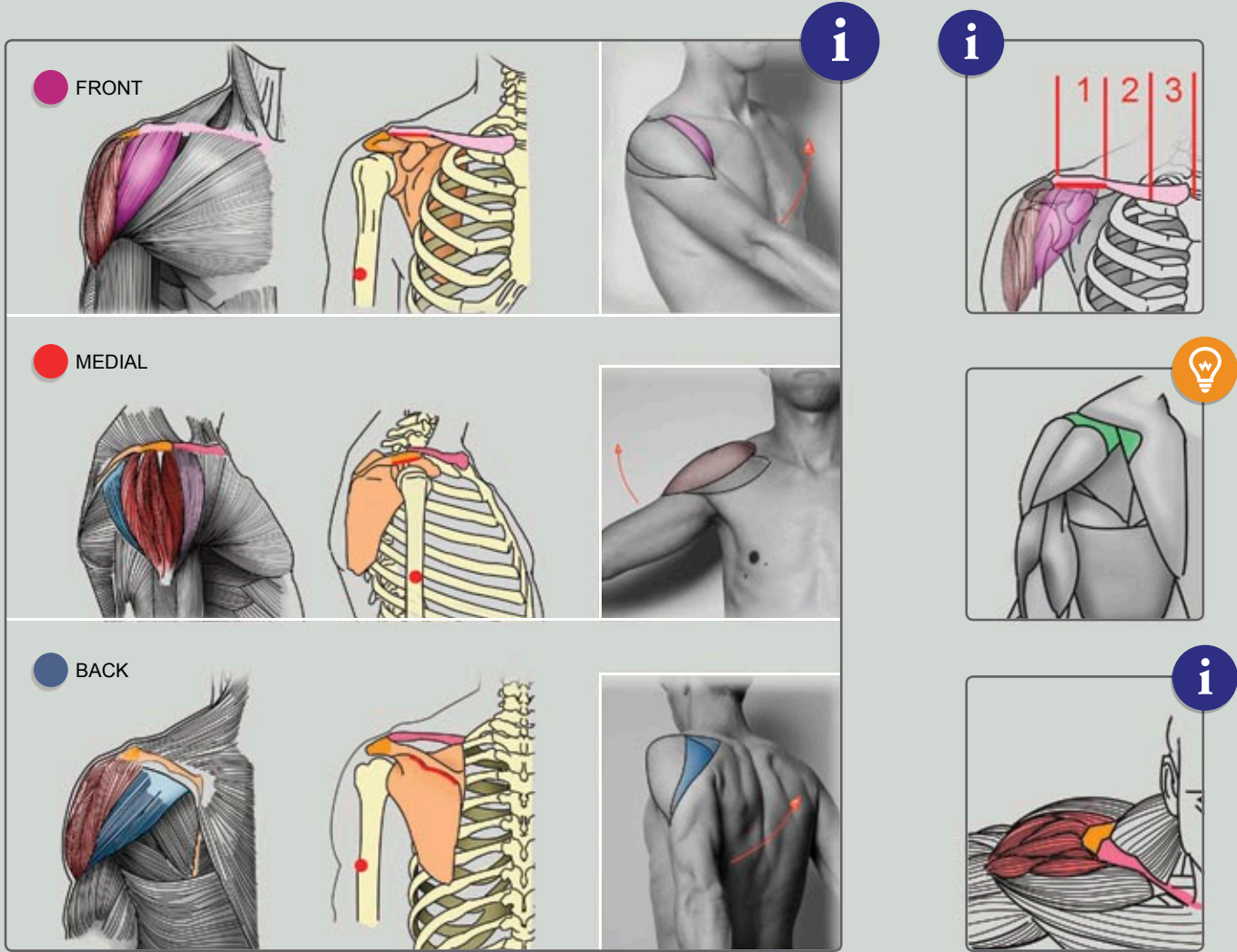


- ① LATERAL END OF **COLLARBONE (CLAVICLE)**
- ② HEAD OF **HUMERUS** PUSHES **SHOULDER MUSCLE (DELTOID)** OUTWARD.
- ③ **TRAPEZIUS**
- ④ LATERAL HEAD OF **SHOULDER MUSCLE (DELTOID)**
- ⑤ LATERAL HEAD OF **TRICEPS**

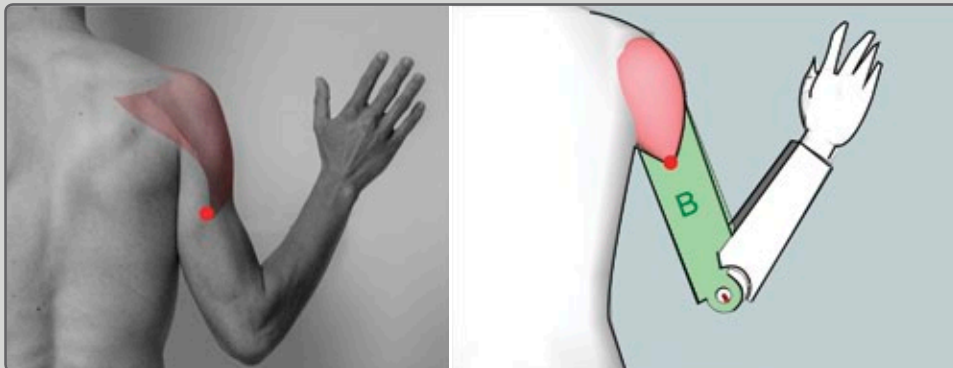
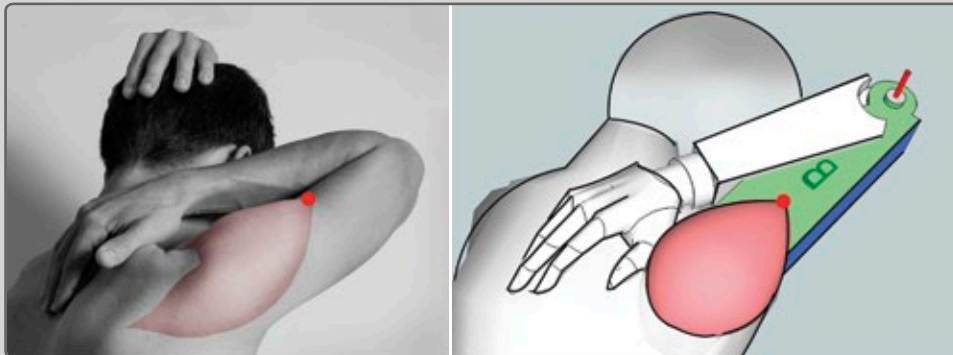
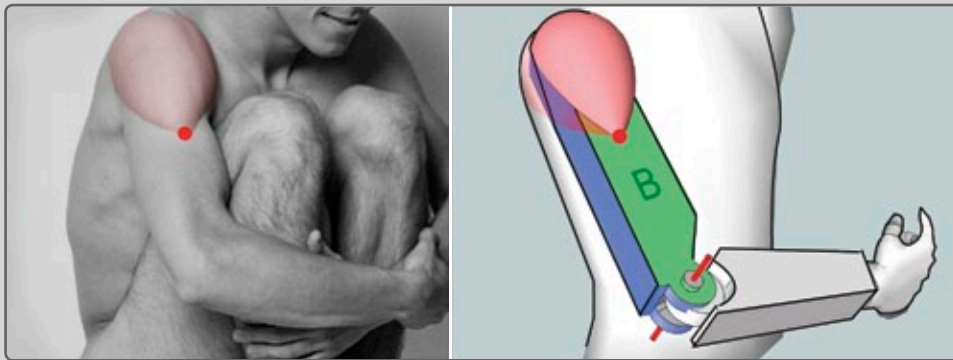
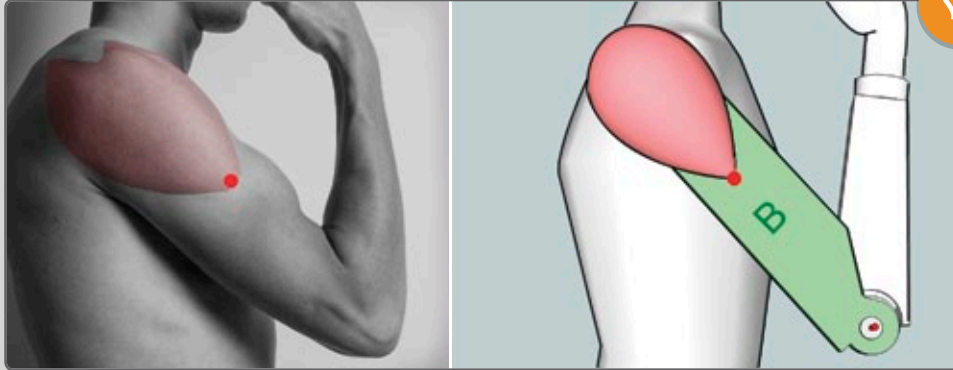
SHOULDER MUSCLE
(DELTOID)



SHOULDER MUSCLE (DELTOID) HAS 3 SECTIONS:
FRONT (ANTERIOR PART), MEDIAL (LATERAL PART) AND BACK (POSTERIOR PART)



WHICHEVER WAY YOU TURN YOUR ARM, THE DELTOID'S LOWER, TAPERED END IS ALWAYS ON THE "B" SURFACE!

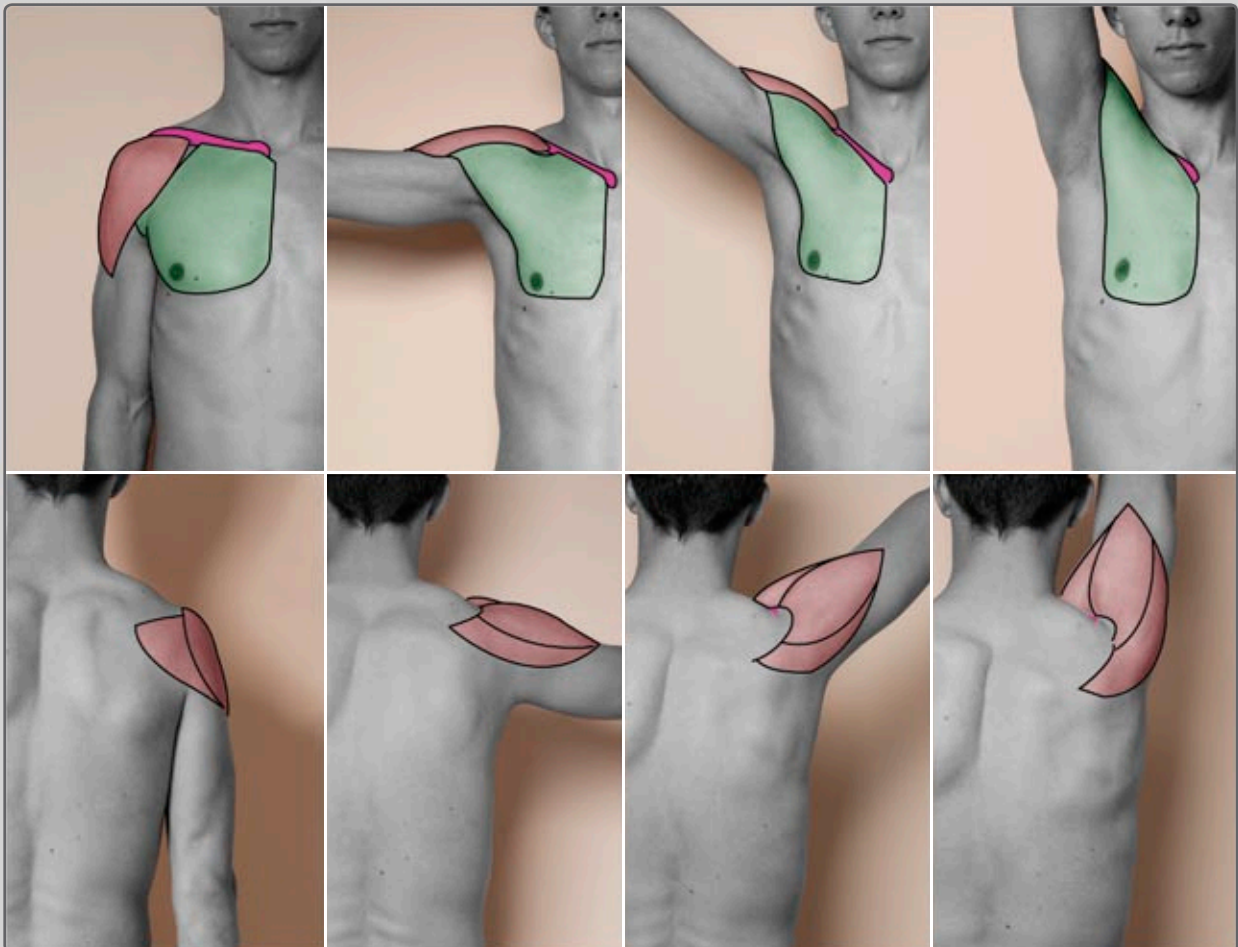
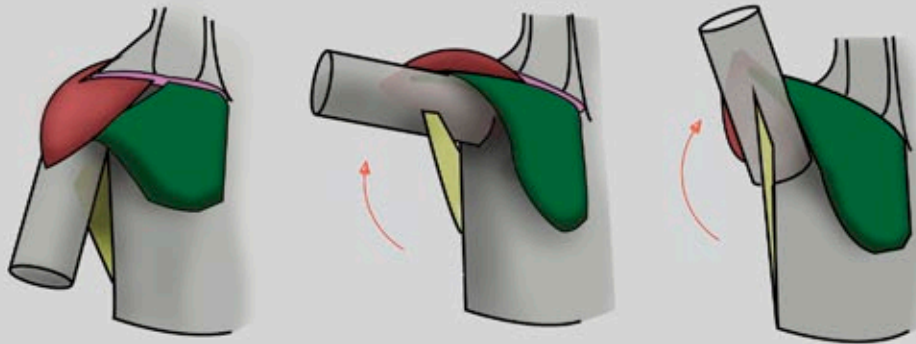


WHERE DOES IT GO?



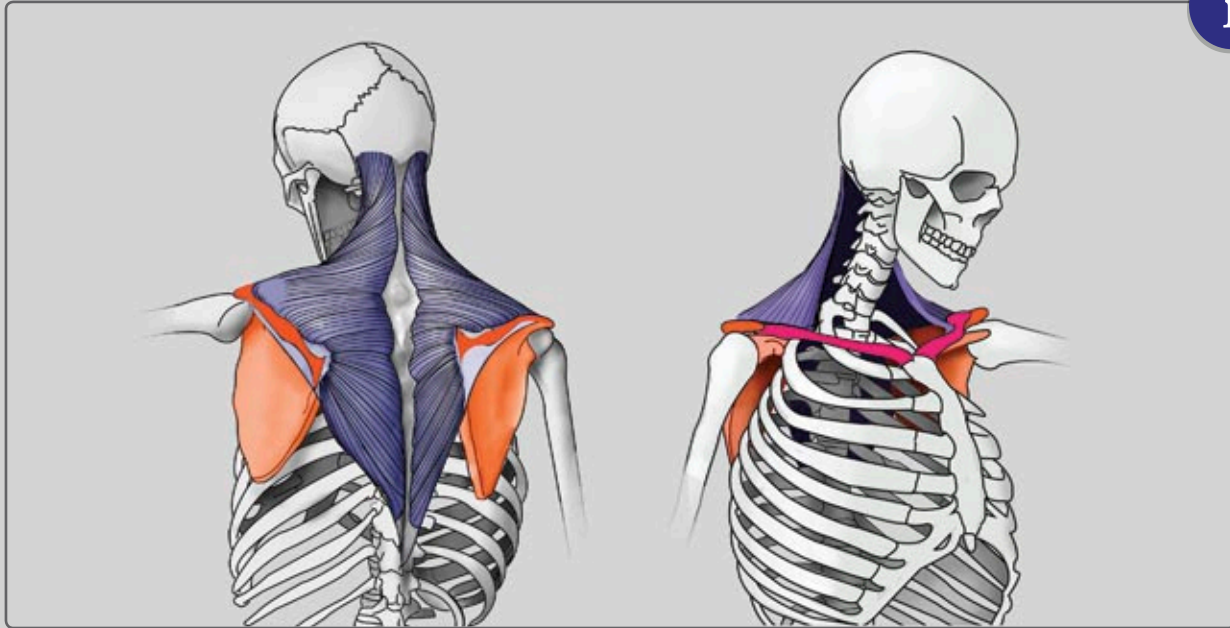WHERE DOES **THE SHOULDER MUSCLE (DELTOID)** DISAPPEAR TO WHEN THE ARM IS LIFTED UP? IT JUST TURNS TOWARD THE BACK AND YOU WILL SEE IT IF YOU LOOK FROM THE OTHER SIDE.

THE CLAVICLE IS ONLY COVERED BY SKIN. IT IS ALWAYS VISIBLE EXCEPT WHEN ARMS ARE LIFTED. THEN, **THE CLAVICLE** IS HIDDEN BEHIND **THE GREAT CHEST MUSCLE (PECTORALIS MAJOR)**.



TRAPEZIUS MUSCLE

i



ORIGIN: MEDIAL SUPERIOR NUCHAL LINE & EXTERNAL PROTUBERANCE OF THE SKULL

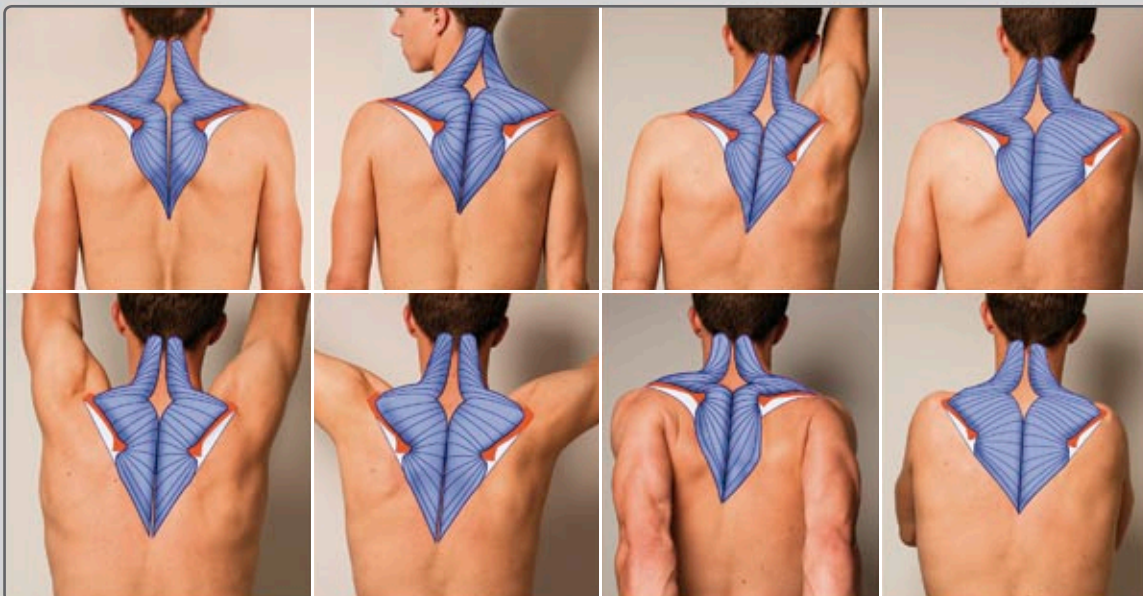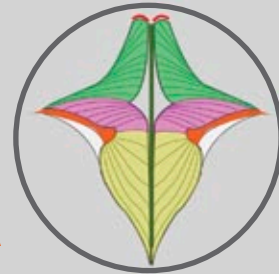
INSERTION: LATERAL CLAVICLE, ACROMION AND SPINE OF SCAPULA

ACTIONS:

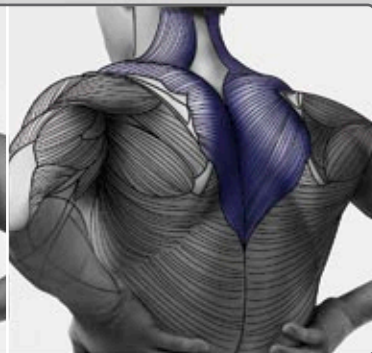
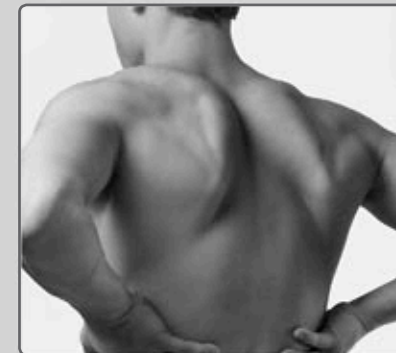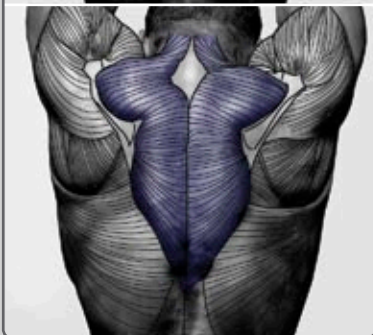
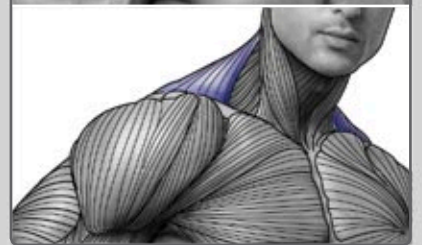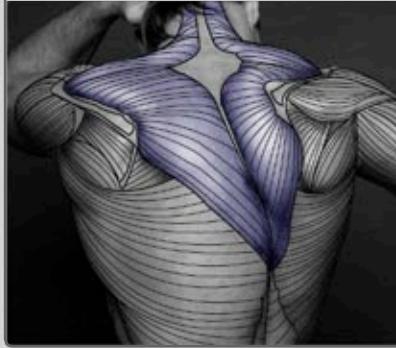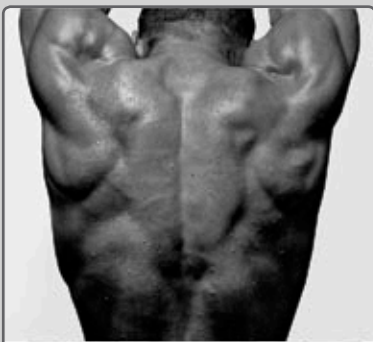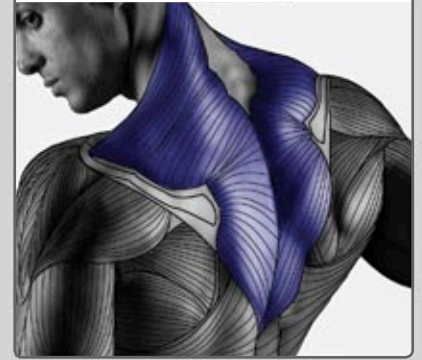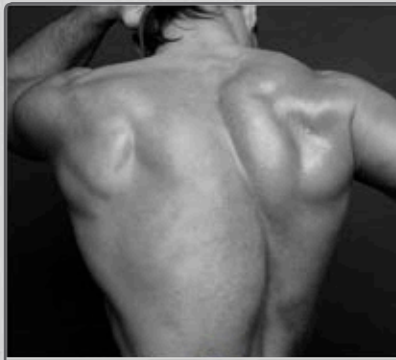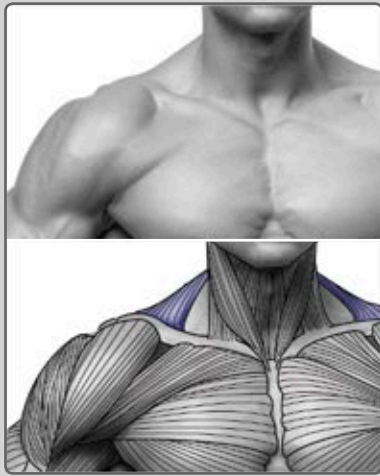
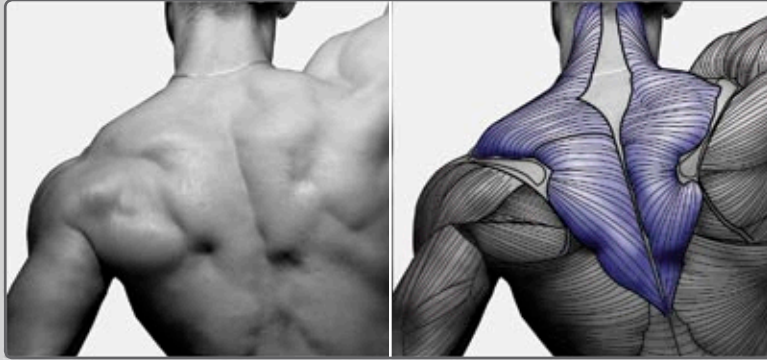
UPPER FIBERS: ELEVATE AND UPWARDLY ROTATE SCAPULA; EXTEND NECK

MIDDLE FIBERS: ADDUCT (RETRACT) SCAPULA

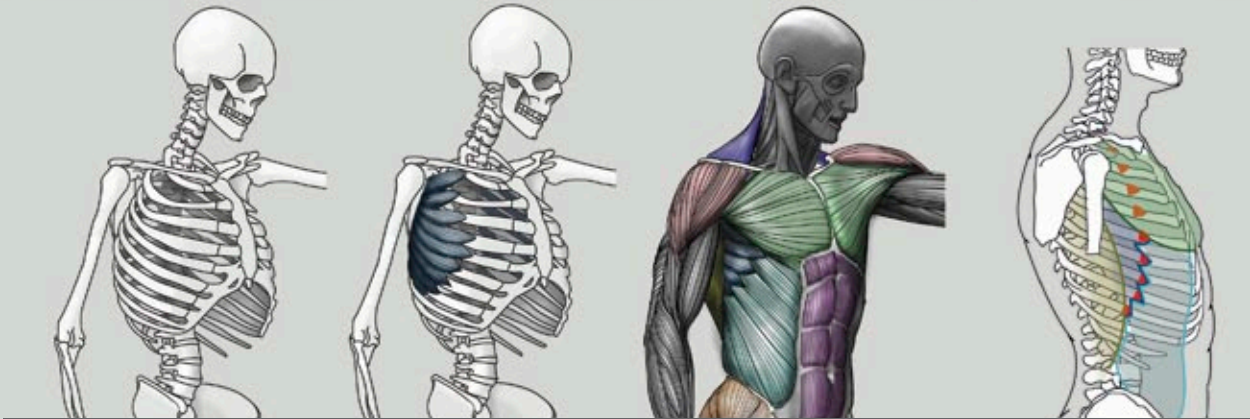

LOWER FIBERS: DEPRESS AND HELP UPPER FIBERS UPWARDLY ROTATE SCAPULA



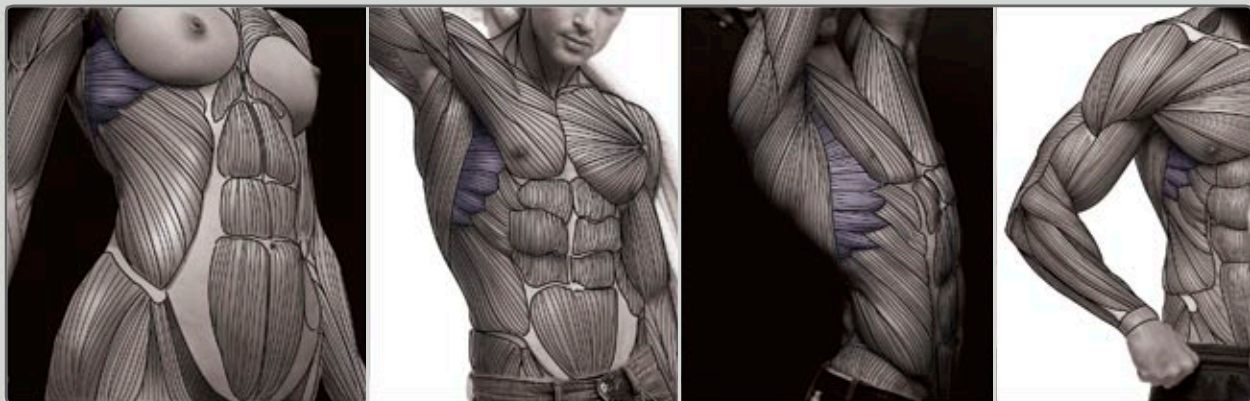
TRAPEZIUS MUSCLE



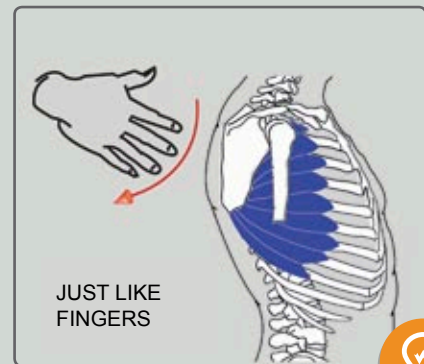
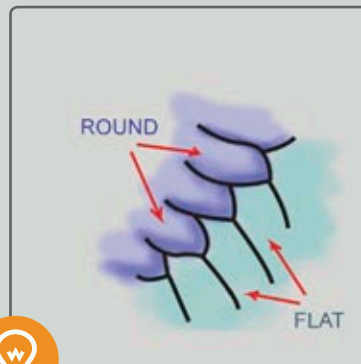
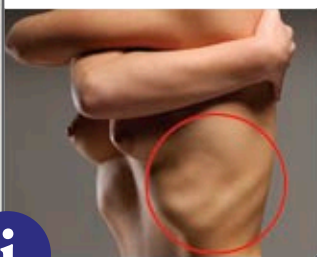
ARE THESE RIBS?



THIS IS A MUSCLE, CALLED **SERRATUS ANTERIOR**

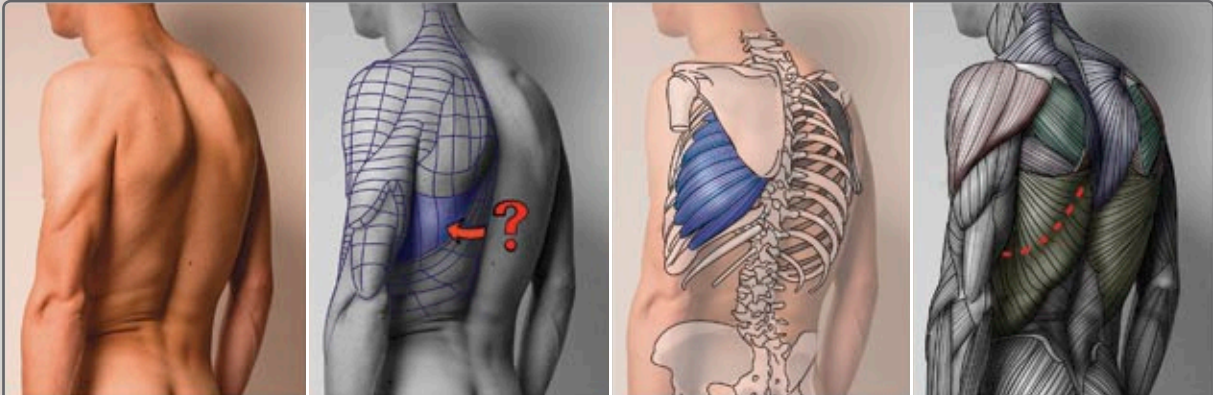


IF PERSON IS SKINNY,
THEN **SERRATUS** IS TOO
FLAT TO BE VISIBLE.



JUST LIKE
FINGERS

WHAT IS THIS BULGE UNDER THE SHOULDER BLADE?

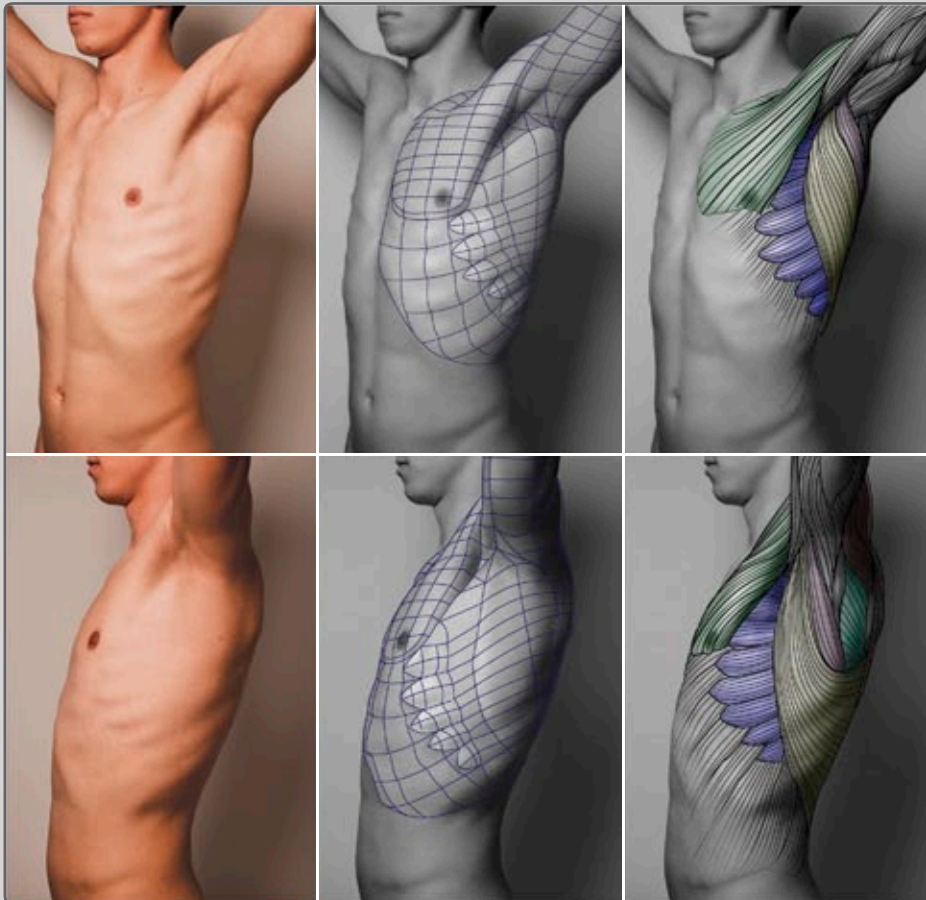


IT IS **THE SERRATUS ANTERIOR** MUSCLE, PUSHING THE **LATISSIMUS DORSI** OUTWARD FROM BENEATH.

i

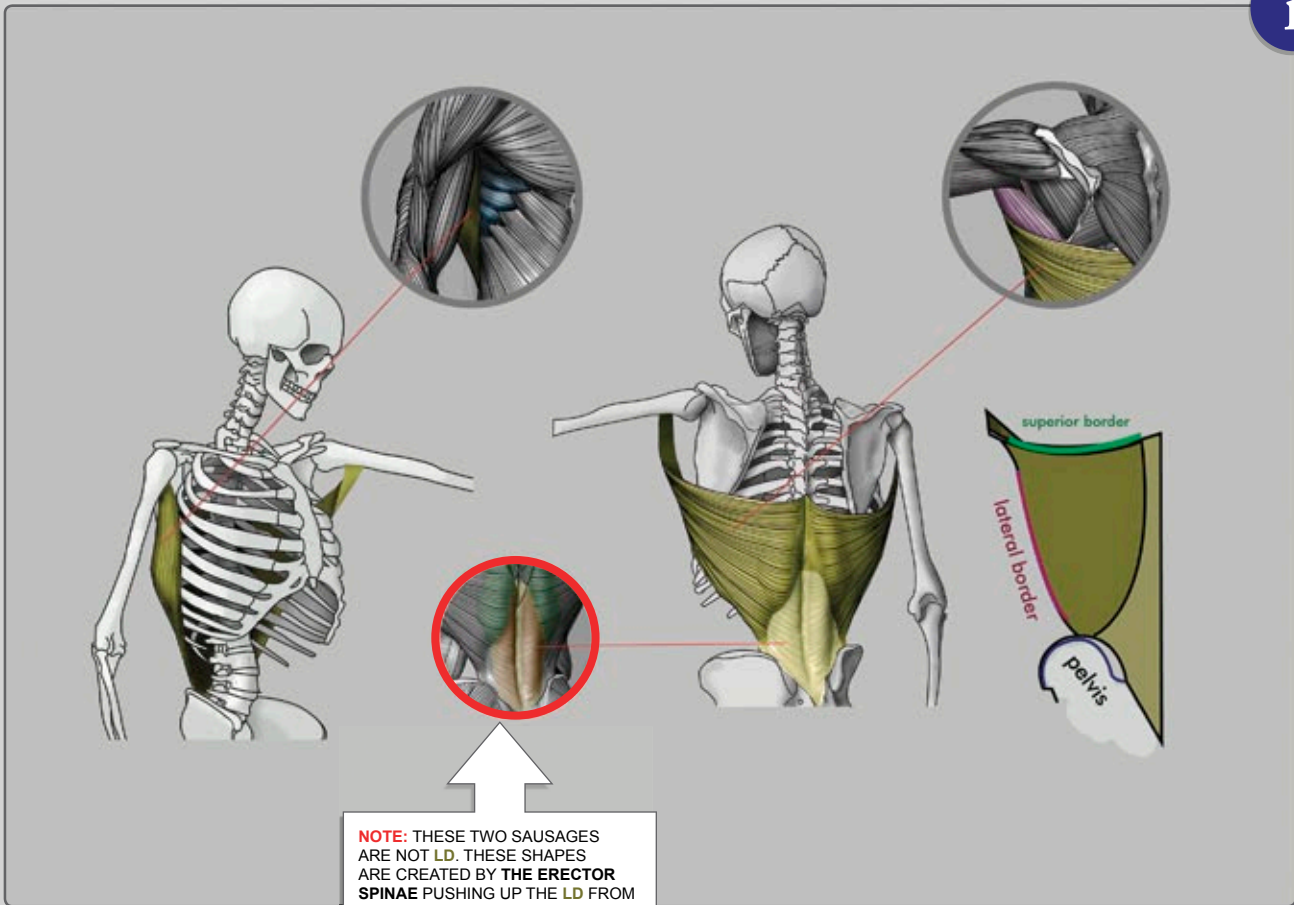
SERRATUS ANTERIOR IS A MUSCLE THAT ORIGINATES ON THE SURFACES OF THE **1ST TO 8TH** RIBS ON THE LATERAL CHEST AND INSERTS ALONG THE ENTIRE ANTERIOR LENGTH OF THE MEDIAL BORDER OF THE SCAPULA.

1/4 AND SIDE VIEW



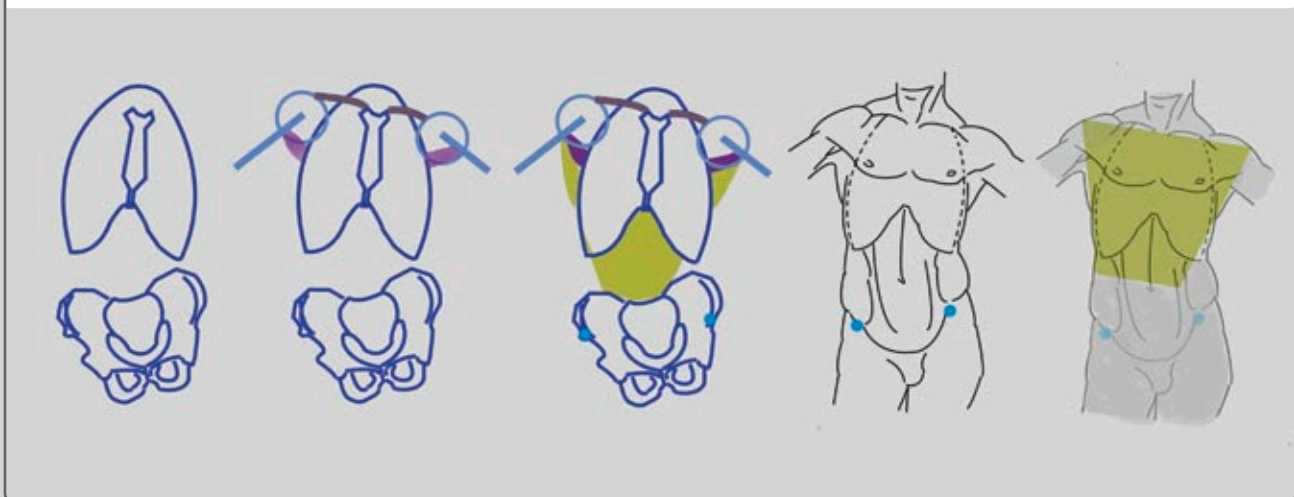
BROADEST MUSCLE OF THE BACK (LATISSIMUS DORSI - LD)

i

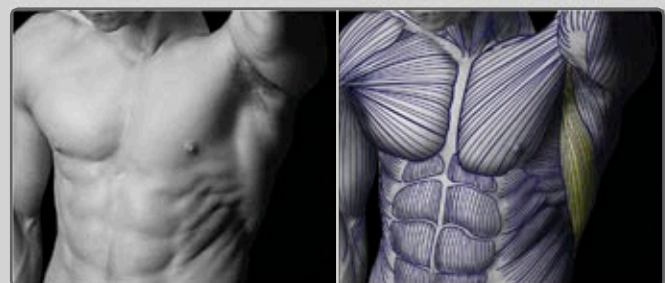
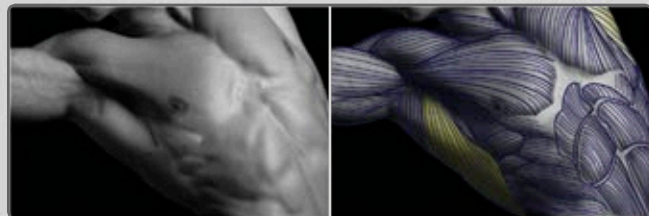
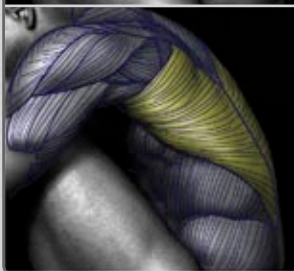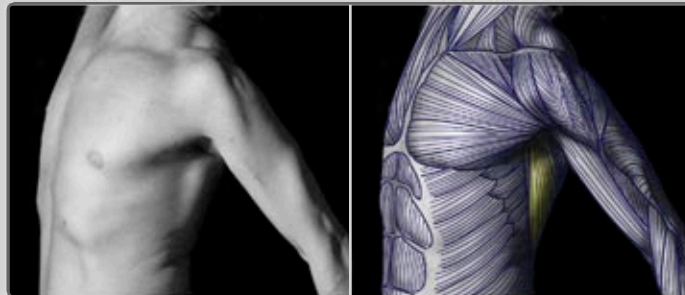
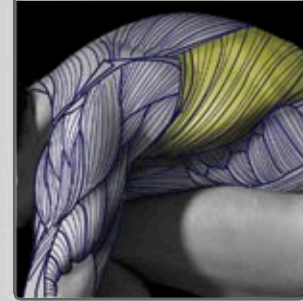
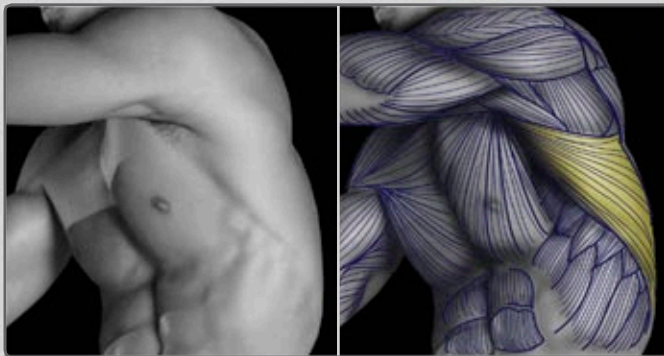

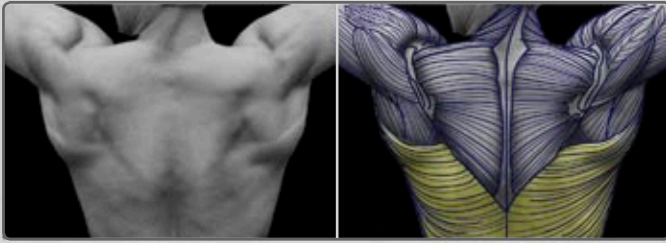
💡


TERES MAJOR COVERED WITH **LATISSIMUS DORSI** CREATES THE TRIANGULAR SHAPE OF A MALE TORSO.



IDENTIFY THE BROADEST MUSCLE OF THE BACK!
(LATISSIMUS DORSI)

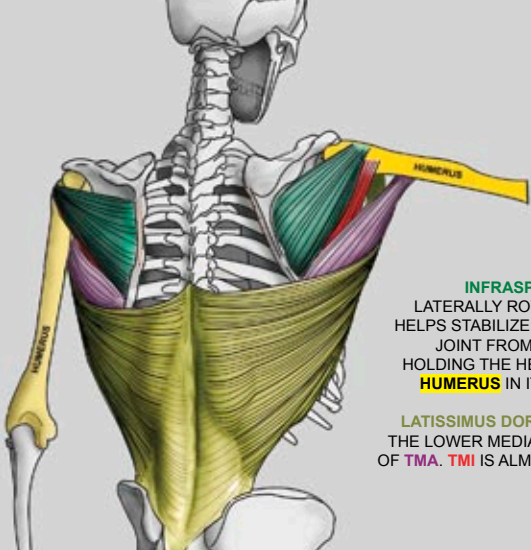


GREAT ROUND MUSCLE (TERES MAJOR TMA), LITTLE ROUND MUSCLE (TERES MINOR TMI) AND INFRASPINATUS MUSCLE (IS)



ACTIONS: ADDUCTS AND MEDIANLY ROTATES ARM; EXTENDS A FLEXED ARM.


NOTE: TMA AND TMI BOTH ADDUCT THE ARM, BUT ARE ANTAGONISTS FOR ROTATION OF THE HUMERUS. TMA ROTATES IT TOWARDS THE BODY; TMI ROTATES IT TO THE SIDE.



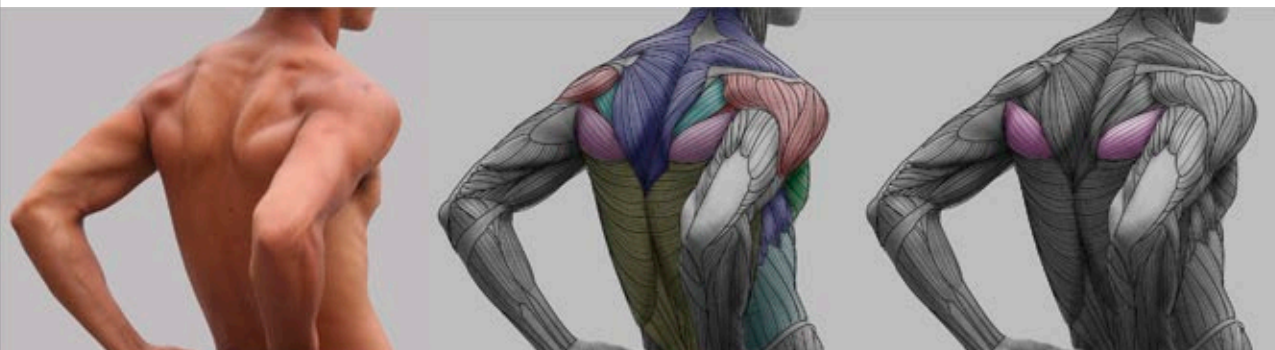
INFRASPINATUS (IS)
LATERALLY ROTATES ARM;
HELPS STABILIZE SHOULDER
JOINT FROM BEHIND BY
HOLDING THE HEAD OF THE
HUMERUS IN ITS SOCKET.

LATISSIMUS DORSI COVERS
THE LOWER MEDIAL PORTION
OF TMA. TMI IS ALMOST NEVER
VISIBLE.

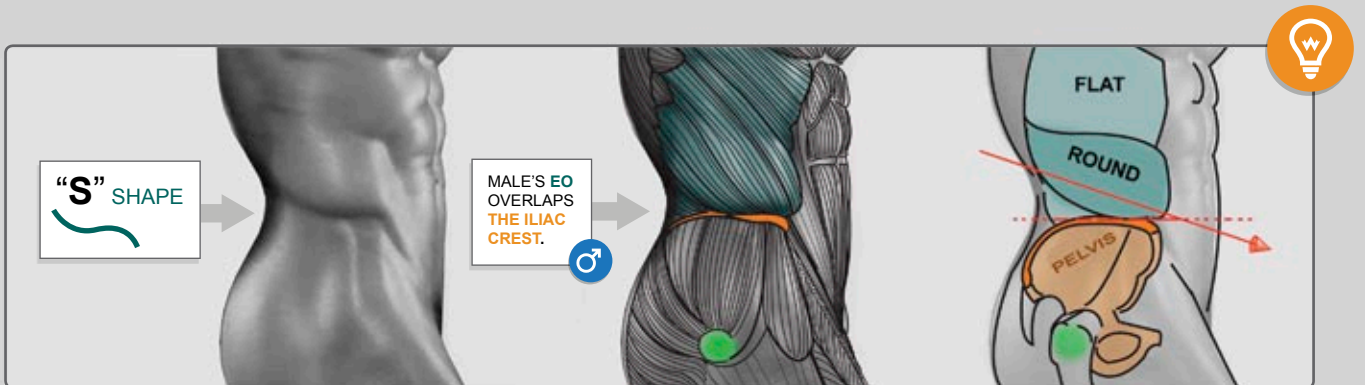
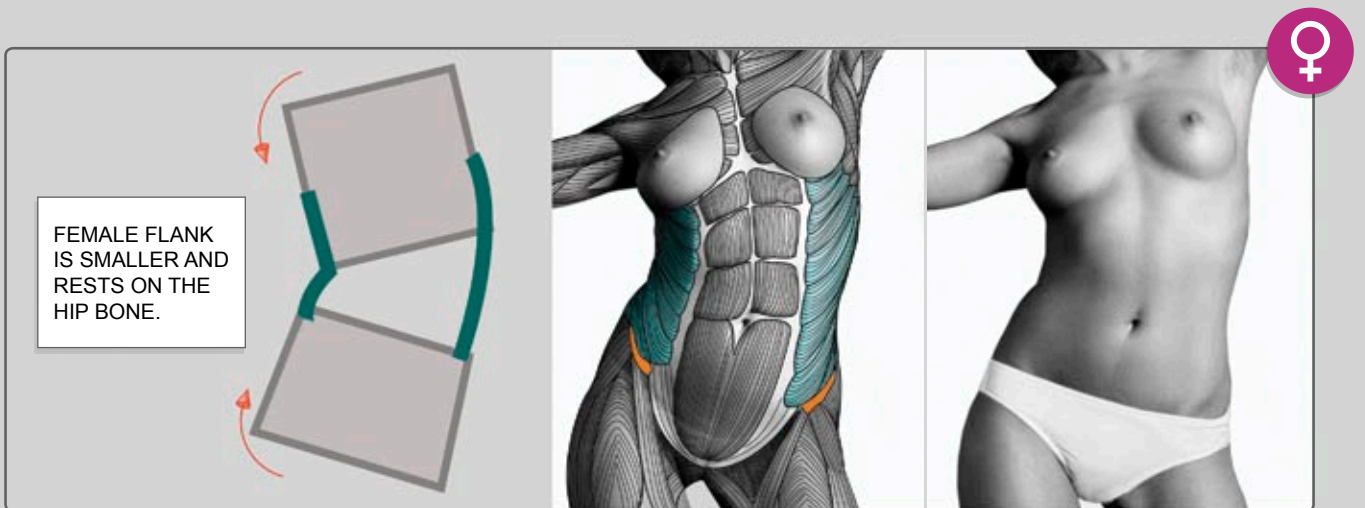
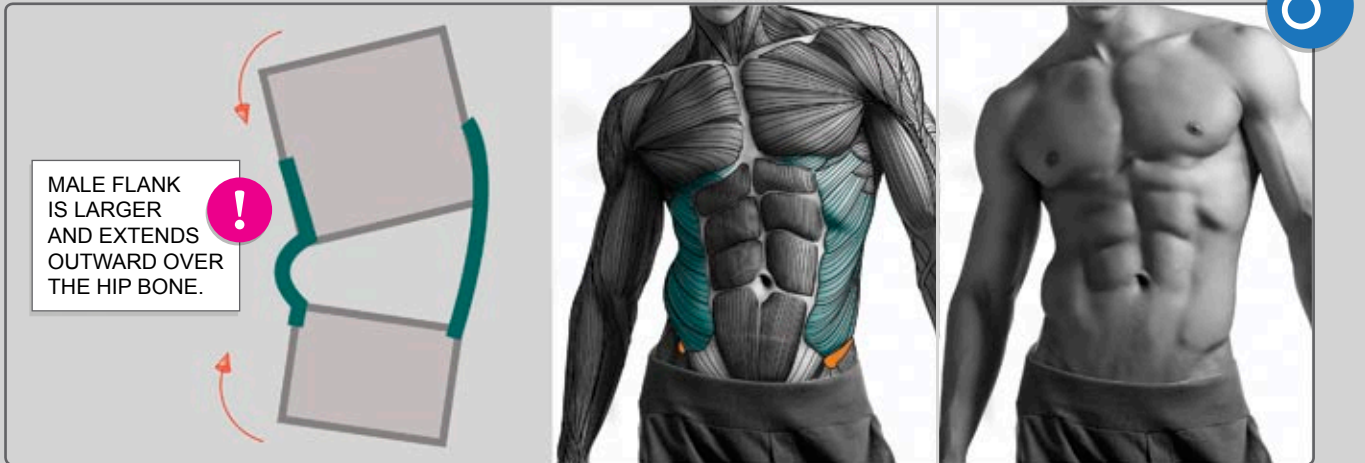
TMI IS ALMOST NEVER VISIBLE.



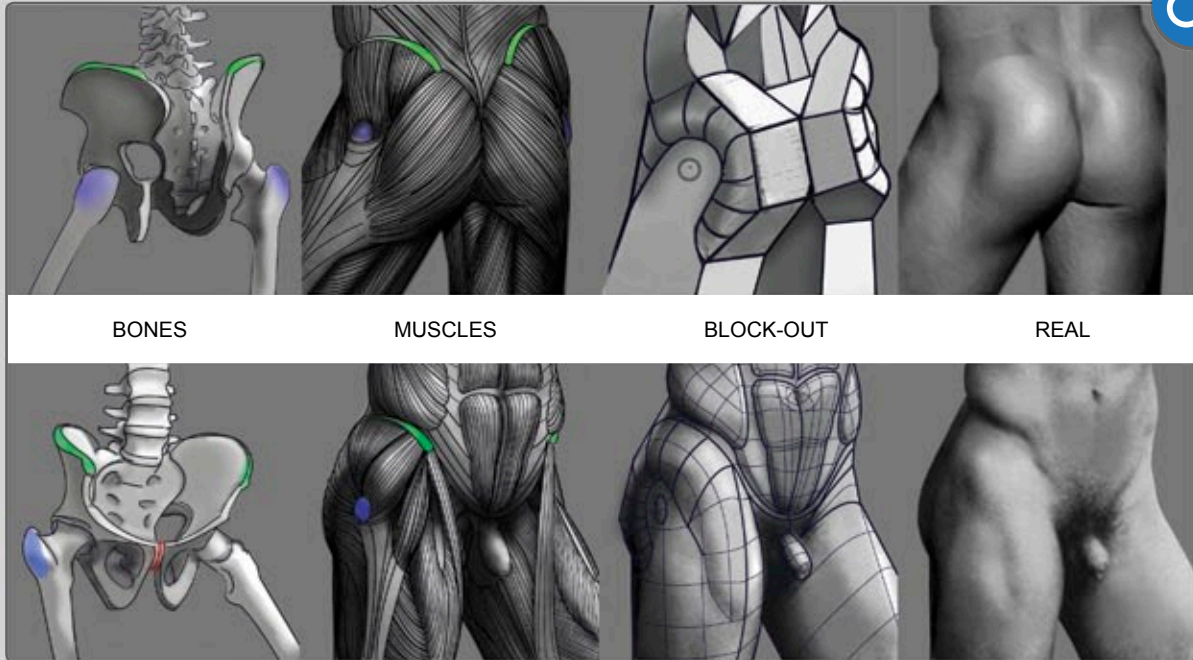
GREAT ROUND MUSCLE (TERES MAJOR) BECOMES PRONOUNCED WHEN ARMS ARE HELD BEHIND THE TORSO.



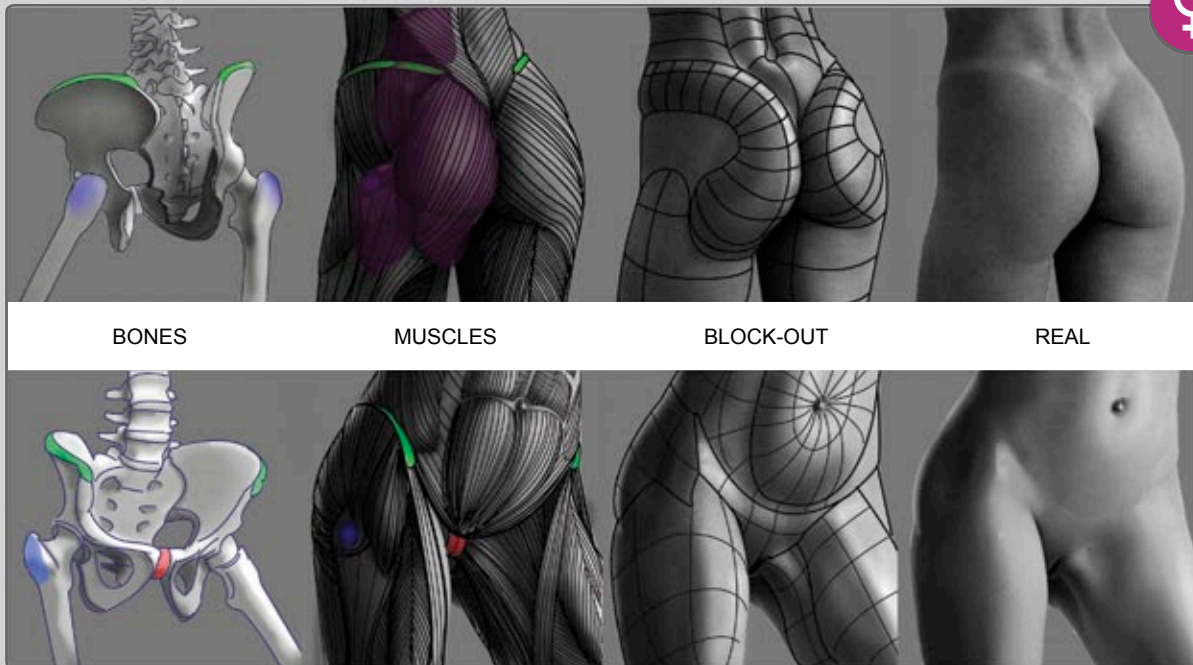
ABDOMINAL EXTERNAL OBLIQUE MUSCLE (EO)



MALE AND FEMALE HIPS

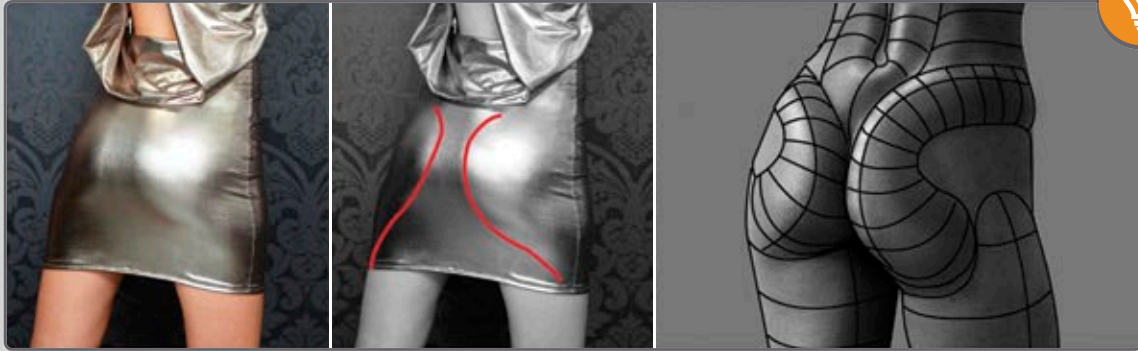

● GREATER TROCHANTER
 ● ILIAC CREST
 ● PUBIC SYMPHYSIS

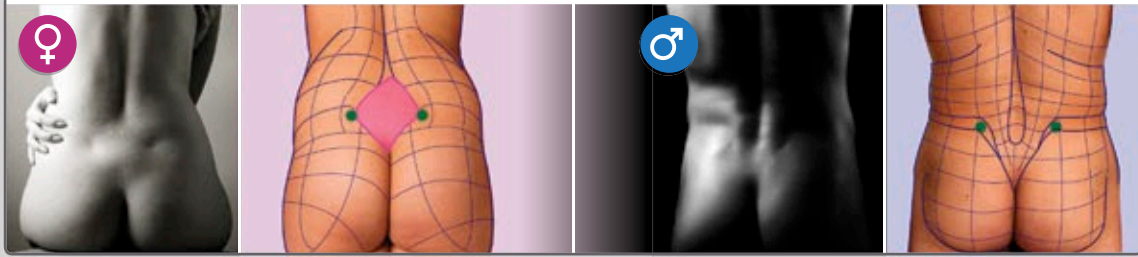


! SUBCUTANEOUS **FAT PADS** UNDER THE SKIN GIVE FEMALE HIPS THEIR CURVY SHAPE.

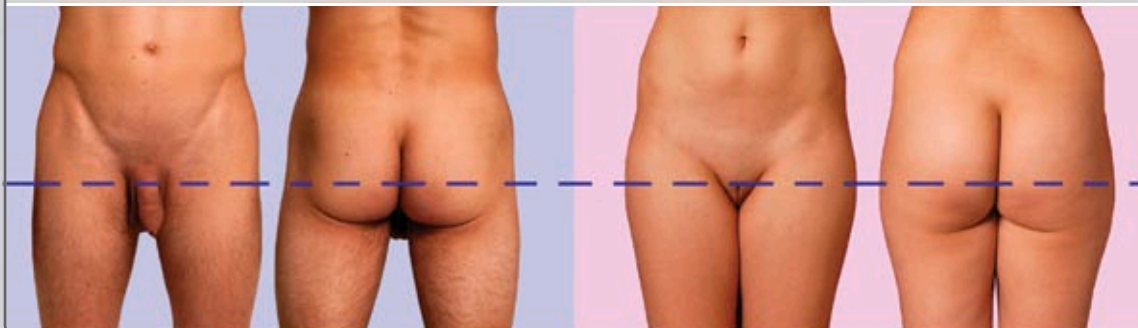
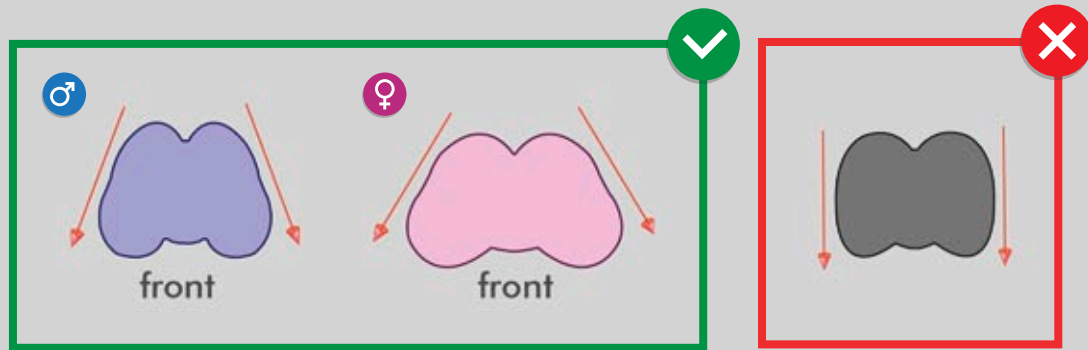
ALL ABOUT “BACKSIDES”



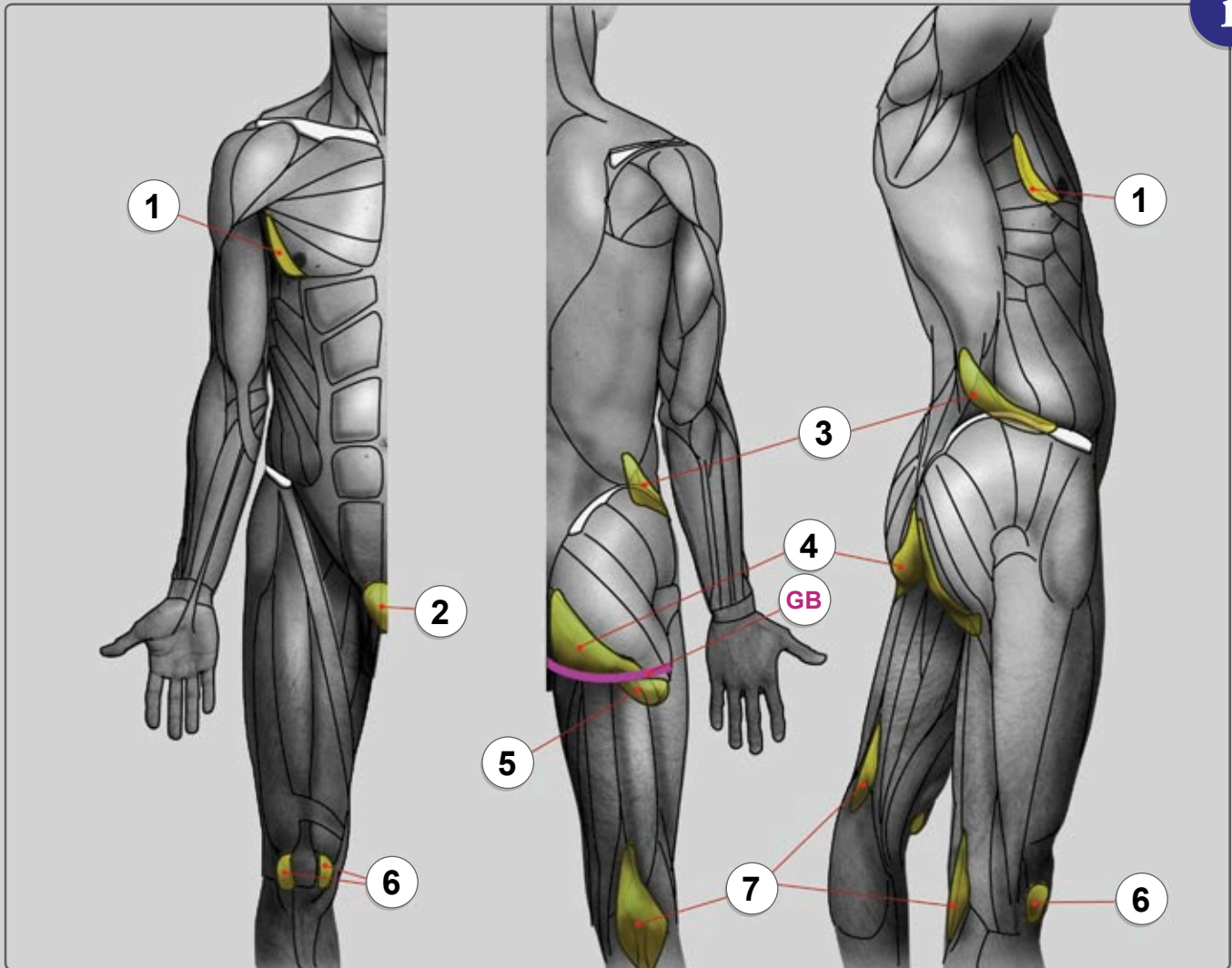
THE “RHOMBUS OF MICHAELIS” IS A FAT PAD THAT IS SOMETIMES VISIBLE ON THE LOWER BACK OF FEMALES.



HORIZONTAL CROSS SECTIONS OF MALE AND FEMALE PELVIS.

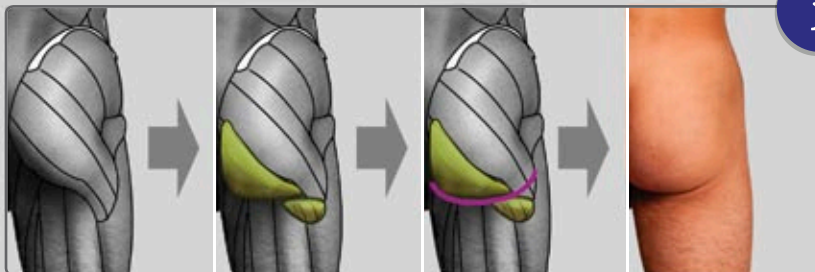


MALE SUBCUTANEOUS FAT PADS

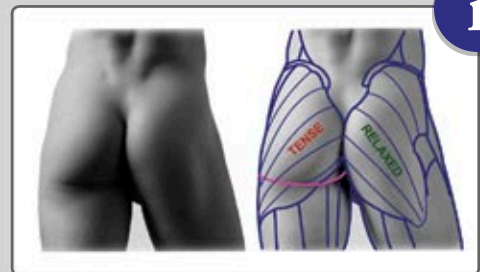


i

- 1 PECTORAL FAT PAD
- 2 PUBIC FAT PAD
- 3 FLANK FAT PAD
- 4 LATERAL GLUTEAL FAT PAD
- 5 INFERIOR GLUTEAL FAT EXTENSION
- 6 INFRAPATELLAR FAT PAD
- 7 POPLITEAL FAT PAD
- GB **GLUTEAL BAND** – CREATES SKIN FOLD. WHEN THE THIGH FLEXES, GLUTEAL FOLD DISAPPEARS.

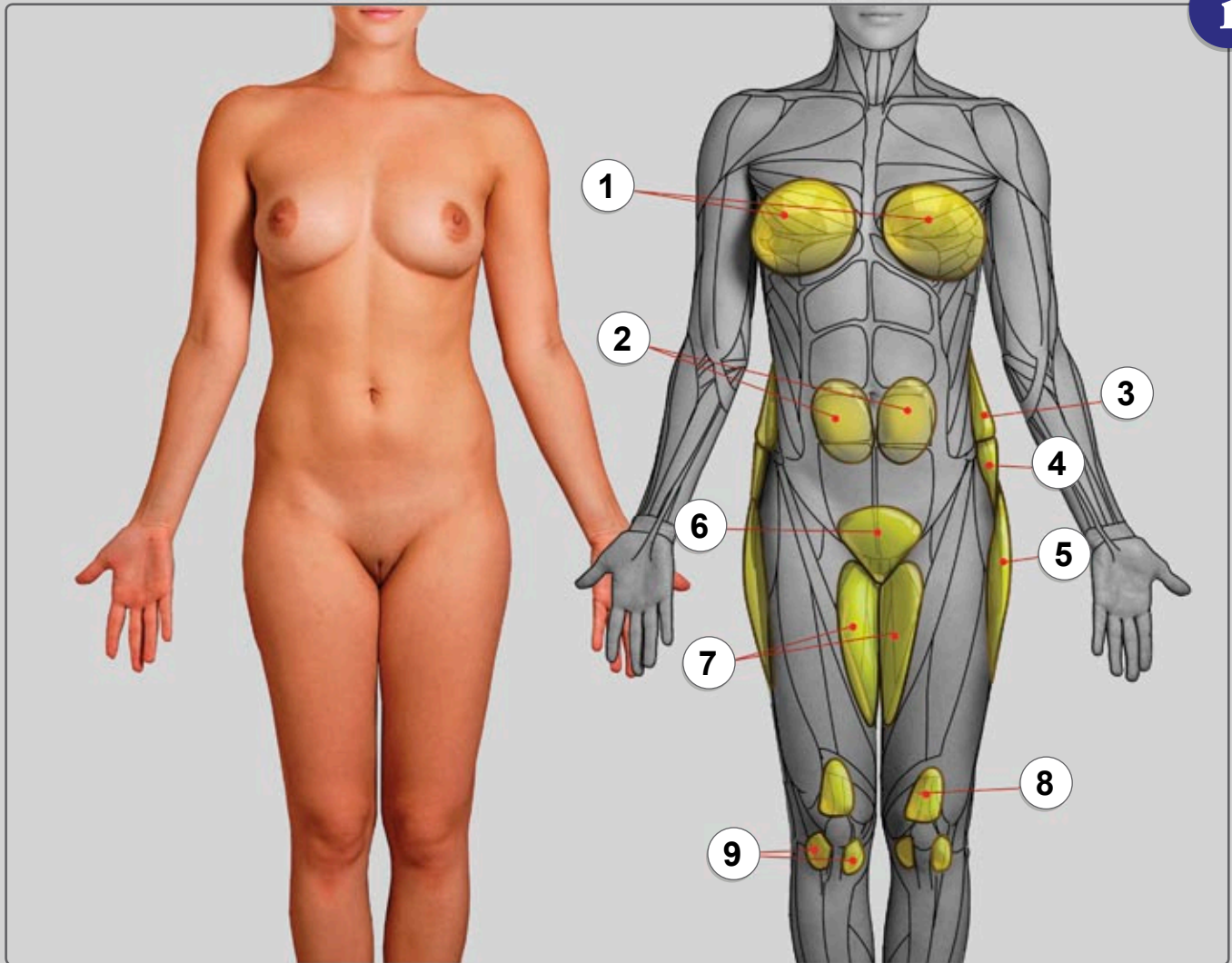


i



i

FEMALE SUBCUTANEOUS FAT PADS (FRONT VIEW)



1 BREAST FAT

2 ABDOMINAL WALL FAT PAD

3 FLANK FAT PAD

4 LATERAL GLUTEAL FAT PAD

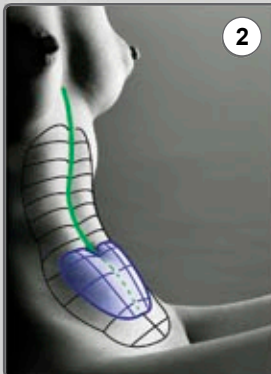
5 OUTER THIGH FAT PAD

6 PUBIC FAT PAD

7 INNER THIGH FAT PAD

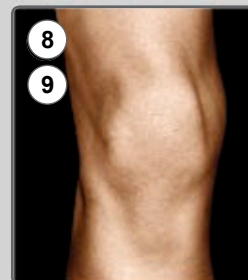
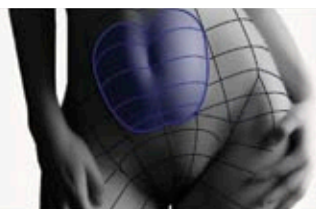
8 LOWER ANTERIOR THIGH FAT PAD

9 INFRAPATELLAR FAT PAD



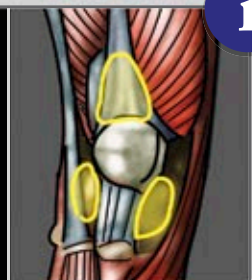
2

AS ABDOMINAL WALL FAT PADS (AWFP) GET LARGER, THAT PART OF THE LINEA ALBA WHICH CONTINUES UNDER THE NAVEL, WILL BE LESS PRONOUNCED, BECAUSE ARE COVERED BY A THICKER LAYER OF FAT. WHEN THERE IS SOME EXCESS BELLY FAT, THE AWFP APPEARS "APPLE" SHAPED.



8

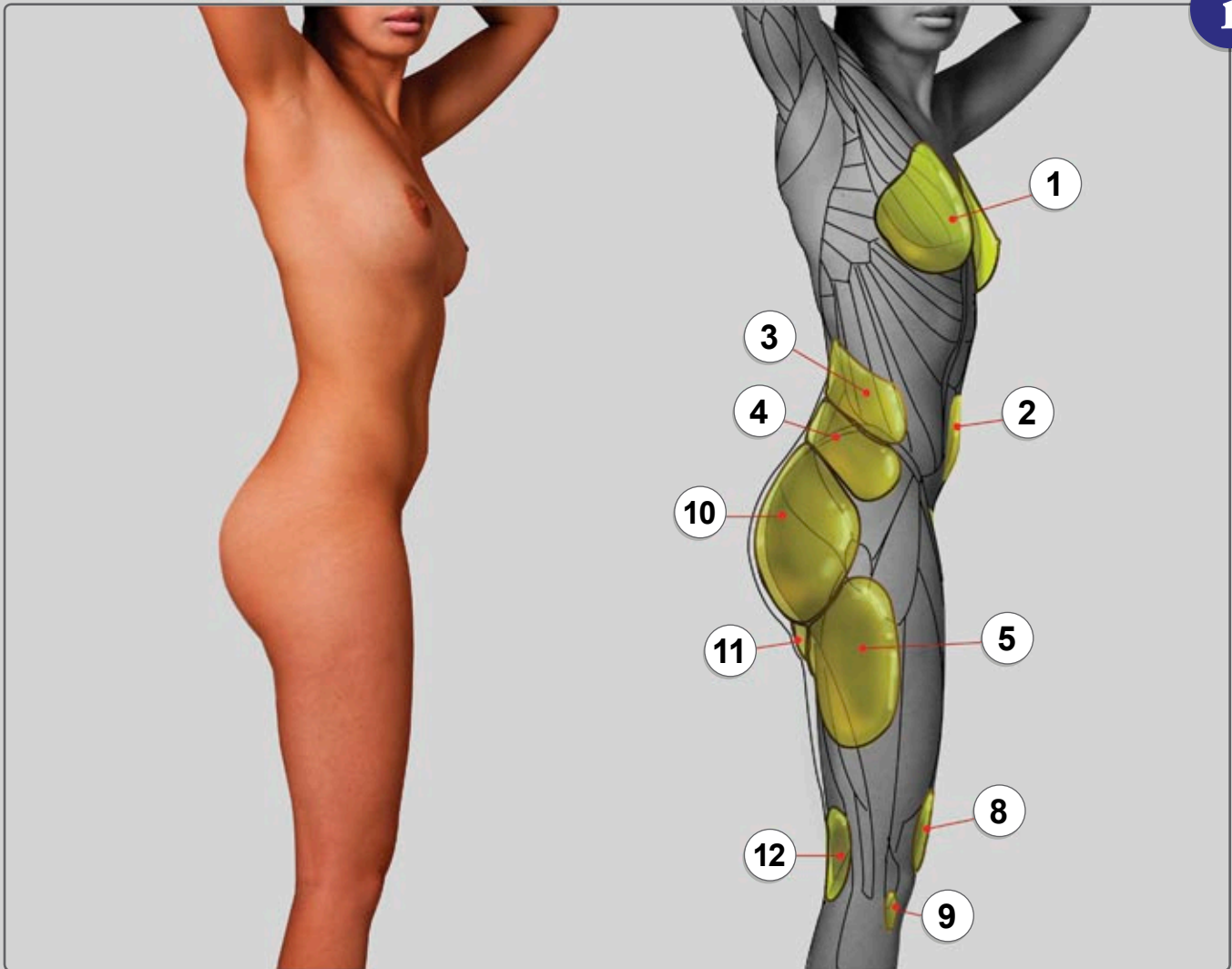
9



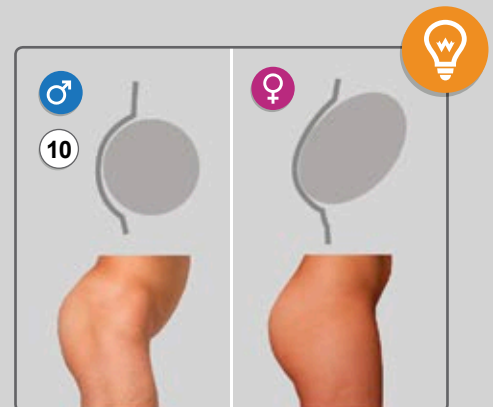
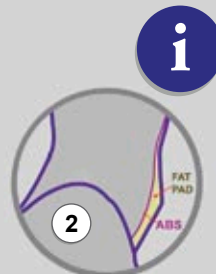
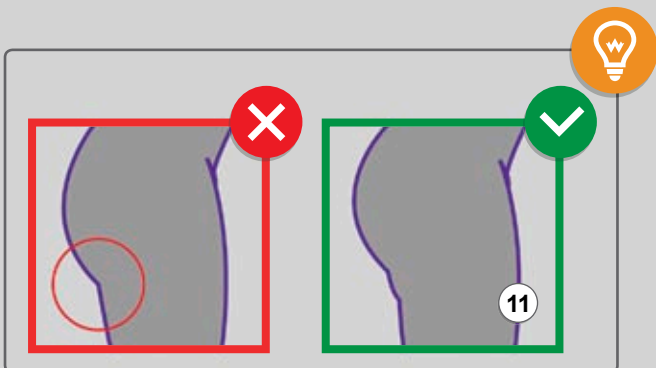
RIGHT KNEE



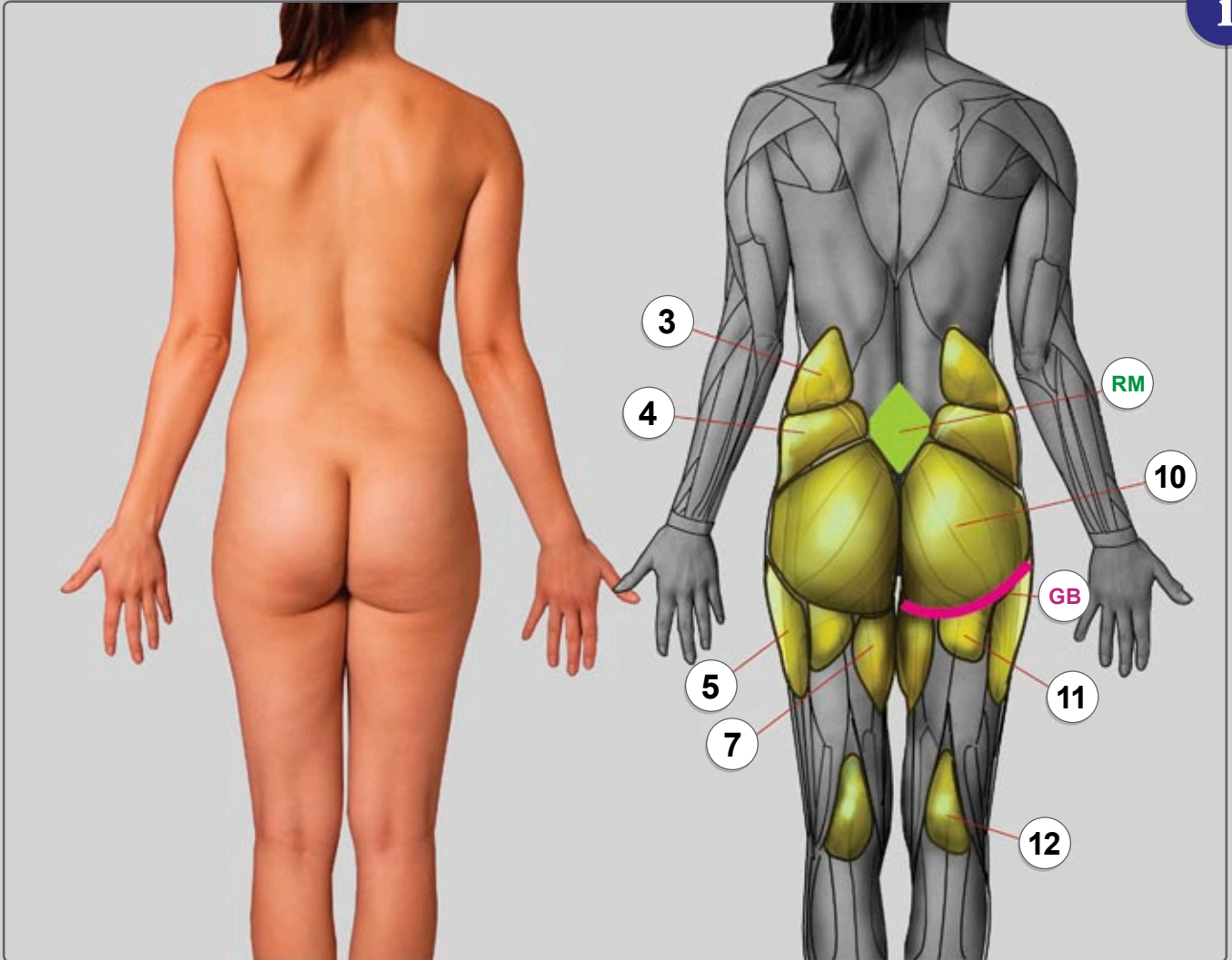
FEMALE SUBCUTANEOUS FAT PADS (SIDE VIEW)



- | | | |
|---------------------------|--------------------------------|-----------------------------------|
| 1 BREAST FAT | 5 OUTER THIGH FAT PAD | 11 INFERIOR GLUTEAL FAT EXTENSION |
| 2 ABDOMINAL FAT PAD | 8 LOWER ANTERIOR THIGH FAT PAD | 12 POPLITEAL FAT PAD |
| 3 FLANK FAT PAD | 9 INFRAPATELLAR FAT PAD | |
| 4 LATERAL GLUTEAL FAT PAD | 10 POSTERIOR GLUTEAL FAT PAD | |

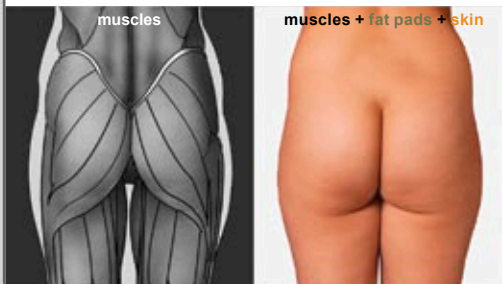


FEMALE SUBCUTANEOUS FAT PADS (BACK VIEW)

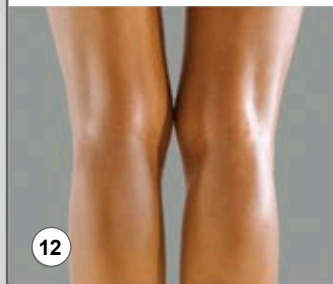

- 3 FLANK FAT PAD
- 4 LATERAL GLUTEAL FAT PAD
- 5 OUTER THIGH FAT PAD
- 7 INNER THIGH FAT PAD
- 10 POSTERIOR GLUTEAL FAT PAD
- 11 INFERIOR GLUTEAL FAT EXTENSION
- 12 POPLITEAL FAT PAD
- RM "RHOMBUS OF MICHAELIS"
- GB GLUTEAL BAND – CREATES SKIN FOLD. WHEN THE THIGH IS FLEXED, GLUTEAL FOLD DISAPPEARS

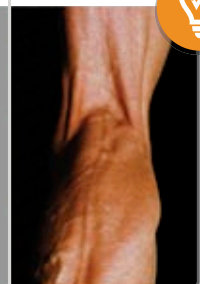
FEMALES HAVE MORE AND MUCH THICKER SUBCUTANEOUS FAT PADS THAN MALES. THIS IS WHY "TYPICAL FEMALE CURVES" APPEAR.



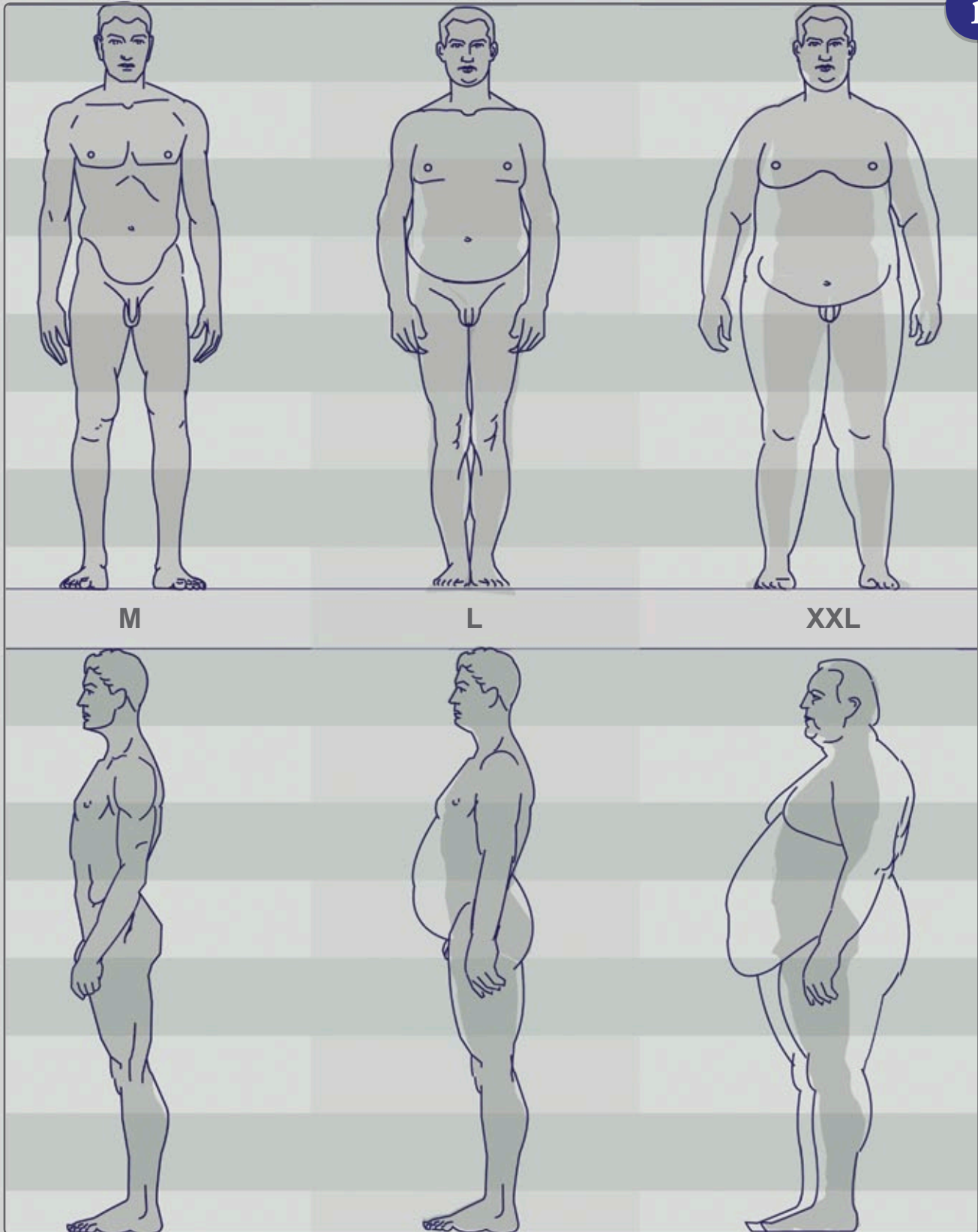
WHEN THE LEG IS STRAIGHT, POPLITEAL FAT PAD POPS OUT!



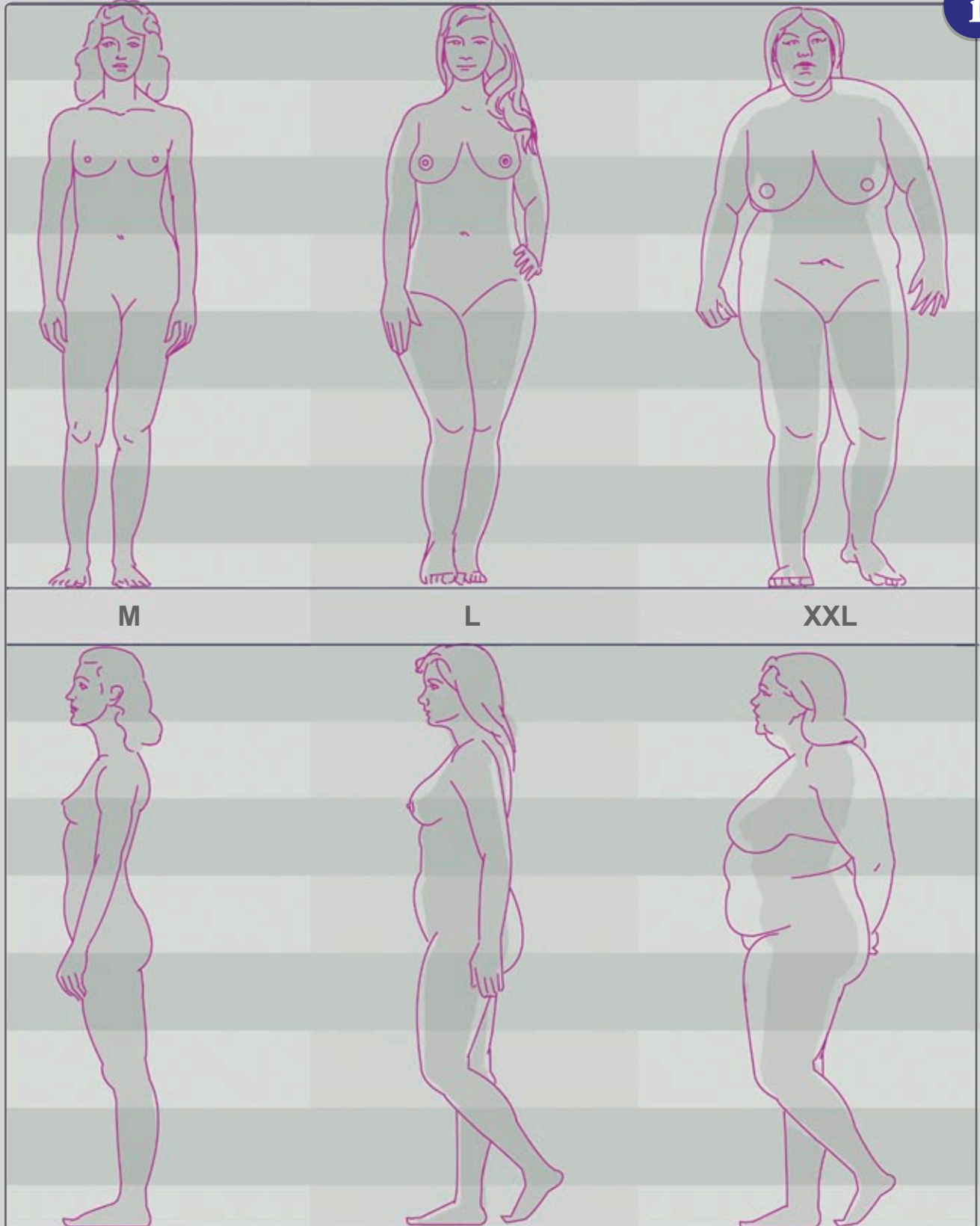
EXTREMELY FATLESS (DRY) BODY CASE.



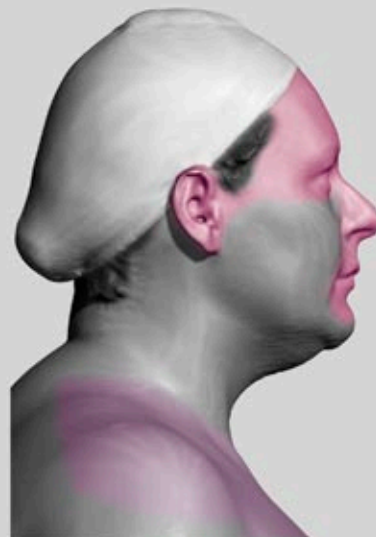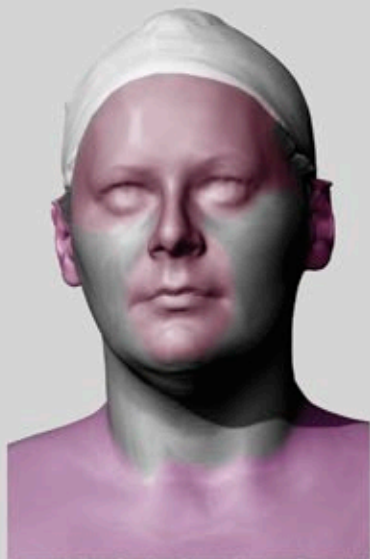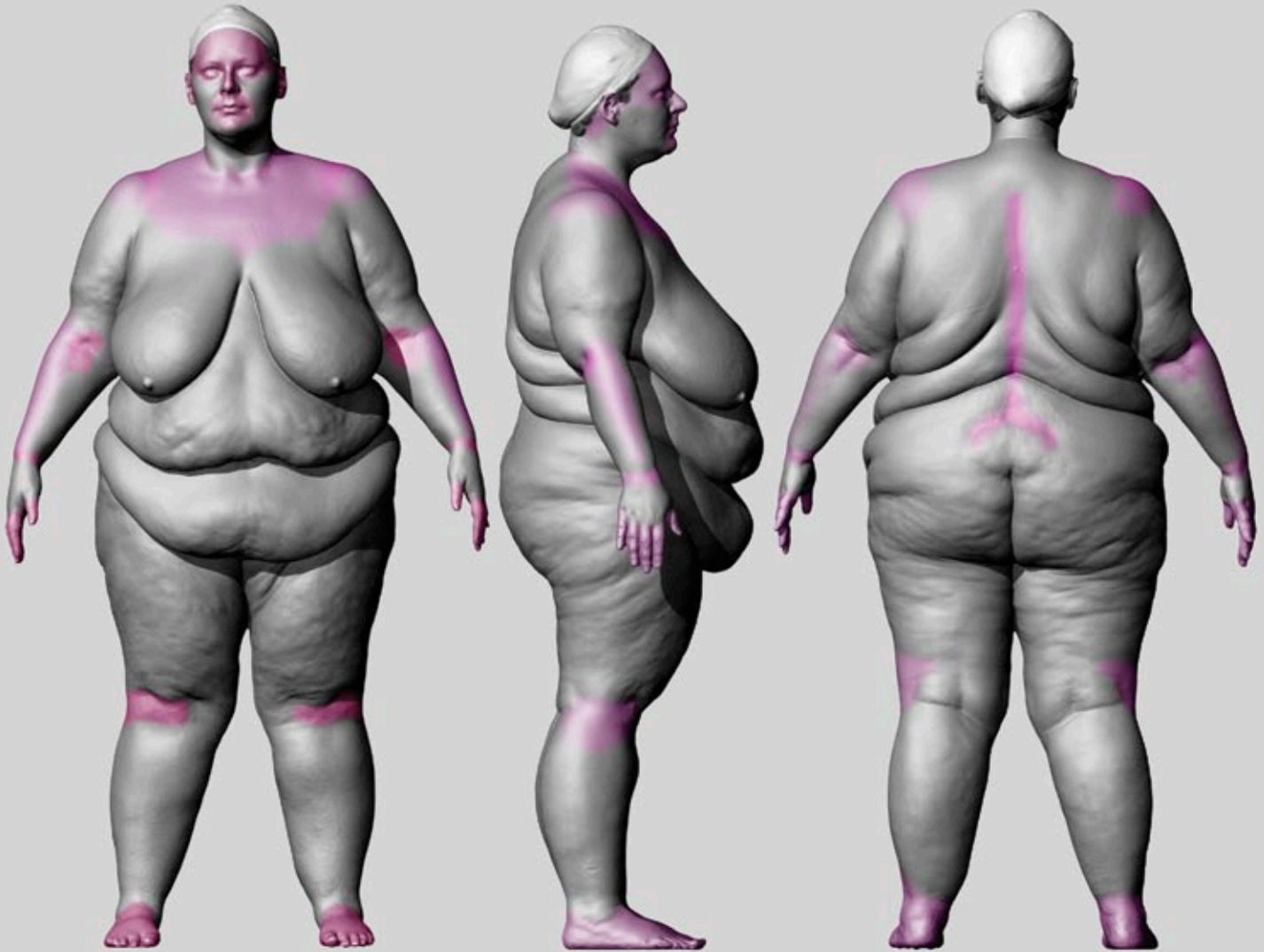
PROPORTIONAL CHANGES OF AN OBESE MALE: 7.5 HEAD UNITS




PROPORTIONAL CHANGES OF AN OBESE FEMALE: 7.5 HEAD UNITS



AREAS OF THE BODY THAT ARE LESS AFFECTED BY FAT ACCUMULATION



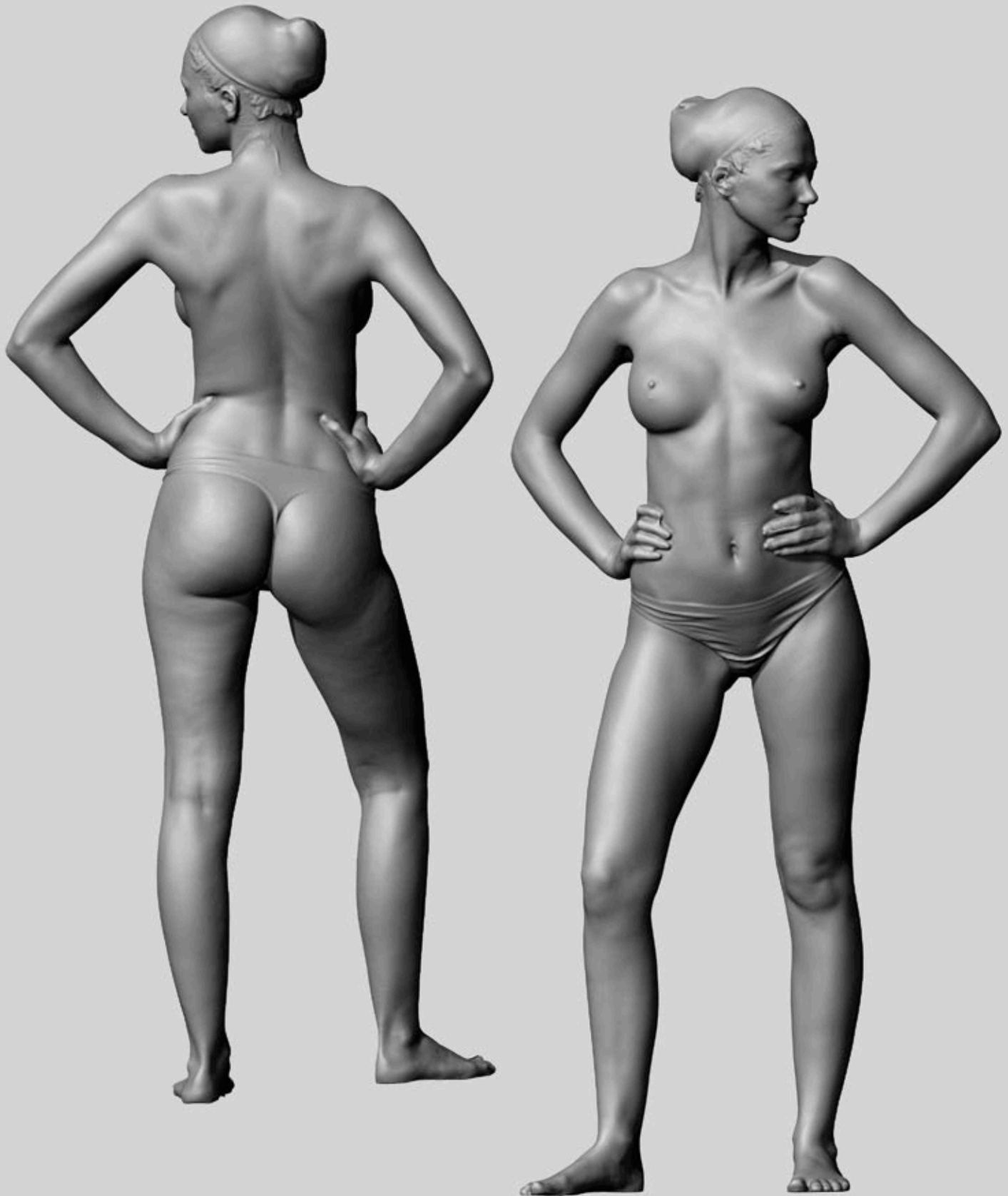
3D SCAN OF MIDDLE-AGED WOMAN



3D SCAN OF YOUNG FEMALE



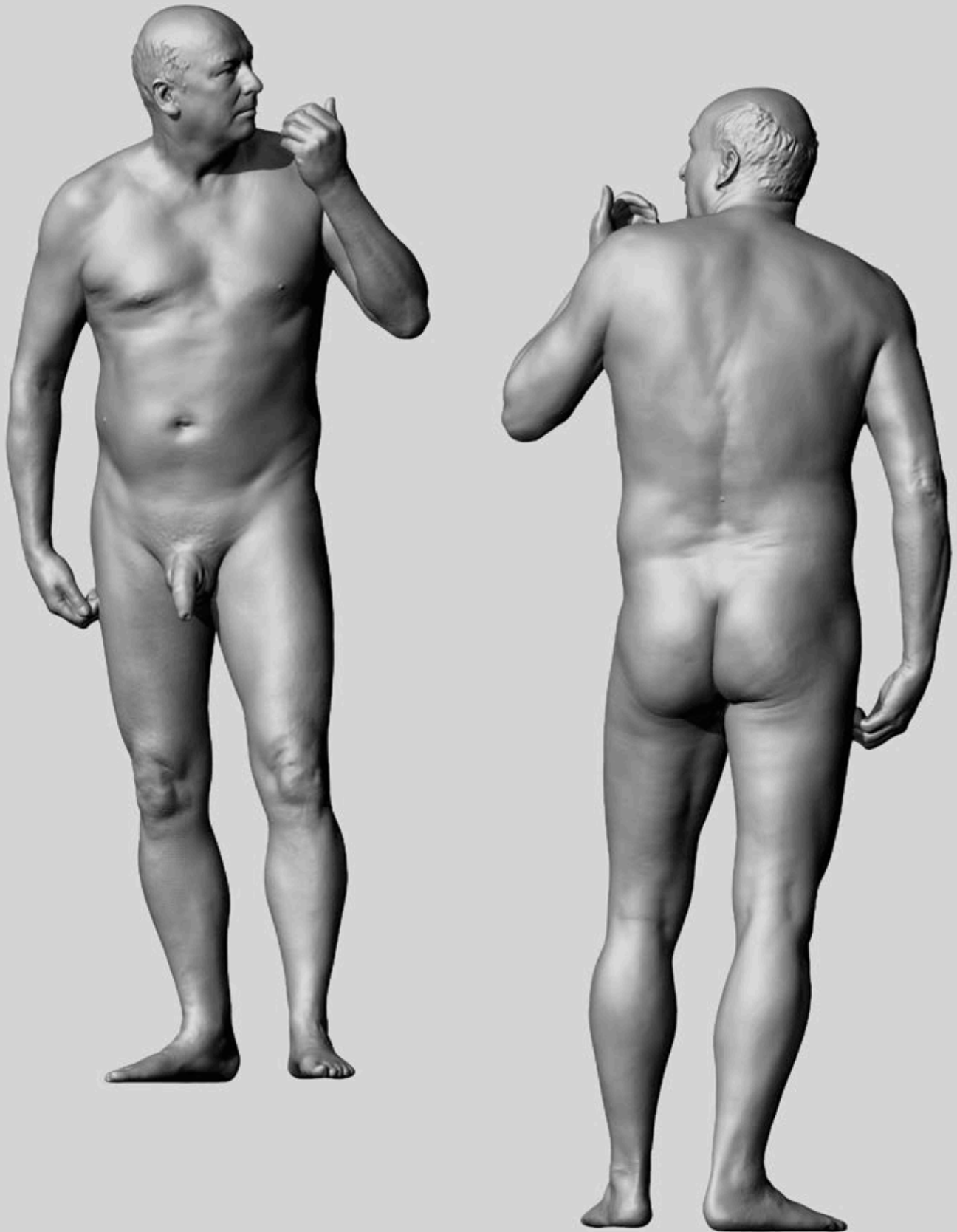
3D SCAN OF YOUNG FEMALE



3D SCAN OF YOUNG MAN



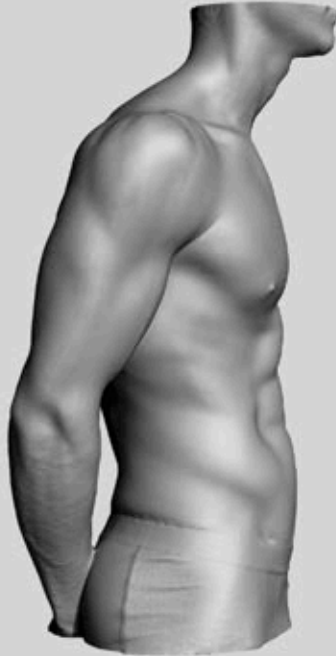3D SCAN OF MIDDLE-AGED MAN



ARMS REACHING BEHIND BODY



3/4



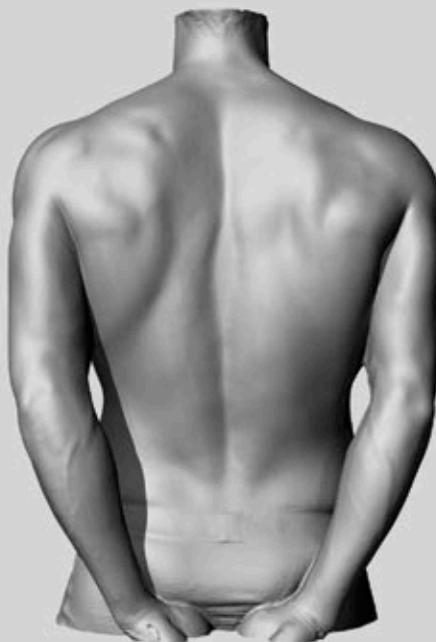RIGHT SIDE



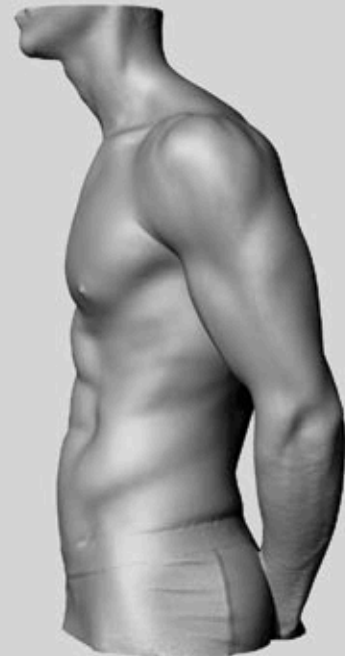3/4



FRONT



BACK

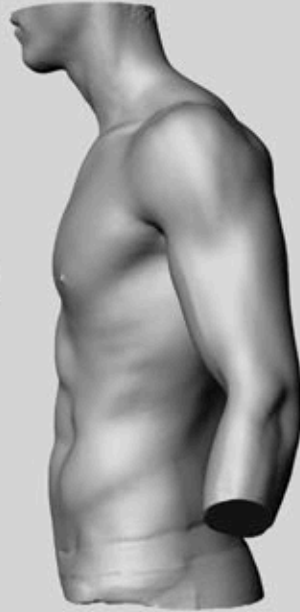

LEFT SIDE

ARMS AT SIDES



3/4



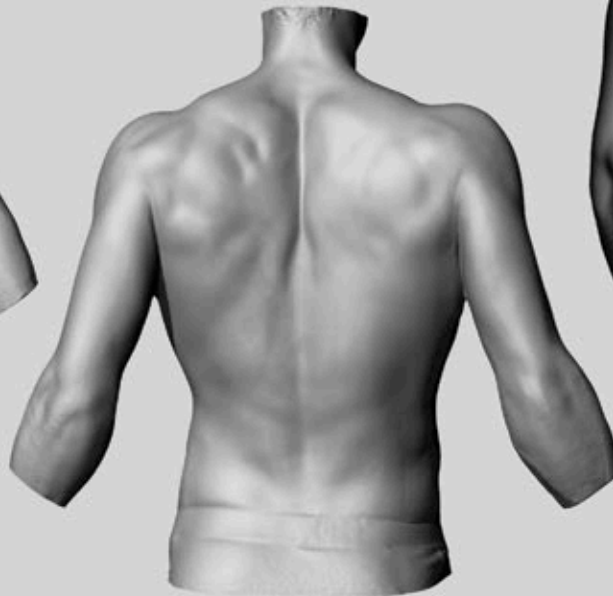
LEFT SIDE



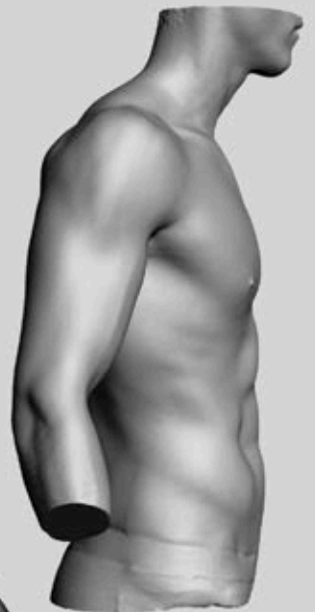3/4



FRONT



BACK

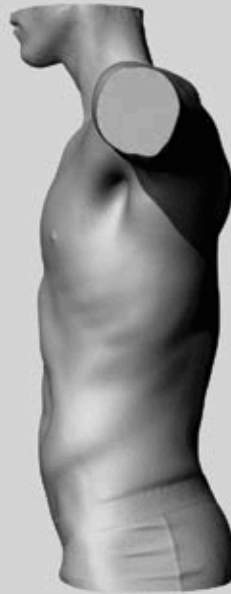

RIGHT SIDE

ARMS HELD STRAIGHT OUT TO SIDES




3/4



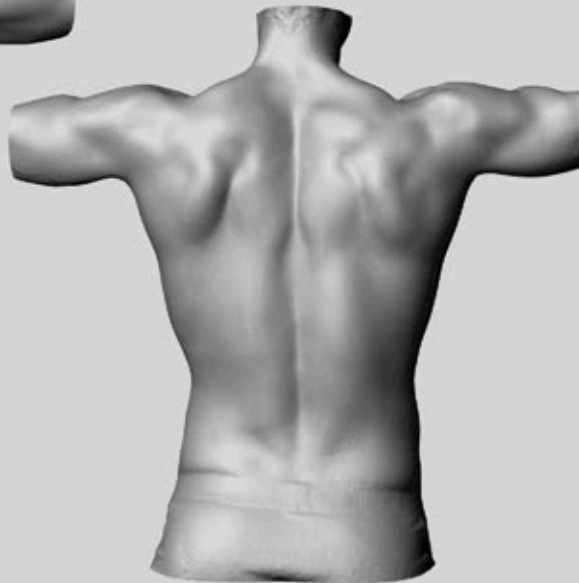LEFT SIDE



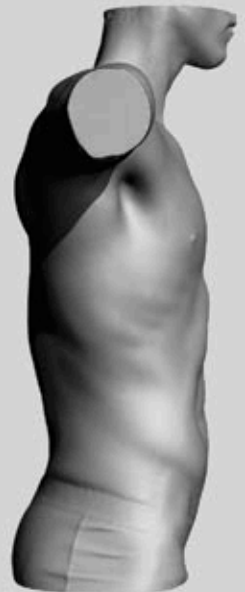3/4



FRONT



BACK

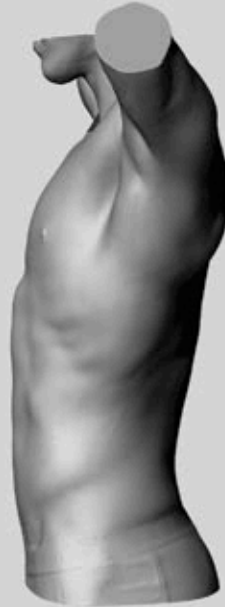

RIGHT SIDE

ARMS IN A "Y" POSITION



3/4



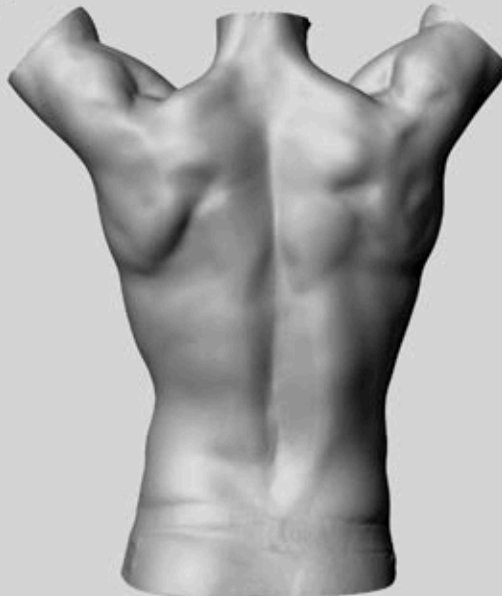LEFT SIDE



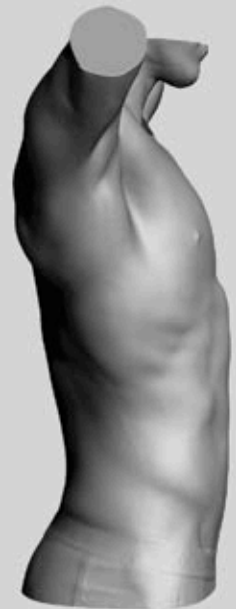3/4



FRONT

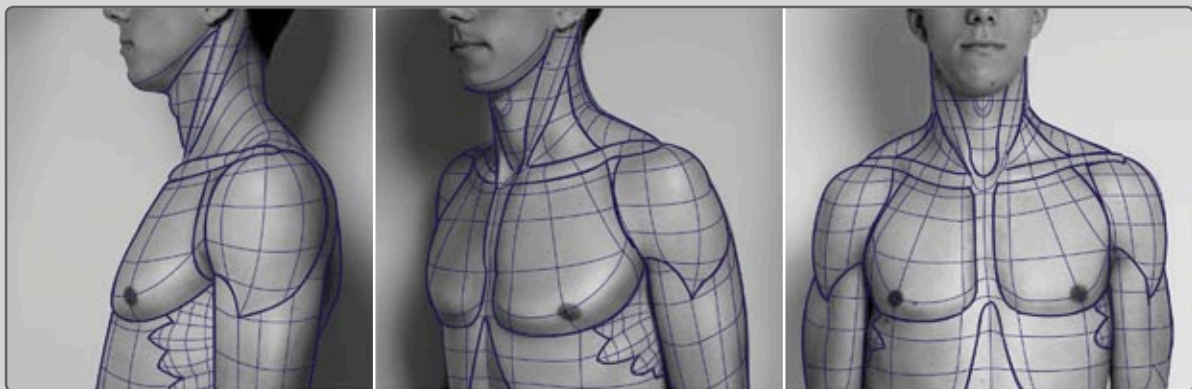
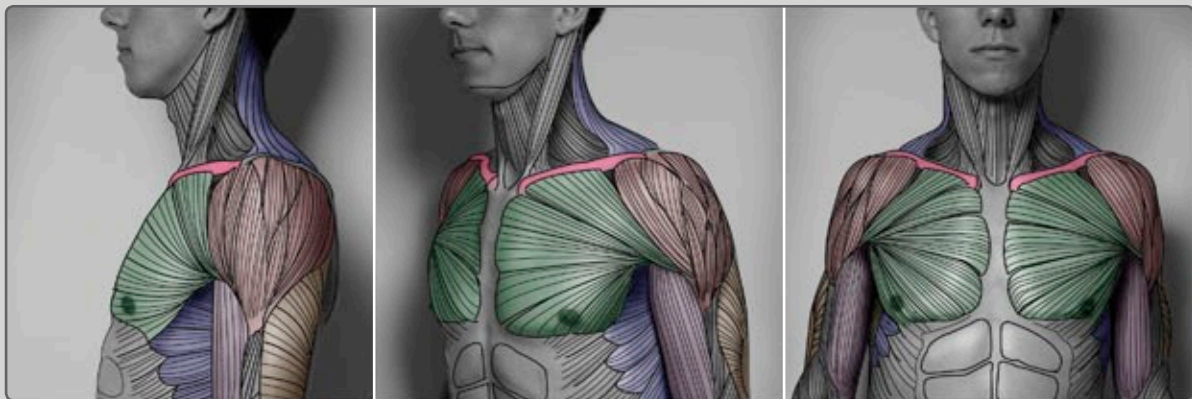
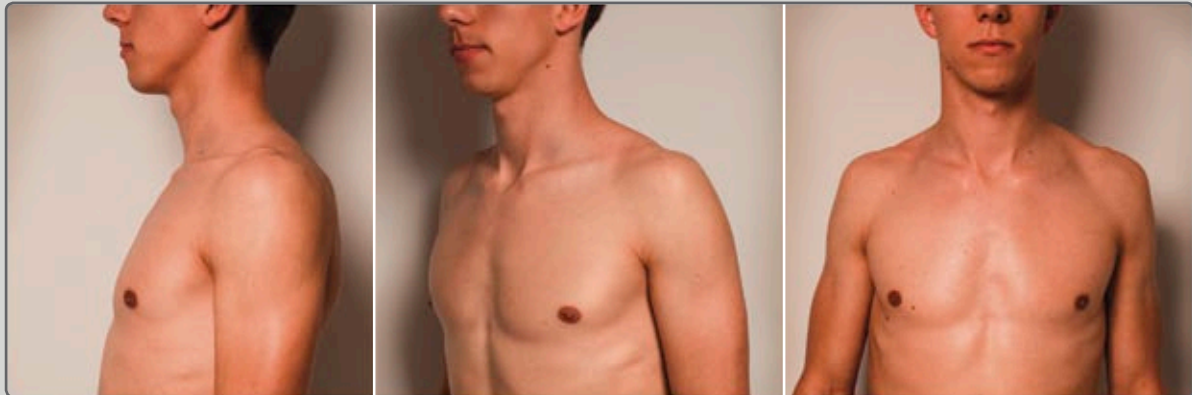


BACK


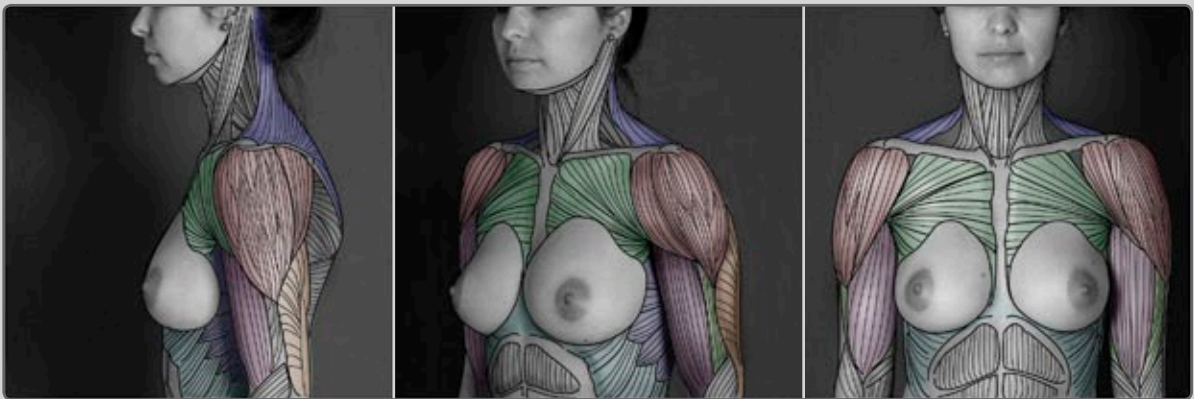
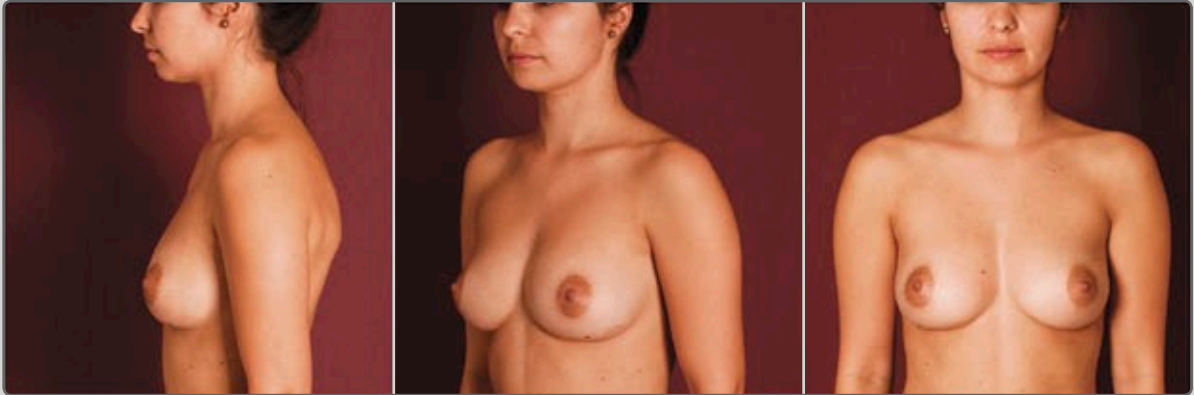


RIGHT SIDE

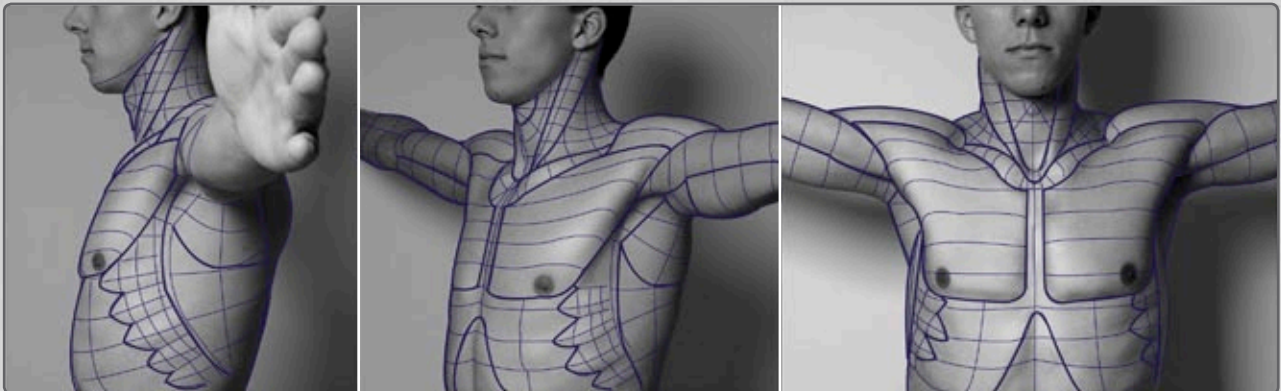
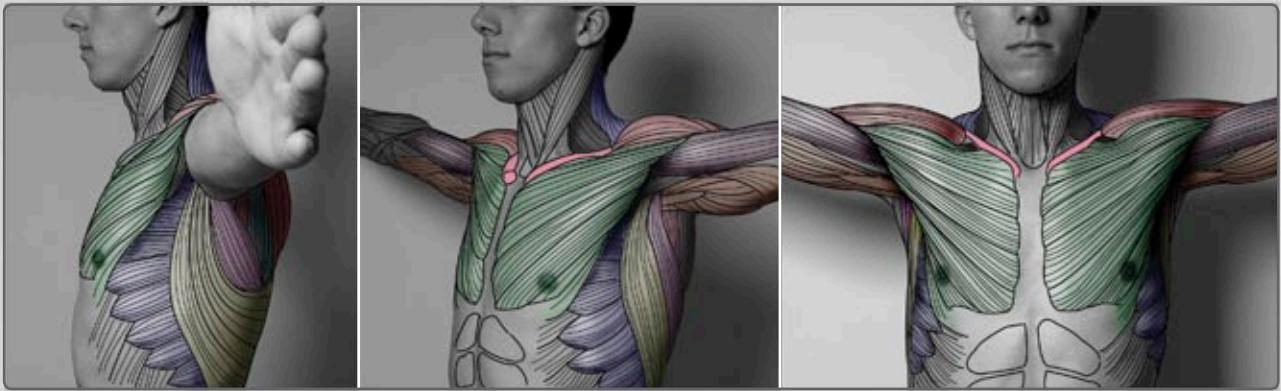
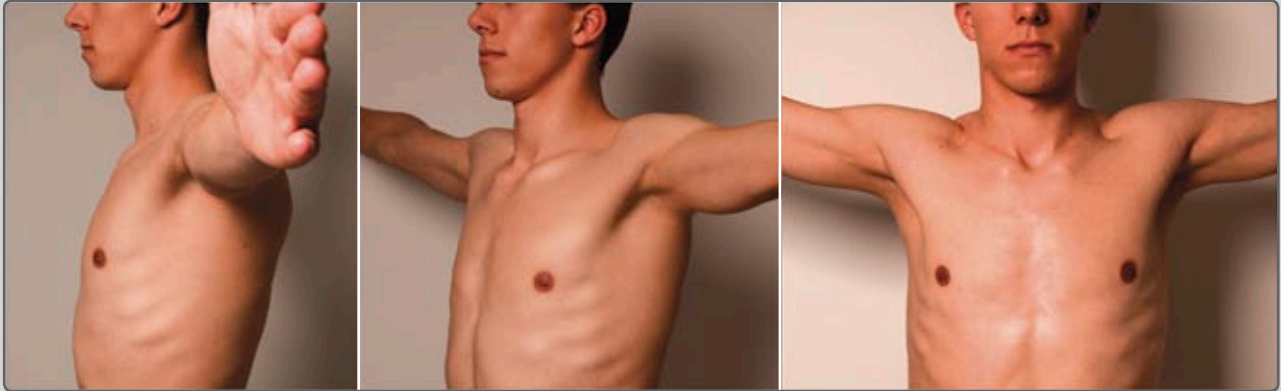
ARMS HANGING NATURALLY – MALE



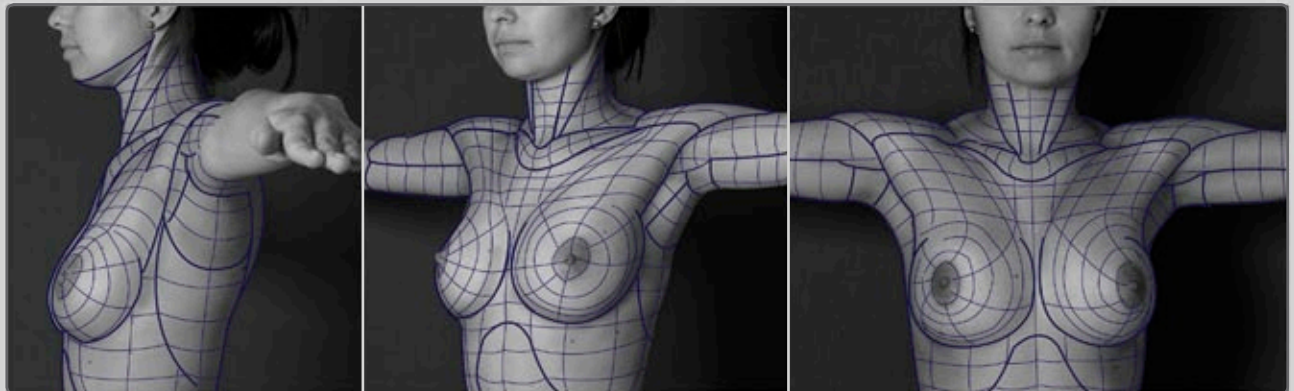
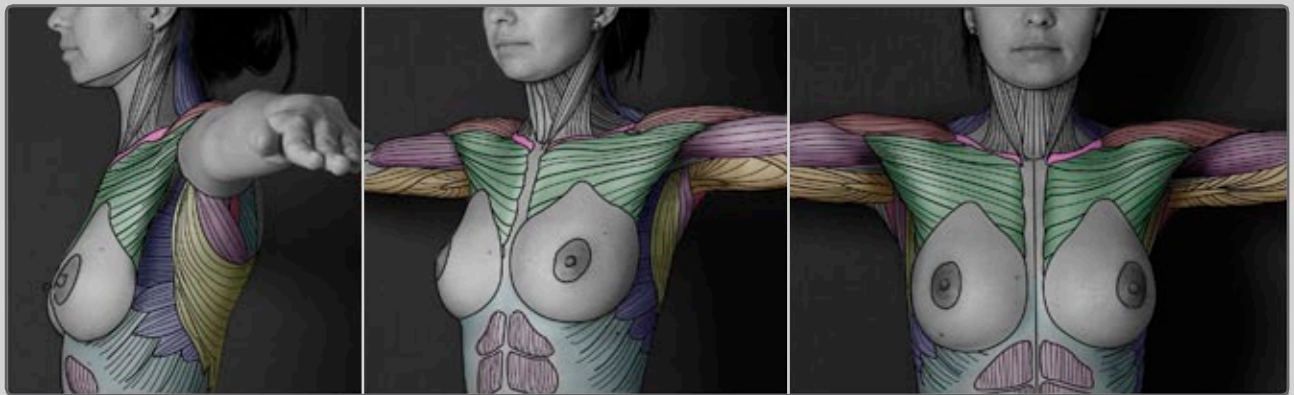
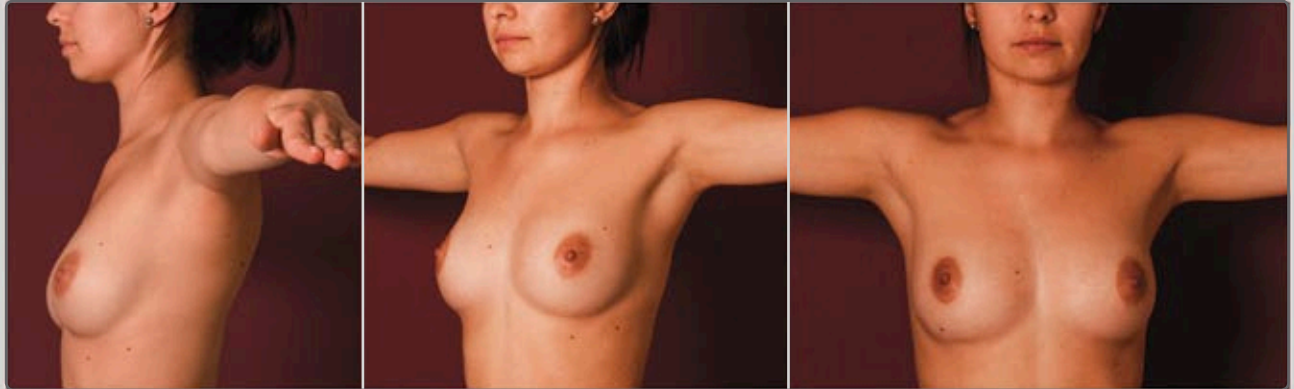
ARMS HANGING NATURALLY – FEMALE




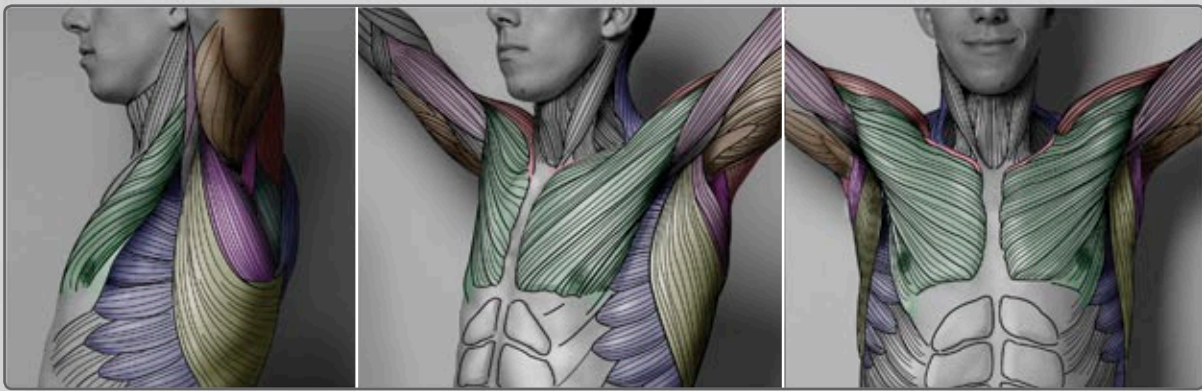
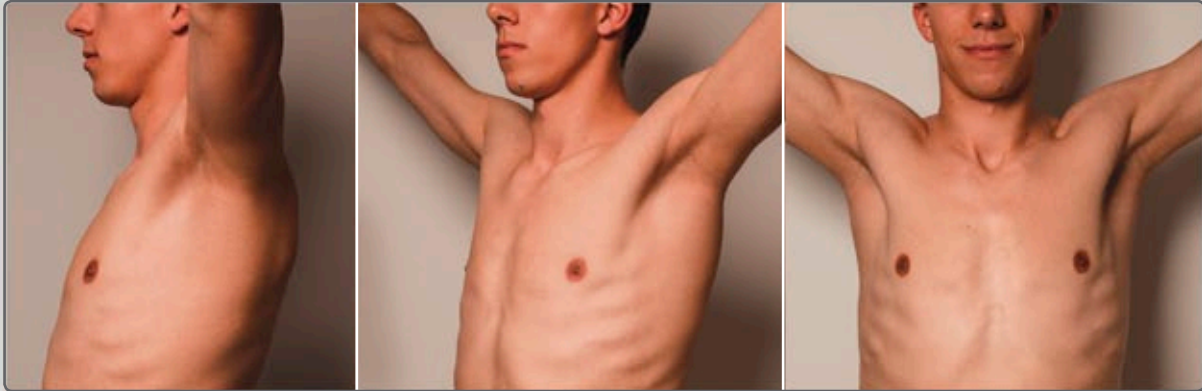
ARMS HELD STRAIGHT OUT TO SIDES – MALE



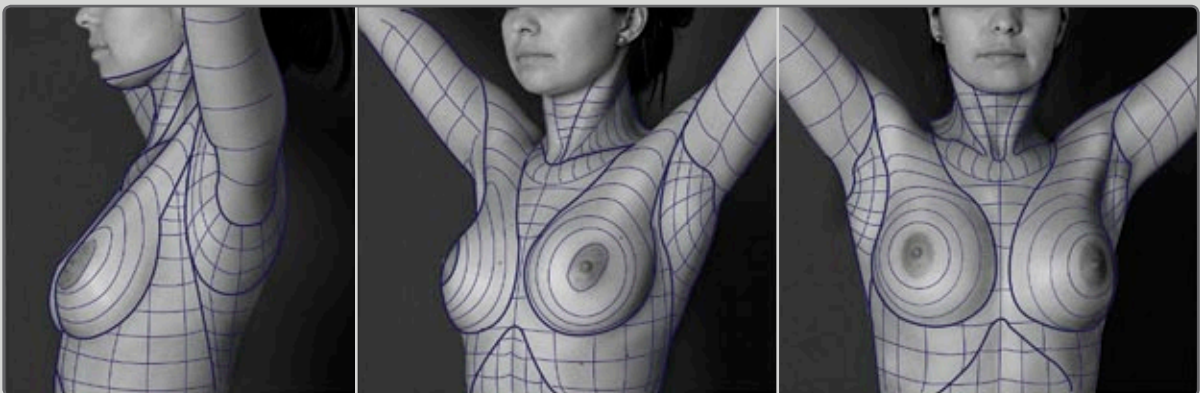
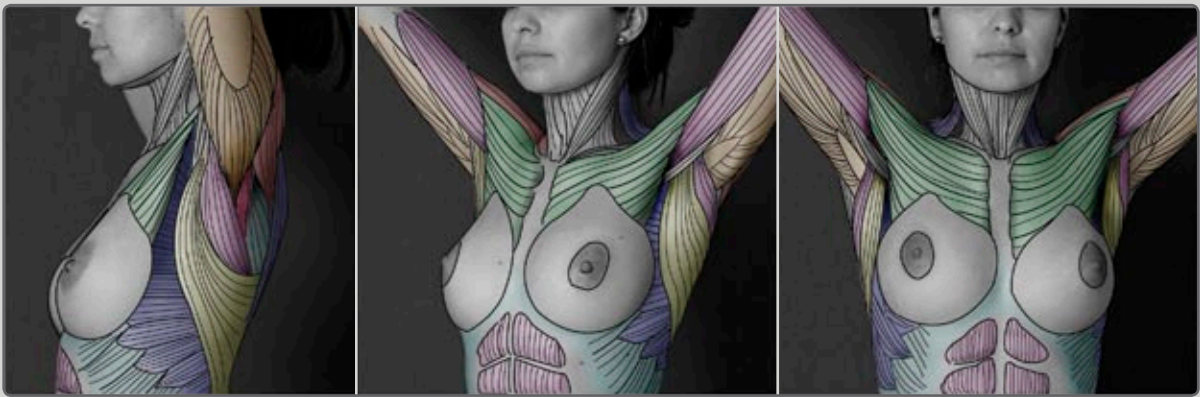
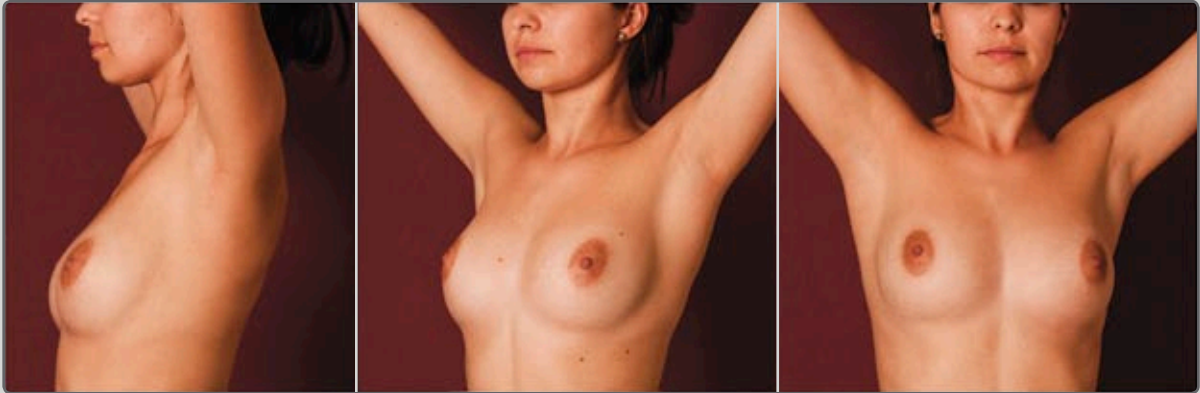
ARMS HELD STRAIGHT OUT TO SIDES – FEMALE



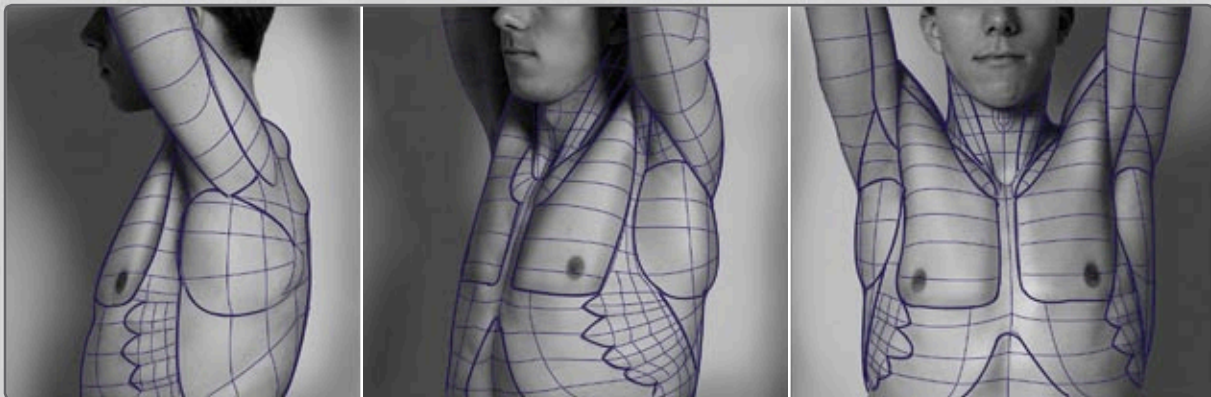

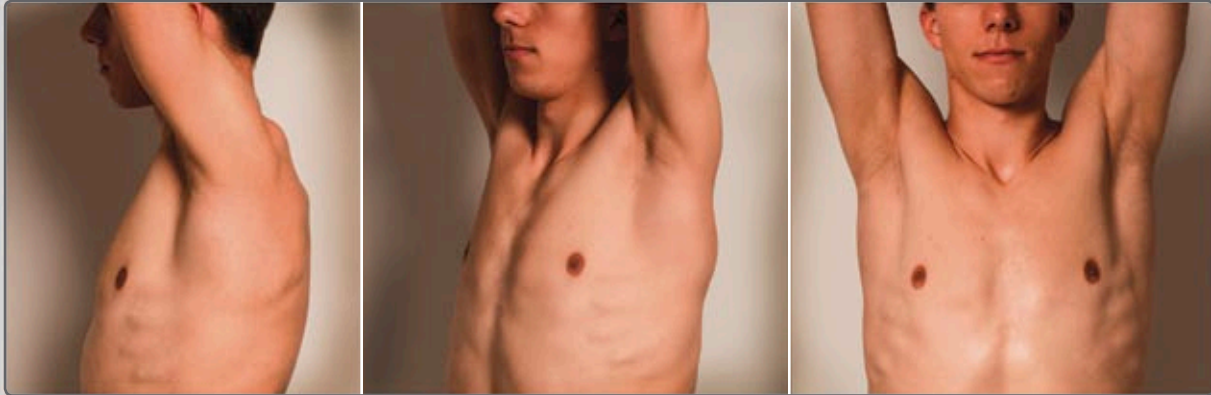
ARMS IN A "Y" POSITION – MALE






ARMS IN A "Y" POSITION – FEMALE



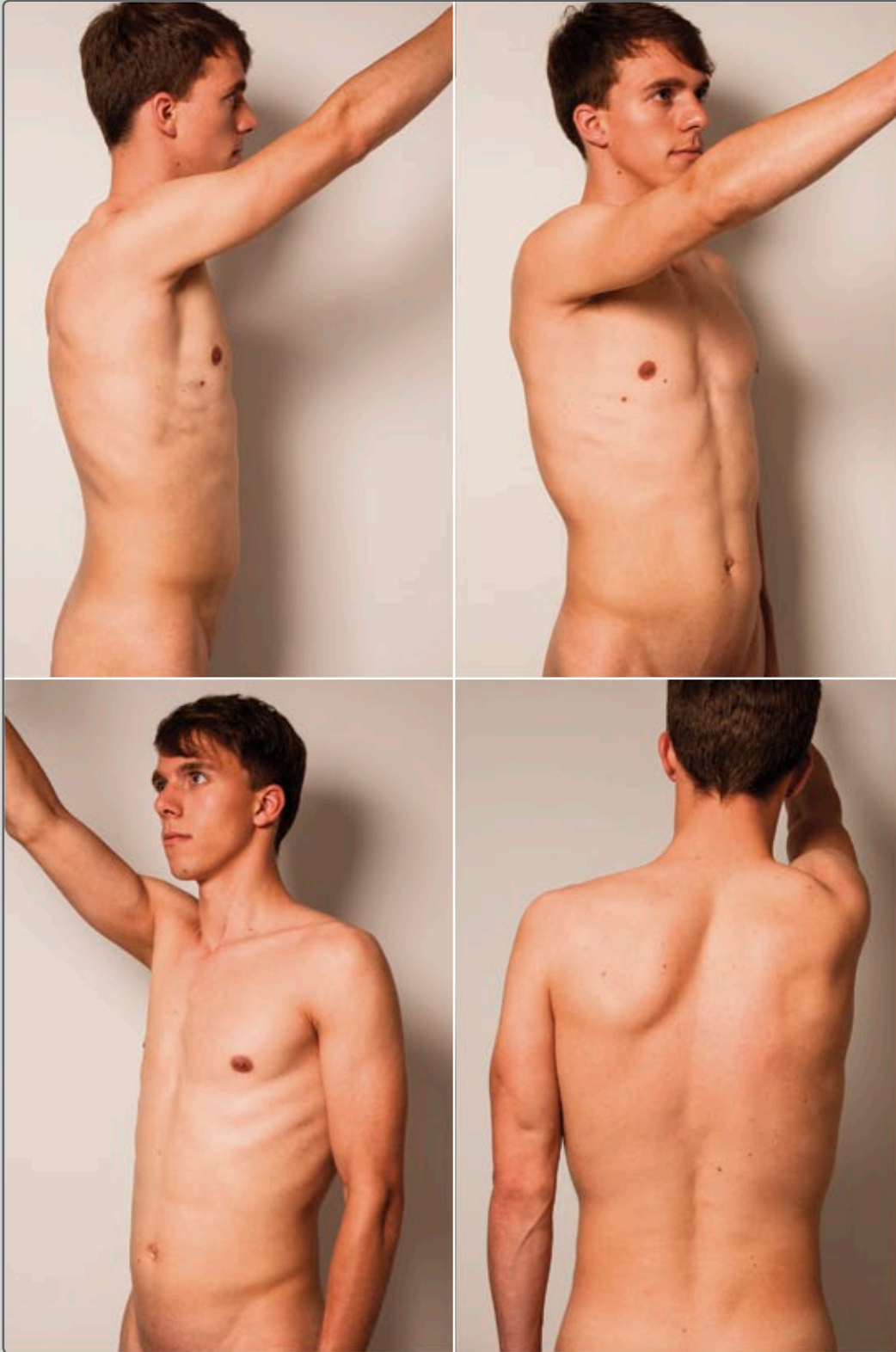
ARMS STRAIGHT UP – MALE



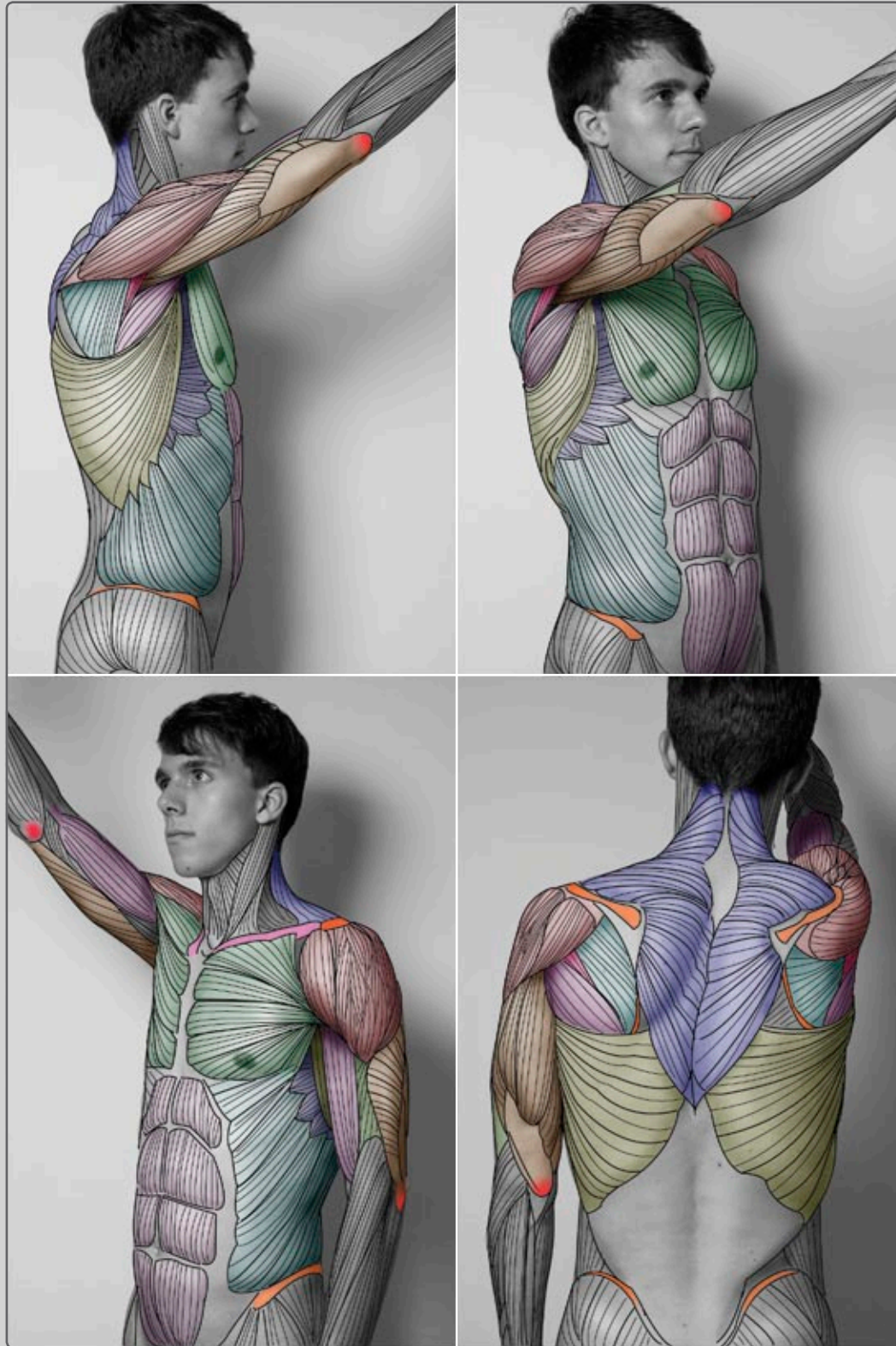
ARMS STRAIGHT UP – FEMALE



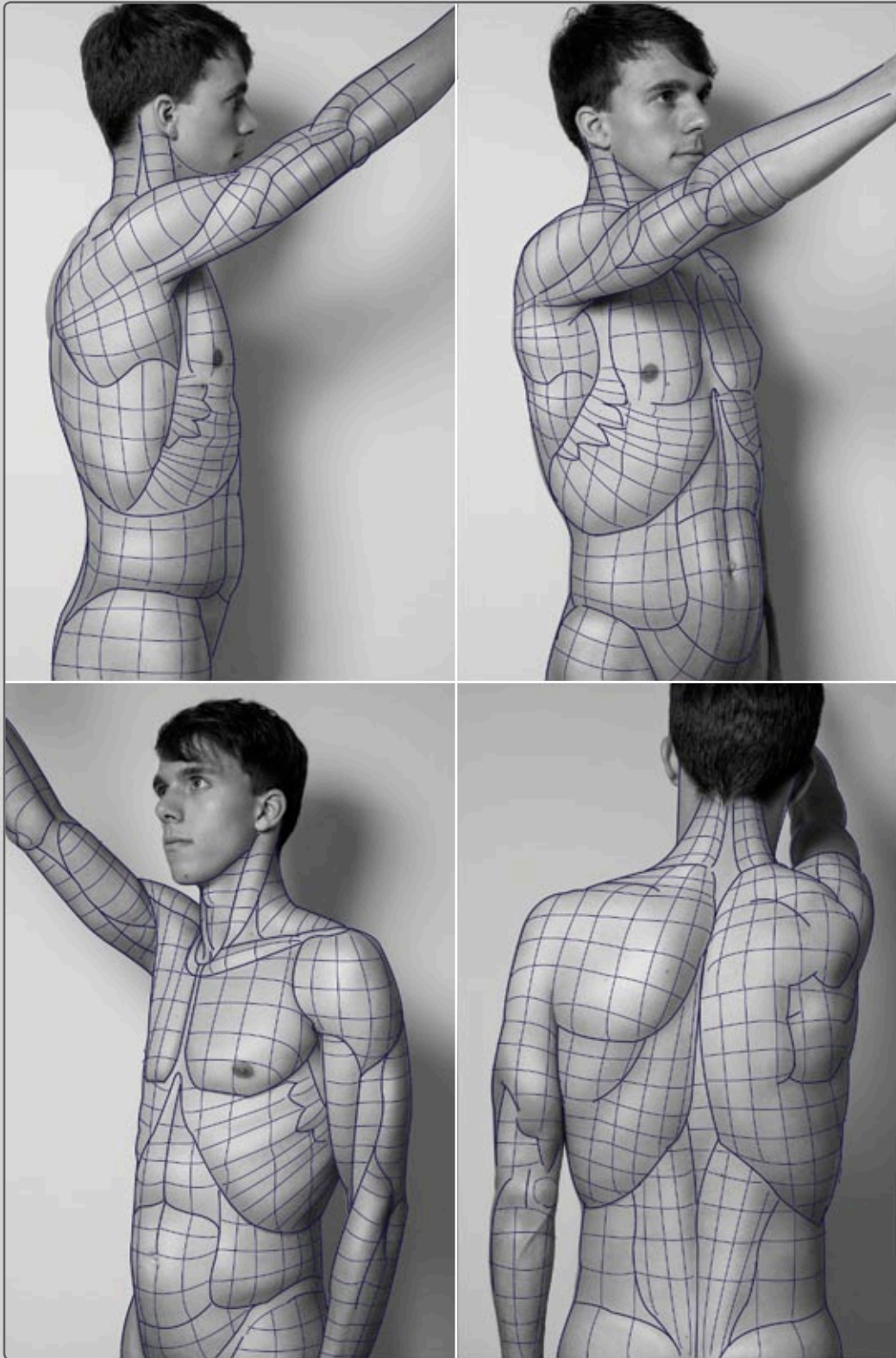
ARM REACHING UP AND FORWARD



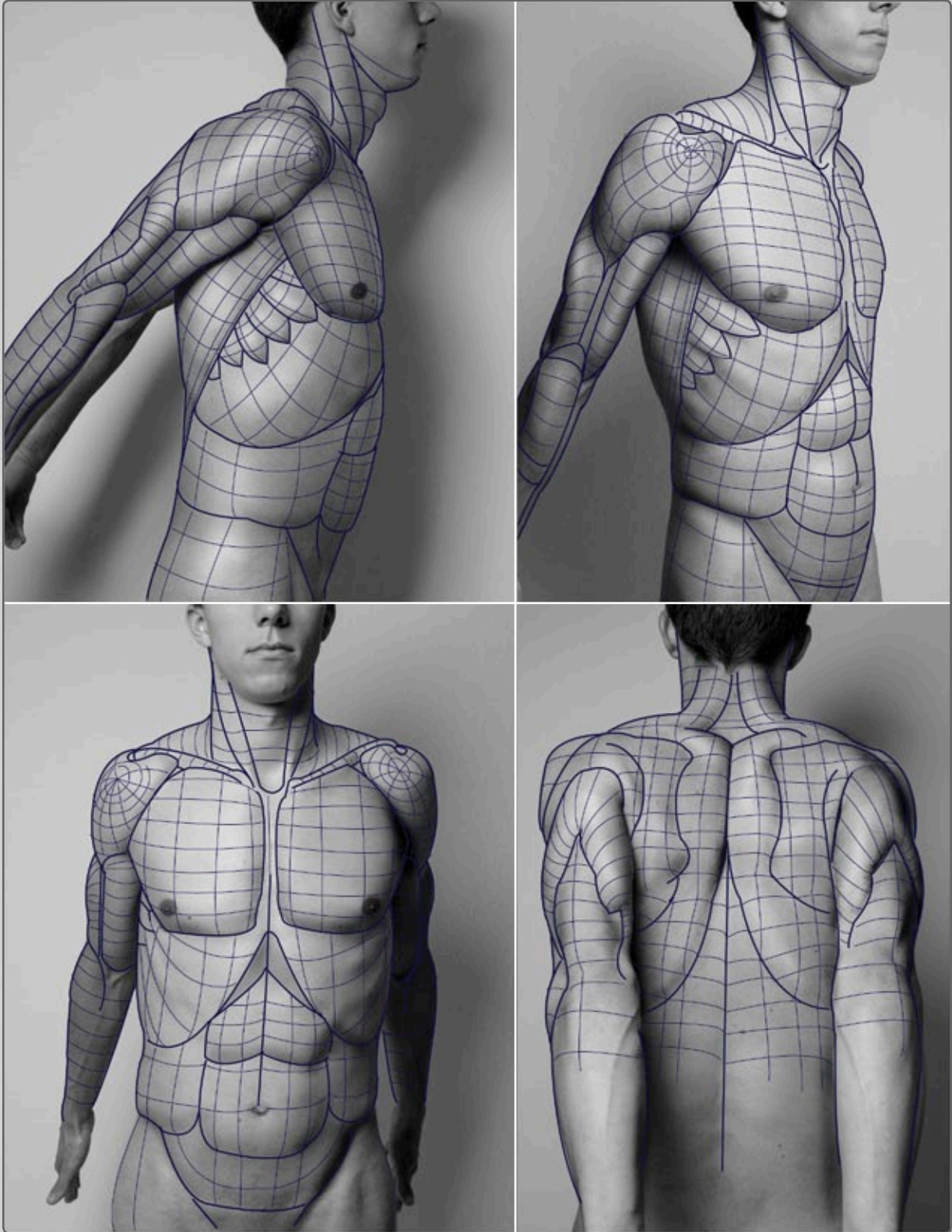
ARM REACHING UP AND FORWARD



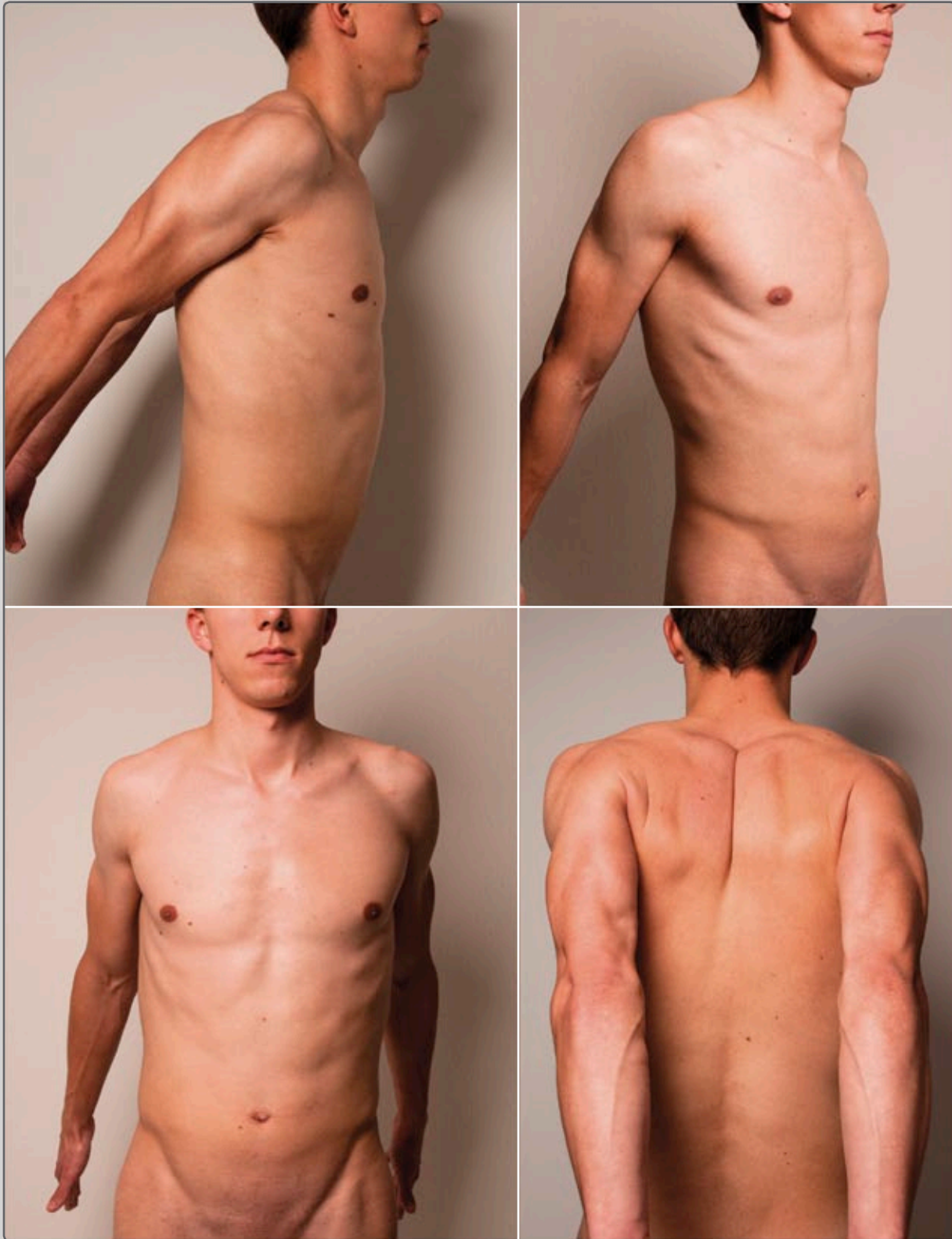ARM REACHING UP AND FORWARD



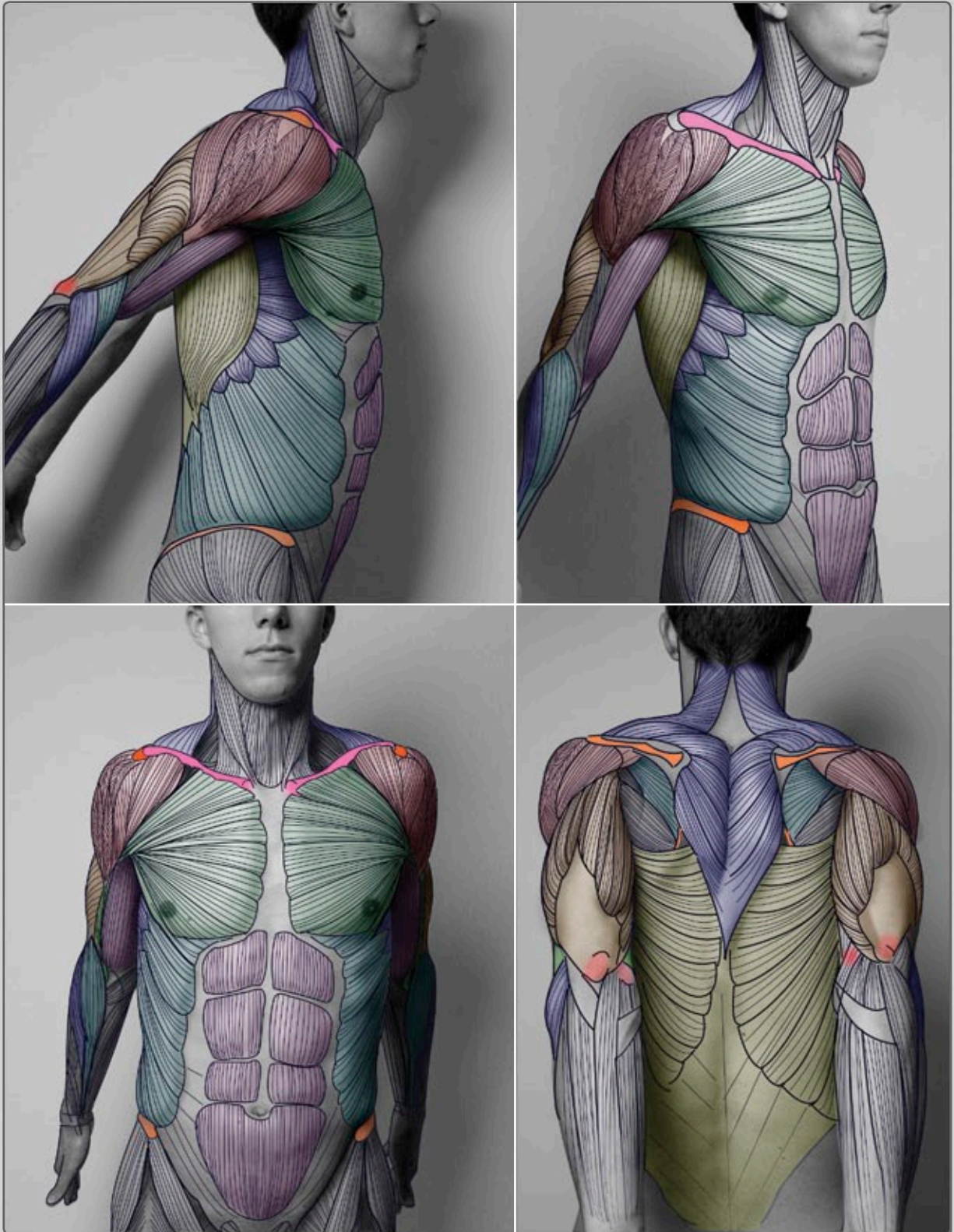
REACHING BACK



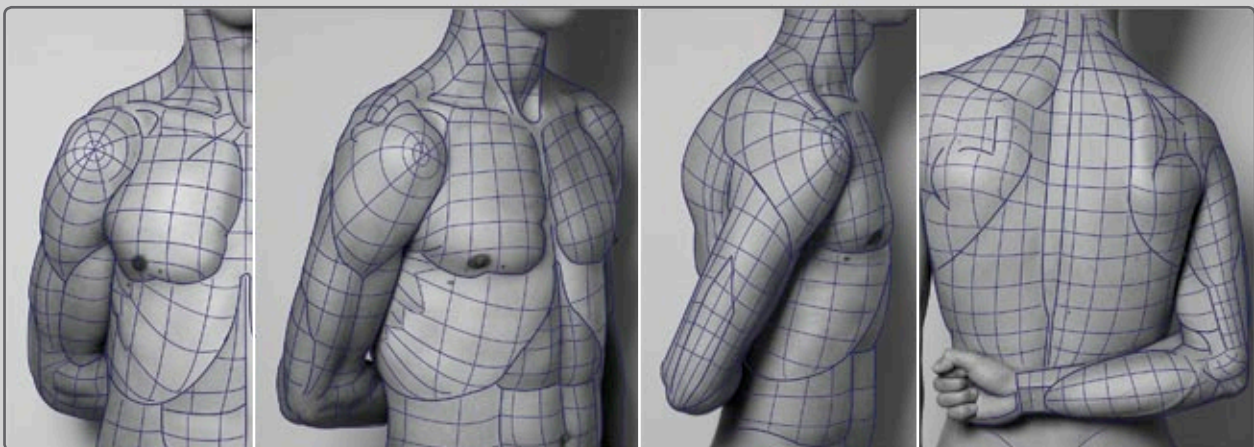
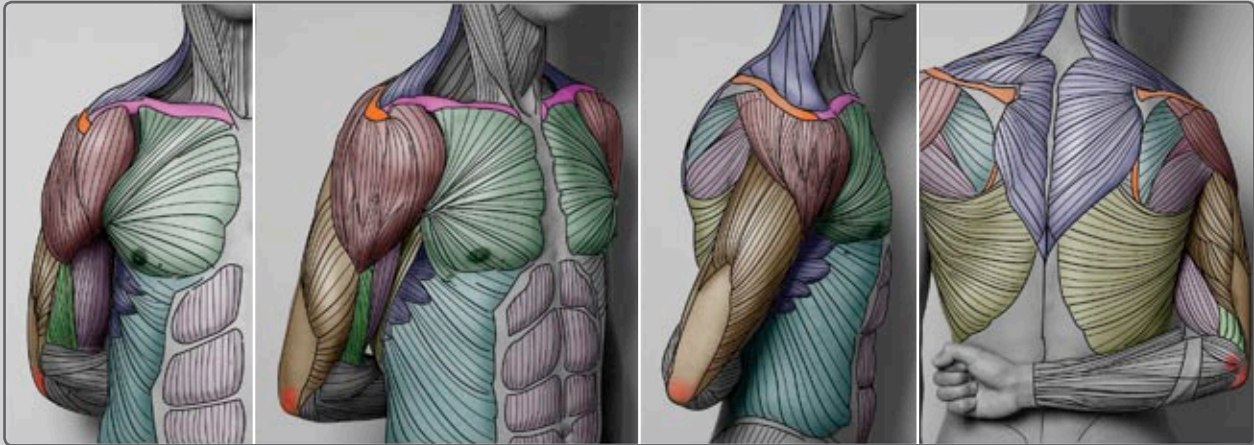
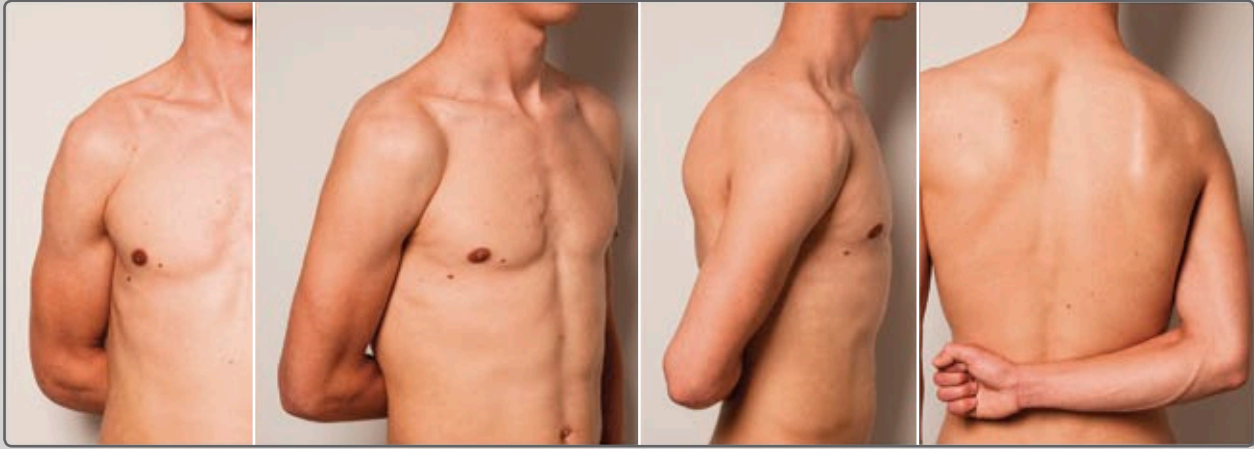
REACHING BACK



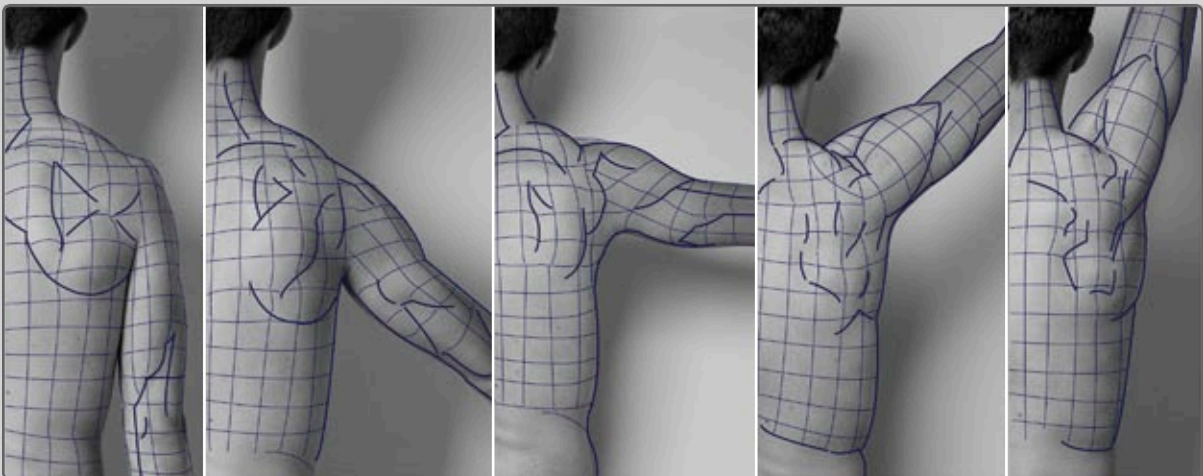
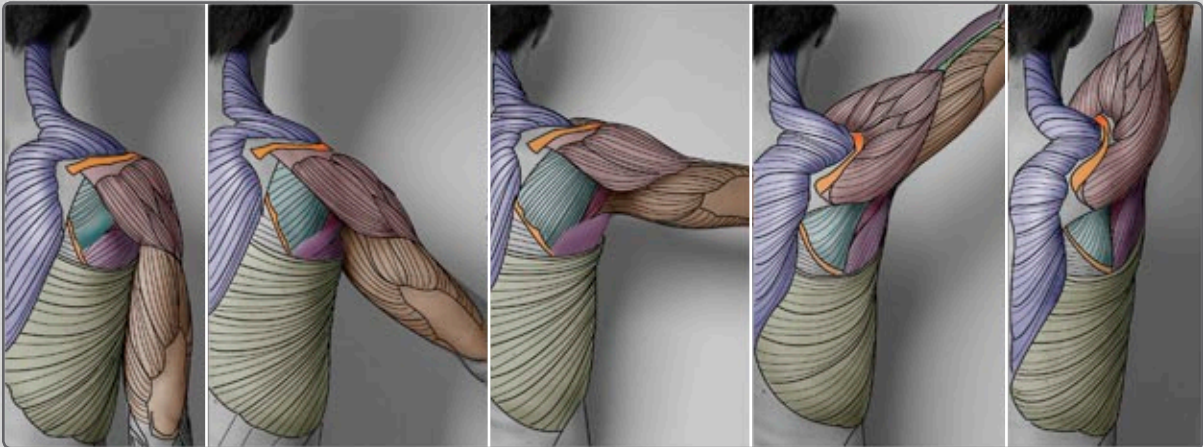
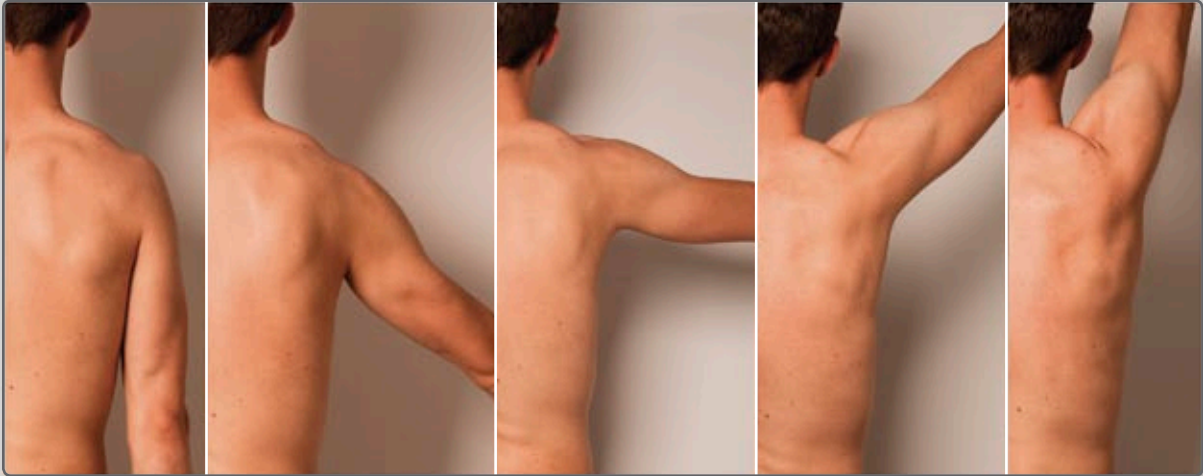
REACHING BACK




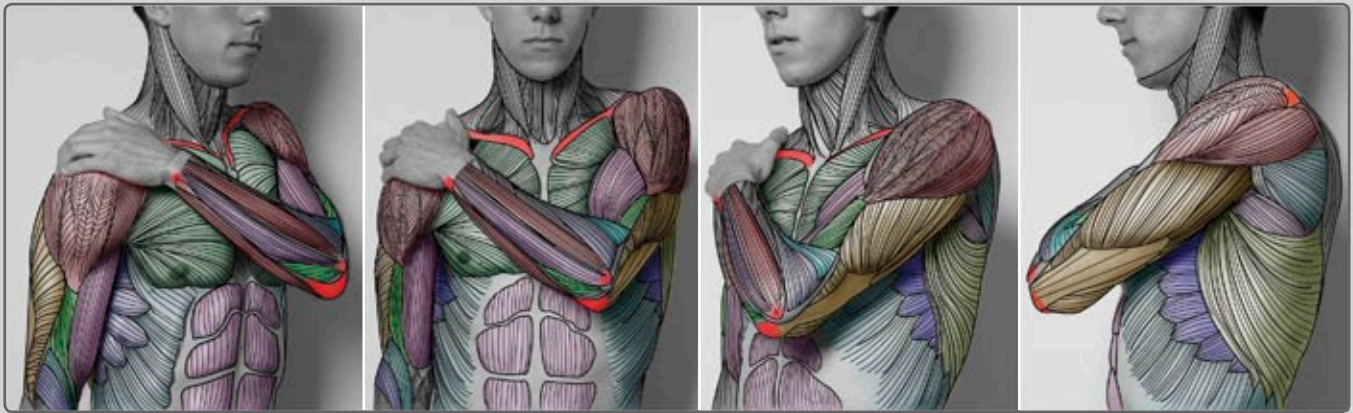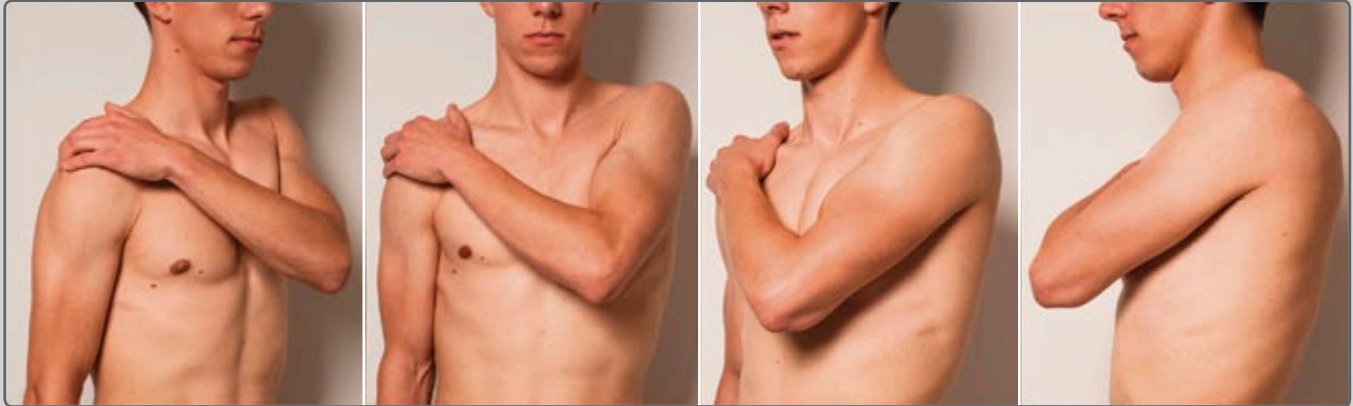
ONE ARM BEHIND BACK




LIFTING ARM HIGHER AND HIGHER



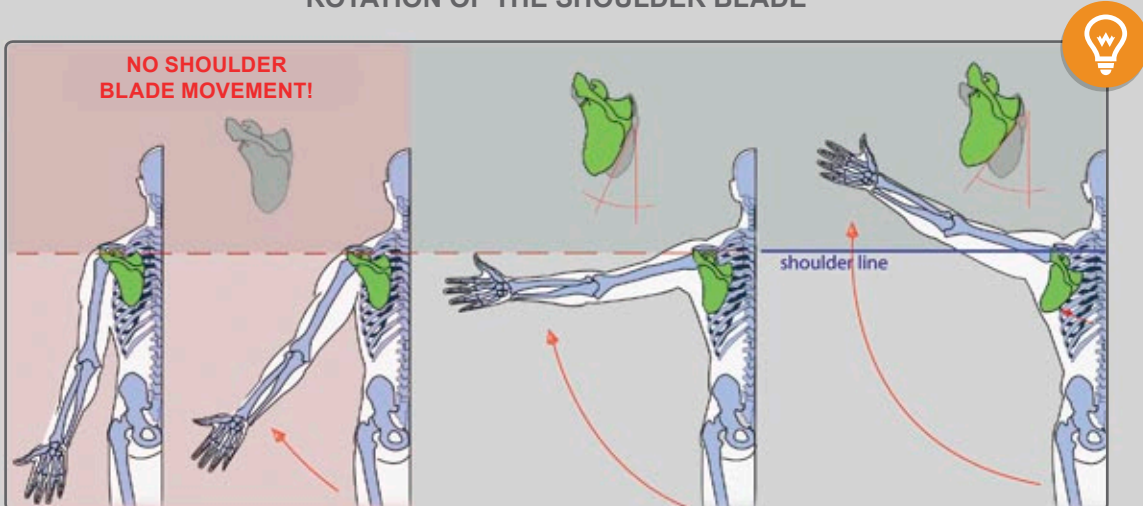
HAND HOLDING OPPOSITE SHOULDER



LET'S FIND SHOULDER BLADES (SCAPULA)!

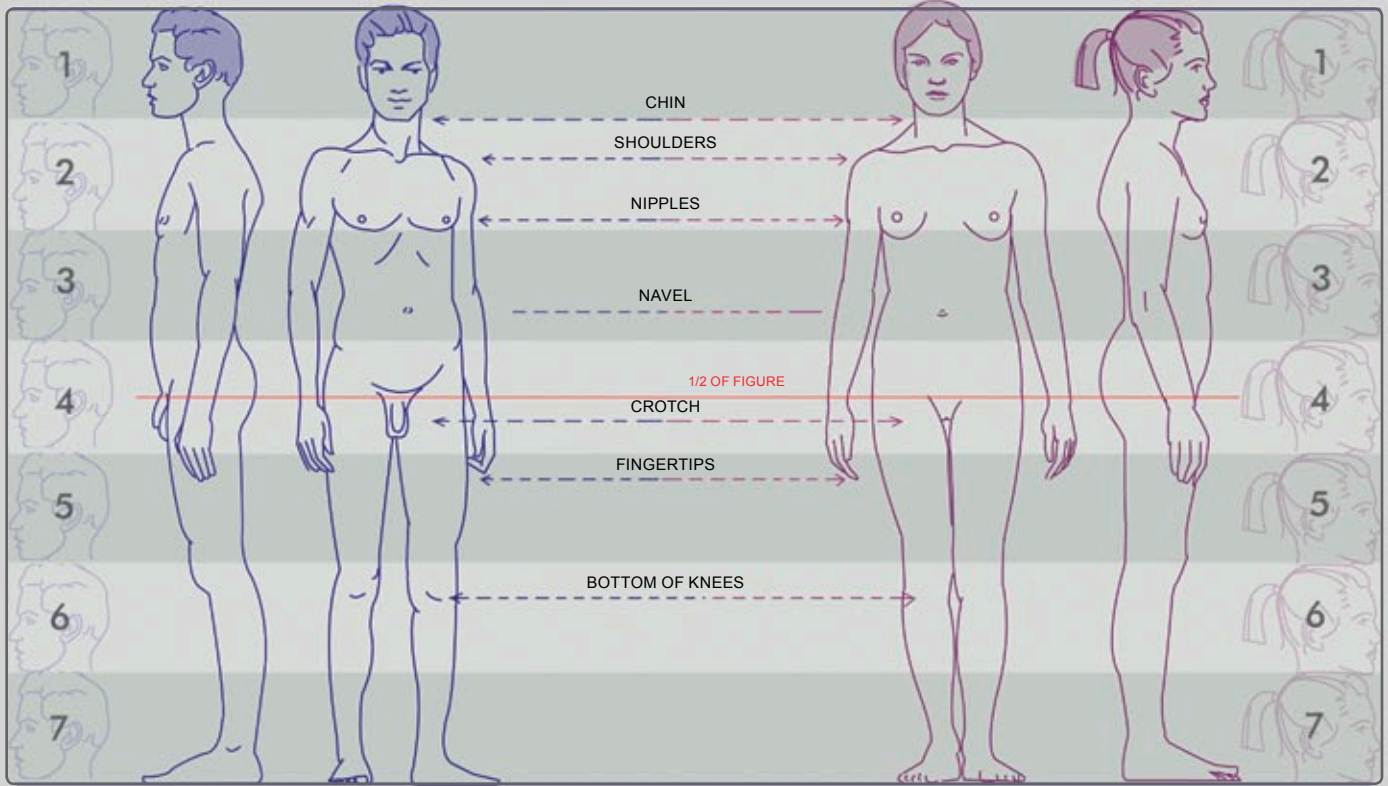


ROTATION OF THE SHOULDER BLADE

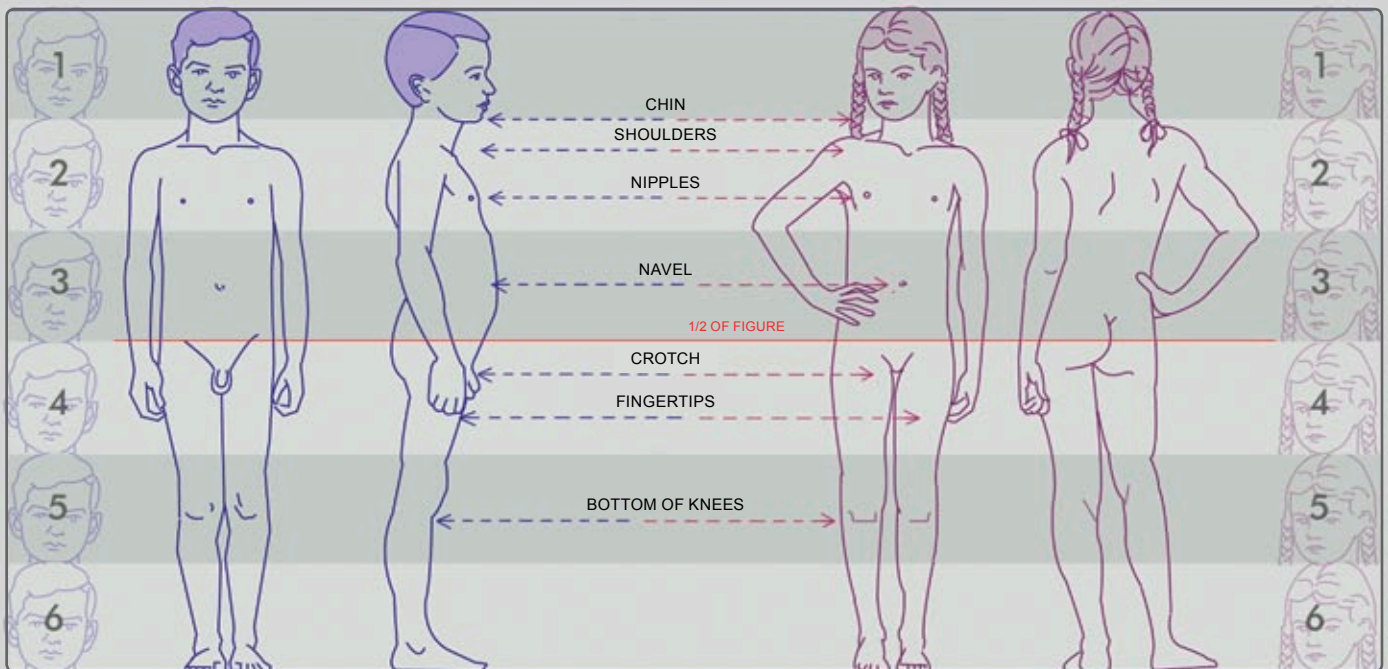


PROPORTIONS OF TEENAGER AND CHILD

TEENAGER PROPORTIONS - 7 HEAD UNITS

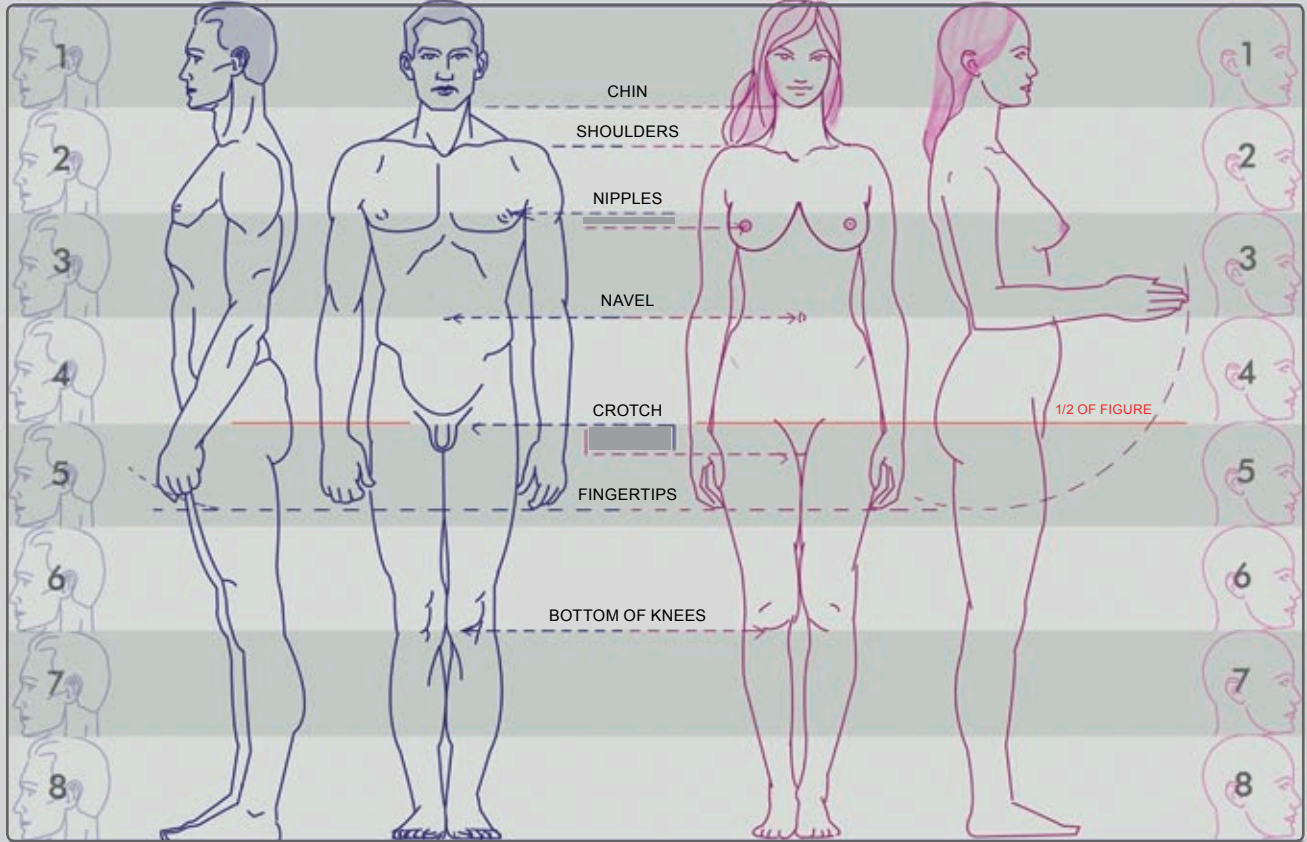


CHILD PROPORTIONS (AGES 8 - 12) - 6 HEAD UNITS

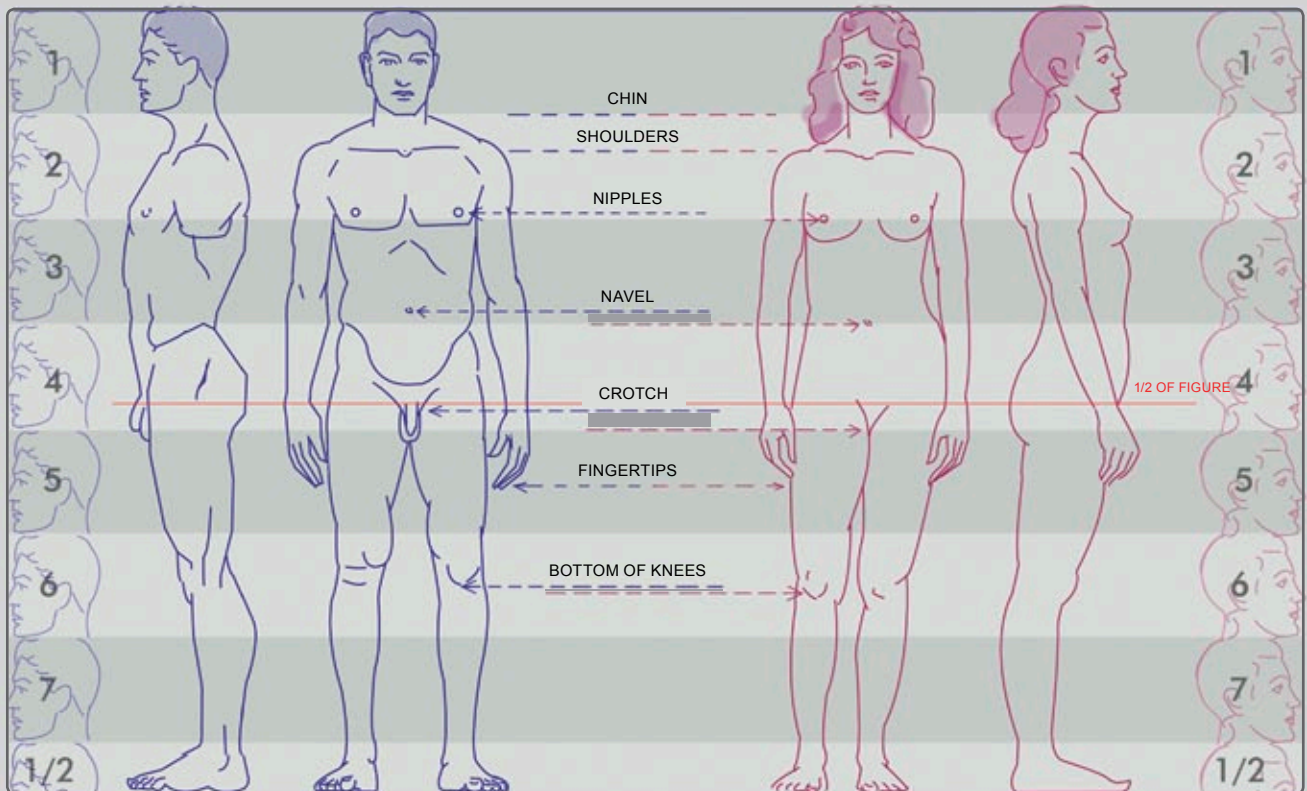


PROPORTIONS OF ADULT MALE AND FEMALE

IDEALIZED ADULT PROPORTIONS - 8 HEAD UNITS

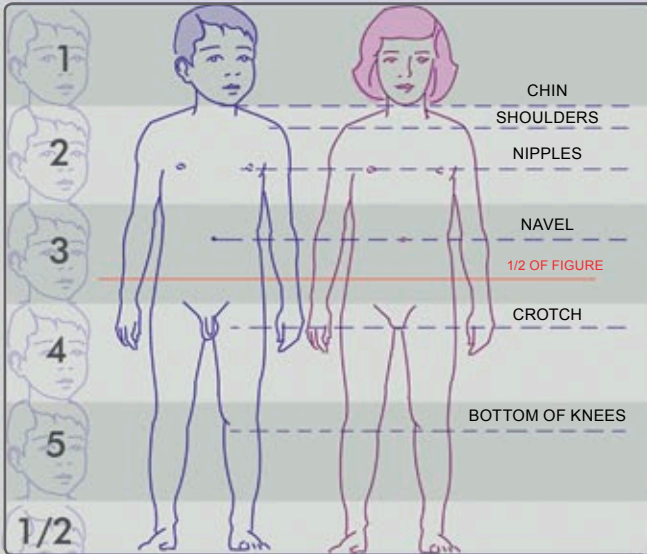


REALISTIC ADULT PROPORTIONS - 7.5 HEAD UNITS

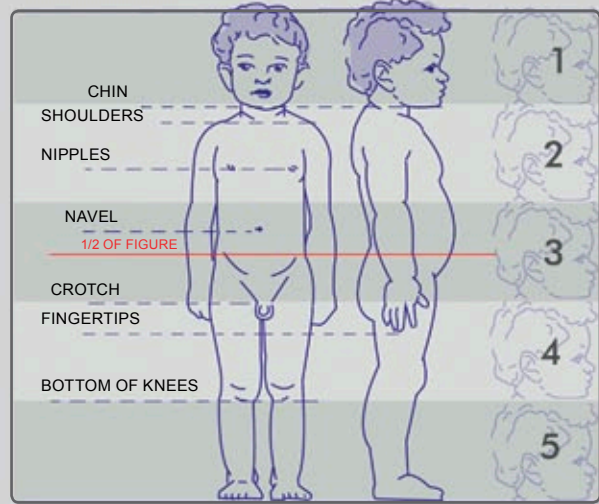


PROPORTIONS OF CHILD, TODDLER, NEWBORN AND SENIOR

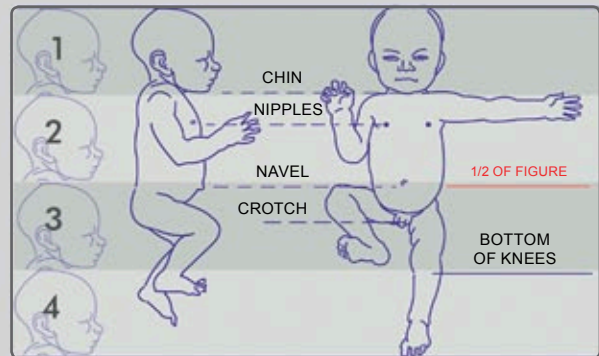
CHILD: **5.5 HEAD UNITS**



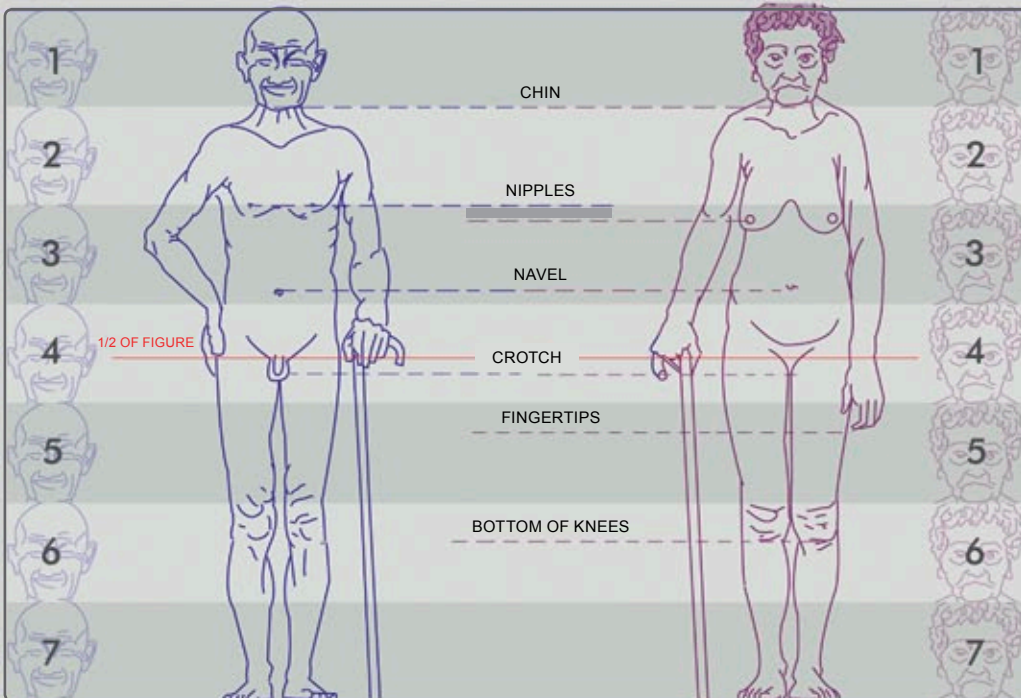
TODDLER: **5 HEAD UNITS**




NEWBORN: **4 HEAD UNITS**

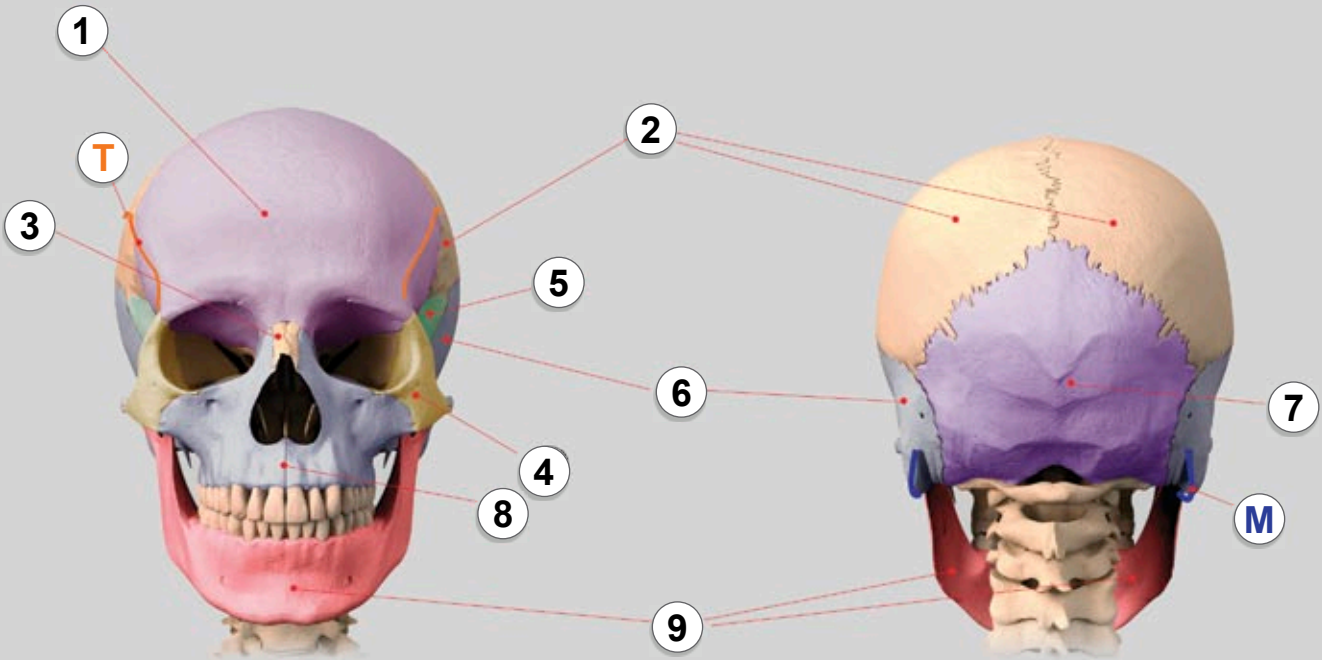
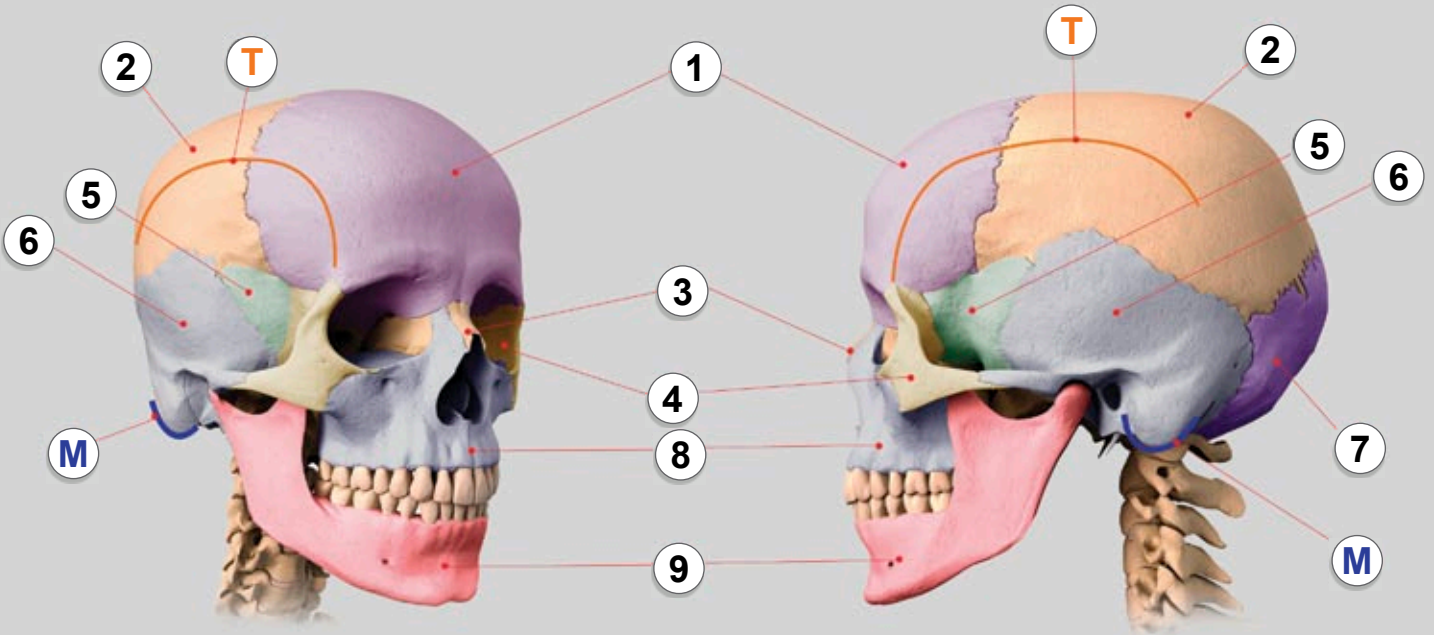


SENIOR: **7 HEAD UNITS**



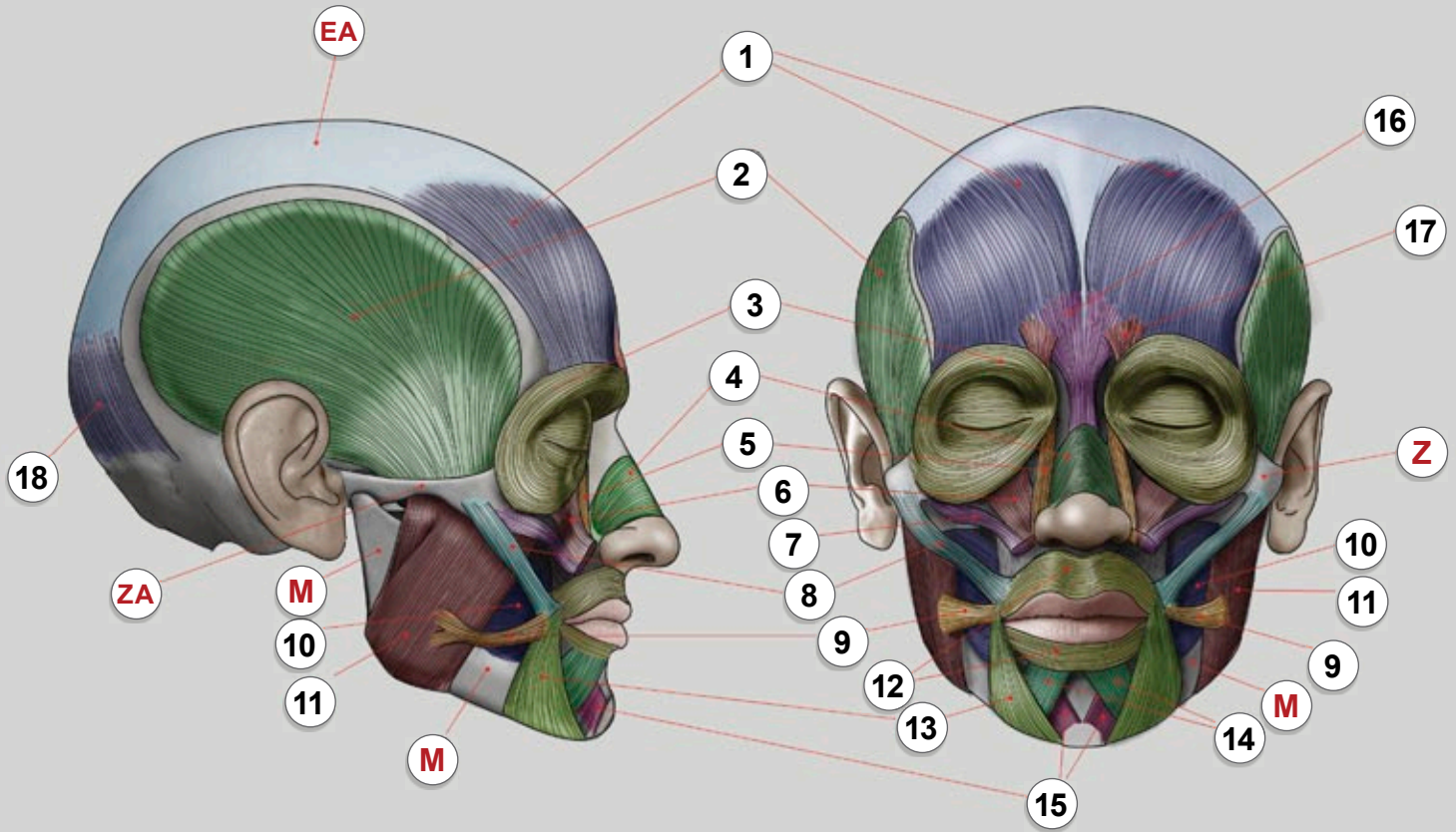


MAJOR SKULL BONES



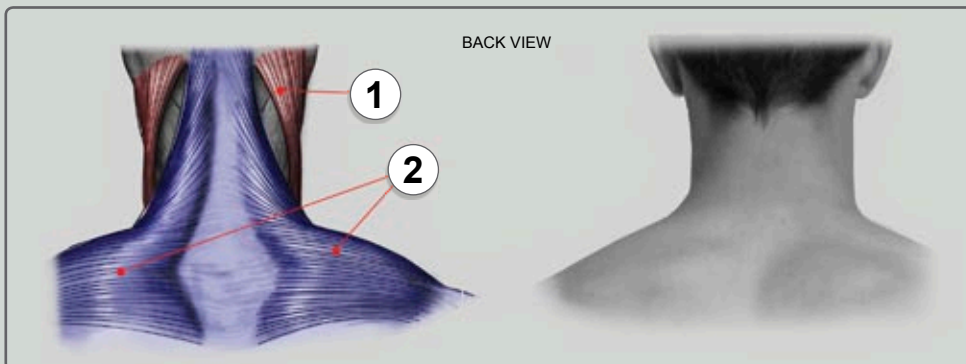
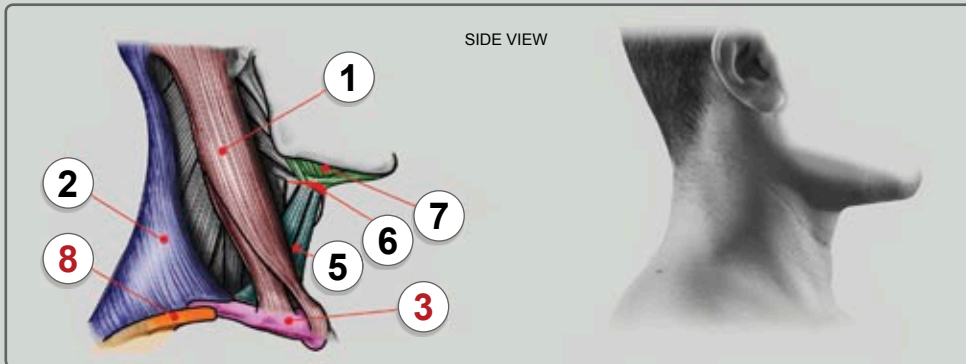
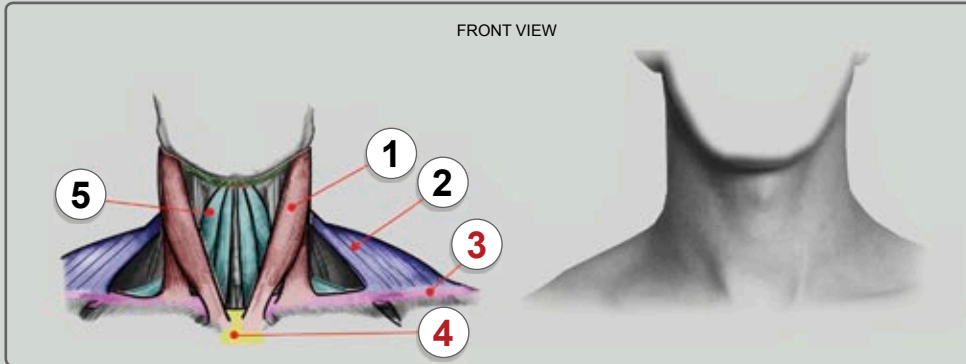
- | | | | | | |
|----------|---------------|----------|-----------------|----------|----------------|
| 1 | FRONTAL BONE | 4 | ZYGOMATIC BONE | 7 | OCCIPITAL BONE |
| 2 | PARIETAL BONE | 5 | SPHENOID BONE | 8 | MAXILLA BONE |
| 3 | NASAL BONE | 6 | TEMPORAL BONE | 9 | MANDIBLE BONE |
| T | TEMPORAL LINE | M | MASTOID PROCESS | | |

MAJOR HEAD MUSCLES



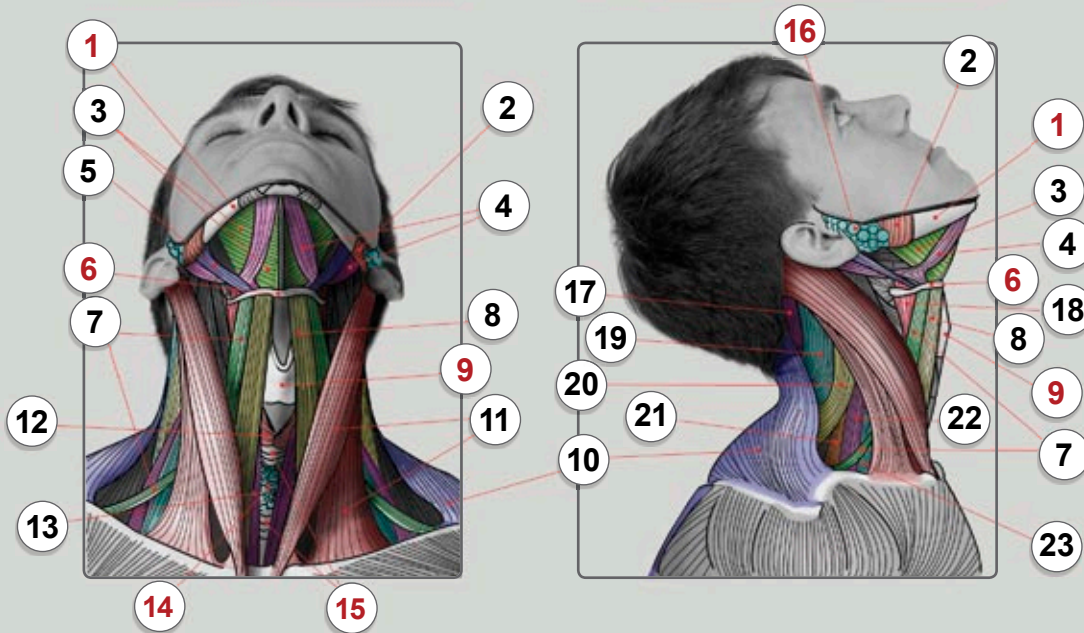
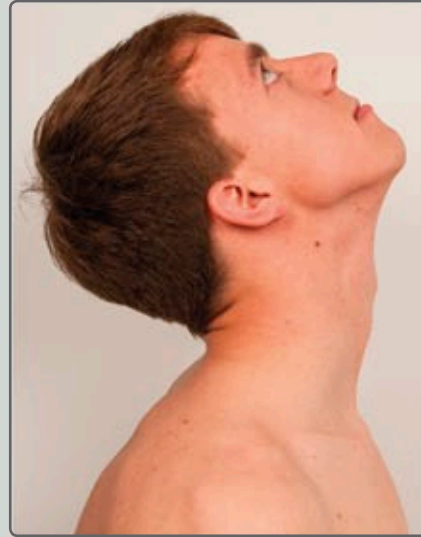
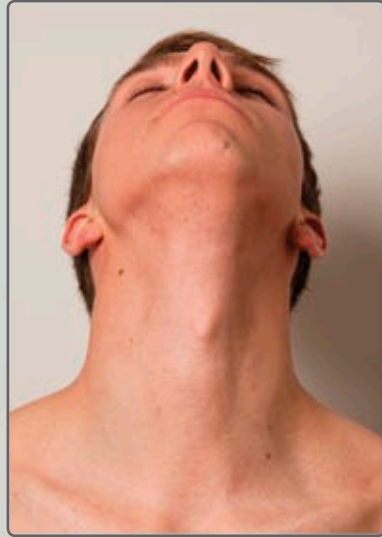
1	FRONTALIS MUSCLE	11	MASSETER MUSCLE
2	TEMPORAL MUSCLE	12	ORBICULARIS ORIS MUSCLE
3	ORBICULARIS OCULI MUSCLE	13	DEPRESSOR ANGULI ORIS MUSCLE
4	NASALIS MUSCLE	14	DEPRESSOR LABII INFERIORIS MUSCLE
5	OTTO'S MUSCLE	15	MENTALIS MUSCLE
6	LEVATOR LABII SUPERIORIS MUSCLE	16	PROCERUS MUSCLE
7	ZYGOMATICUS MINOR MUSCLE	17	CORRUGATOR MUSCLE
8	ZYGOMATICUS MAJOR MUSCLE	18	OCCIPITALIS MUSCLE
9	RISORIIUS MUSCLE	Z	ZYGOMATIC BONE
10	BUCCINATOR MUSCLE	ZA	ZYGOMATIC ARCH
M	MANDIBLE (LOWER JAW)	EA	EPICRANIAL APONEUROSIS

MAIN NECK MUSCLES



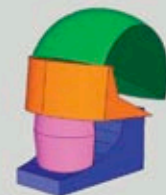
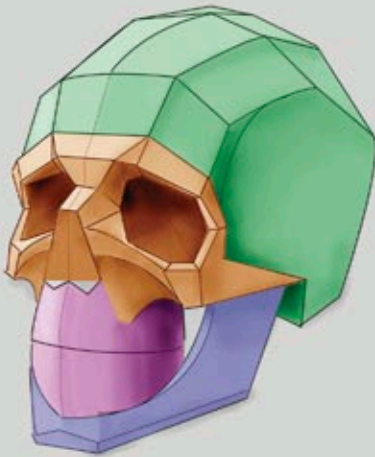
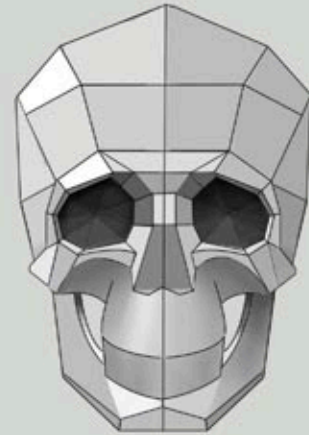
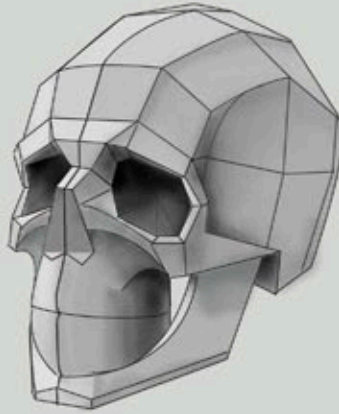
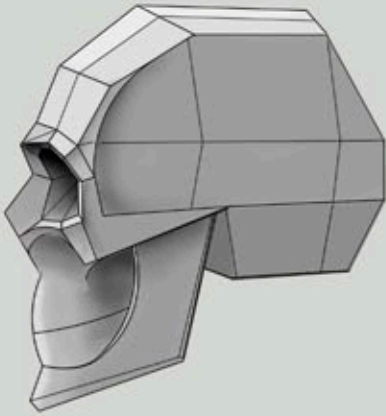
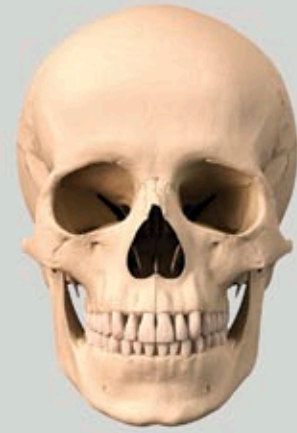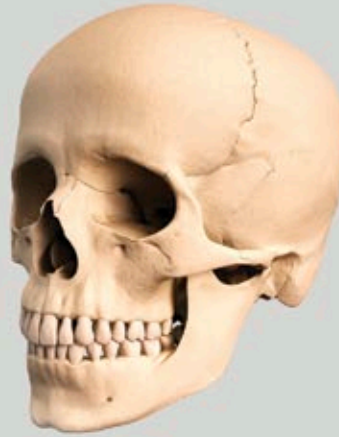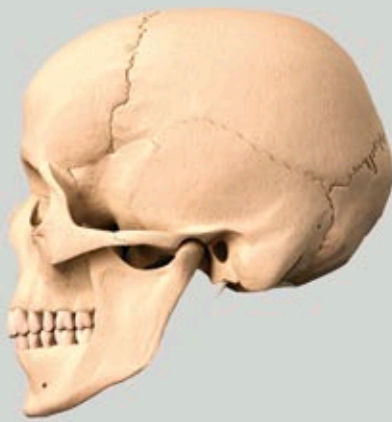- | | | |
|---------------------------------|-------------------------------|-----------------------------------|
| 1 STERNOCLEIDOMASTOID | 4 CHEST BONE (STERNUM) | 7 SUPRAHYOID MUSCLES |
| 2 TRAPEZIUS | 5 INFRAHYOID MUSCLES | 8 SHOULDER BLADE (SCAPULA) |
| 3 COLLAR BONE (CLAVICLE) | 6 HYOID BONE | |

MAIN NECK MUSCLES

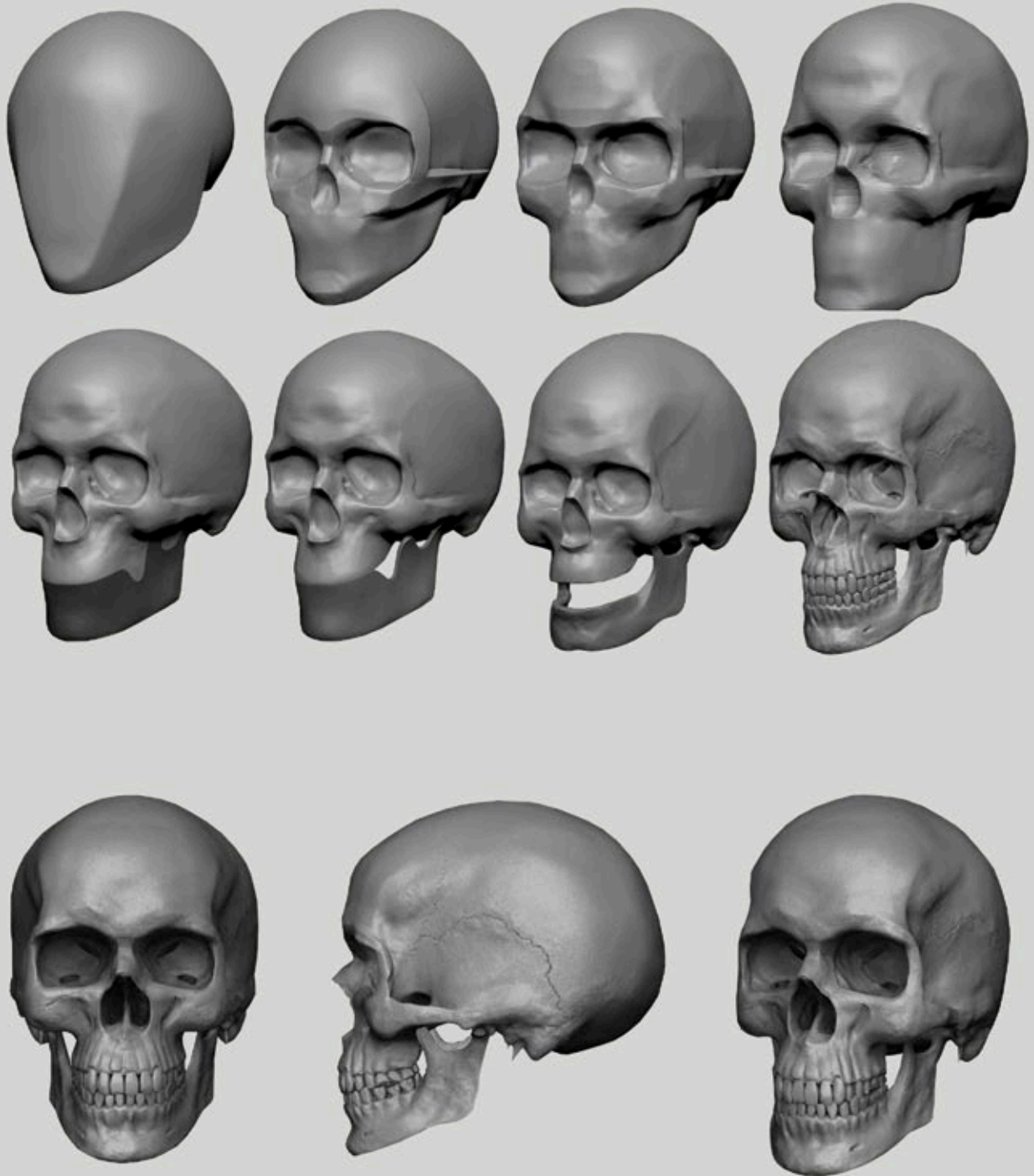


- | | | |
|------------------------|---------------------------------------|-------------------------|
| 1 LOWER JAW (MANDIBLE) | 9 ADAM'S APPLE (LARYNGEAL PROMINENCE) | 17 SEMISPINALIS CAPITIS |
| 2 MASSETER | 10 TRAPEZIUS | 18 HYOGLOSSUS |
| 3 MYLOHYOID | 11 STERNOCLEIDOMASTOID | 19 SPLENIUS CAPITIS |
| 4 DIGASTRIC | 12 CRICOTHYROID | 20 LEVATOR SCAPULAE |
| 5 STYLOHYOID | 13 STERNOTHYROID | 21 SCALENUS POSTERIOR |
| 6 HYOID BONE | 14 THYROID GLAND | 22 SCALENUS MEDIUS |
| 7 OMOHYOID | 15 TRACHEA | 23 SCALENUS ANTERIOR |
| 8 STERNOHYOID | 16 PAROTID GLAND | |


SHAPES THAT FORM A SKULL



MODELING A 3D SKULL

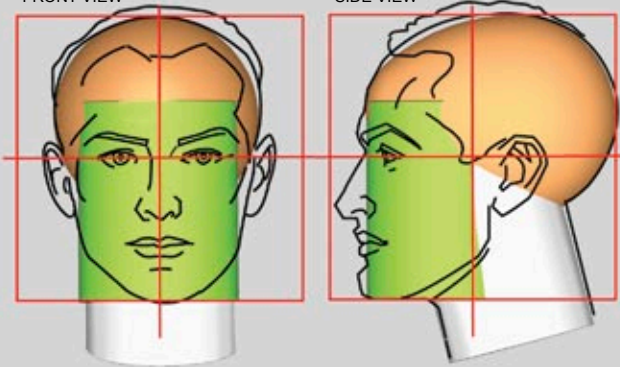


HEAD SHAPE AND MASSES

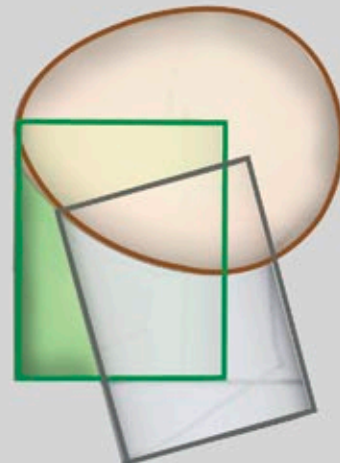

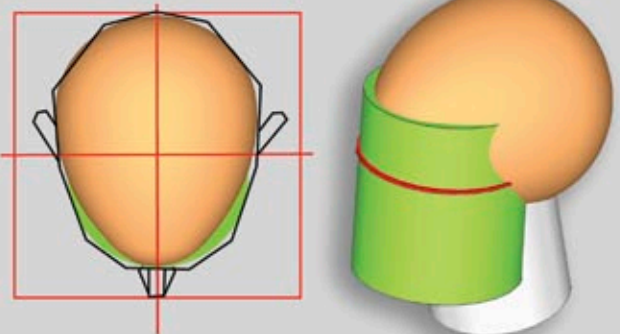


FRONT VIEW

SIDE VIEW

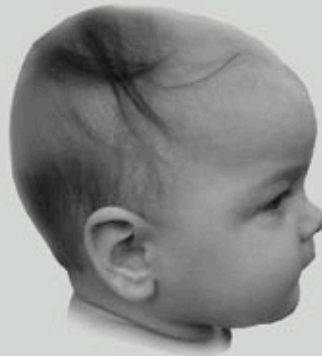

TOP VIEW

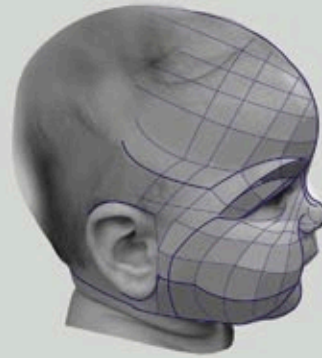
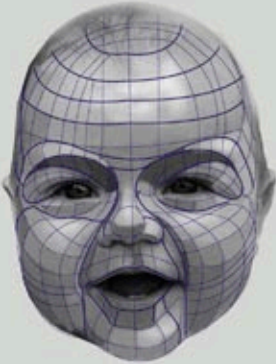


BABY HEAD

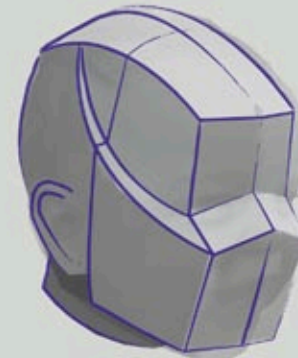
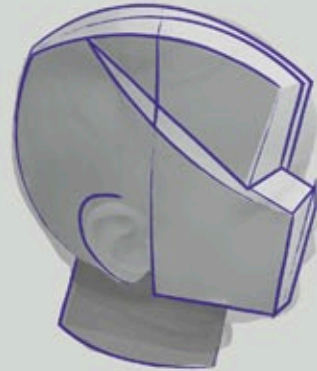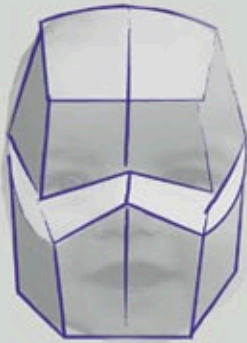REAL



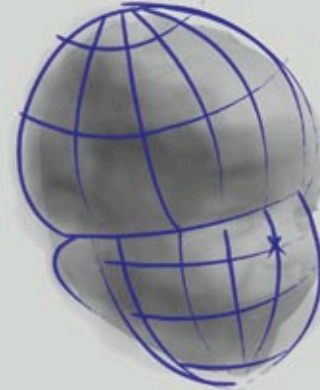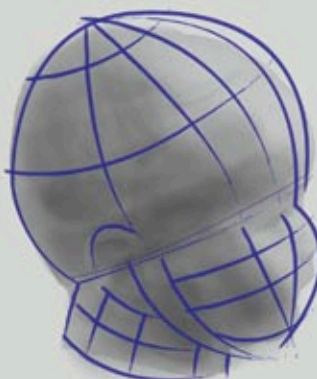MESH



BLOCK-OUT

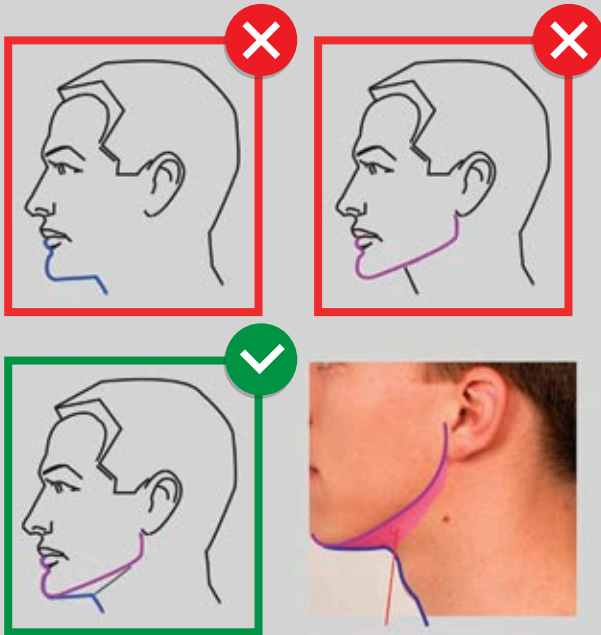


MASSES



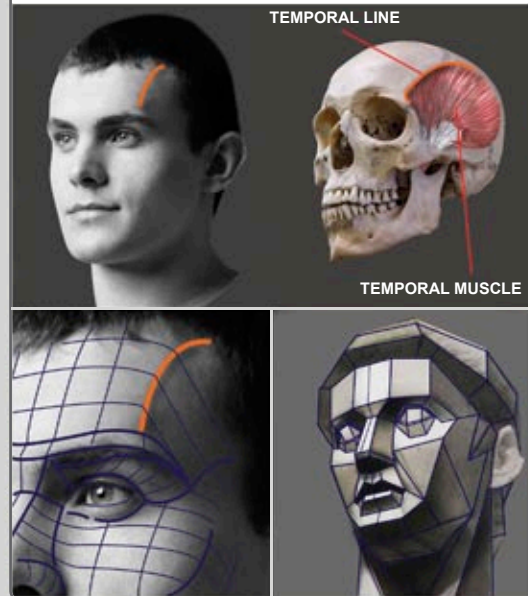
THE HEAD SHAPE

CONTOUR OF THE CHIN
IS NOT THE SAME AS **JAWLINE**.



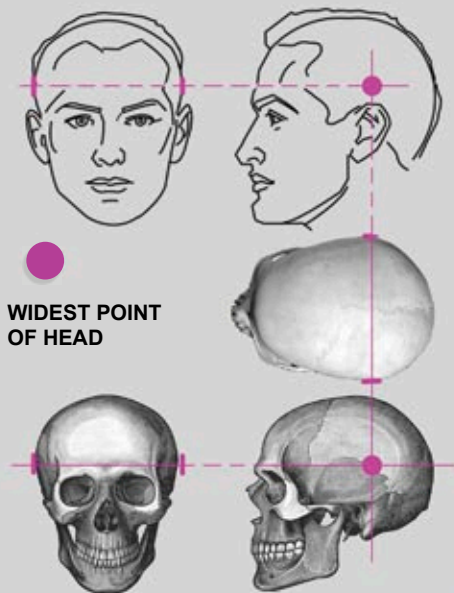
SUPRAHYOID MUSCLES

TEMPORAL LINE (THE EDGE BETWEEN
TEMPORAL BONE AND FOREHEAD PLANE).



TEMPORAL LINE

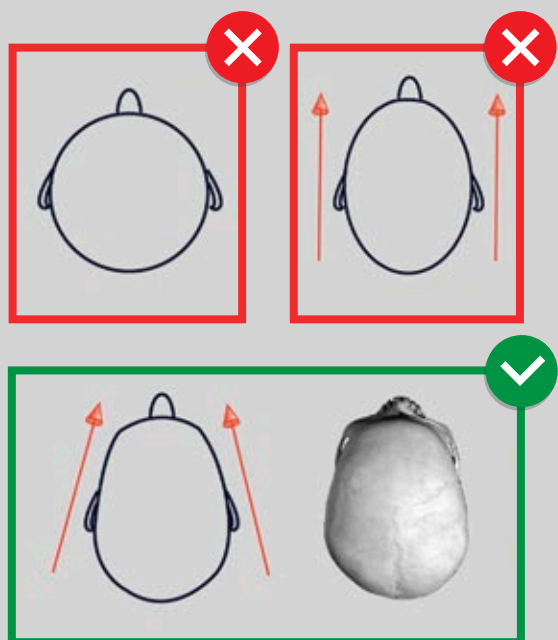
TEMPORAL MUSCLE



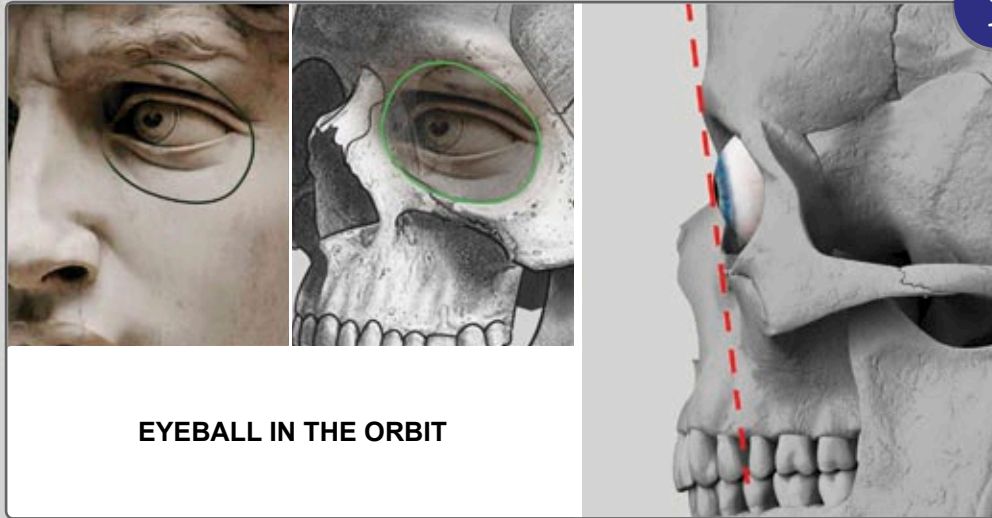
WIDEST POINT
OF HEAD



HEAD IS NOT ROUND.



FRAMING THE EYES




EYEBROWS

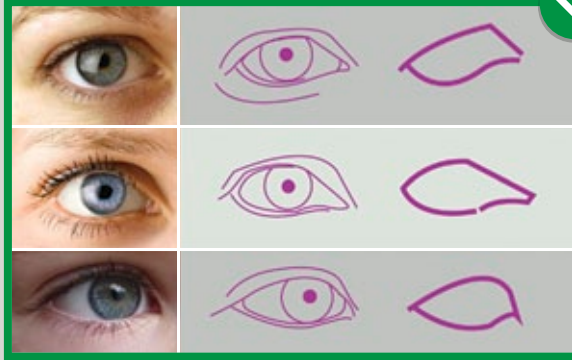
! **EYEBROW** CHANGES DIRECTION AS IT RUNS ACROSS **THE TEMPORAL LINE**, SLOPING DOWN AND BACK TOWARD THE EAR.




ALL ABOUT EYES

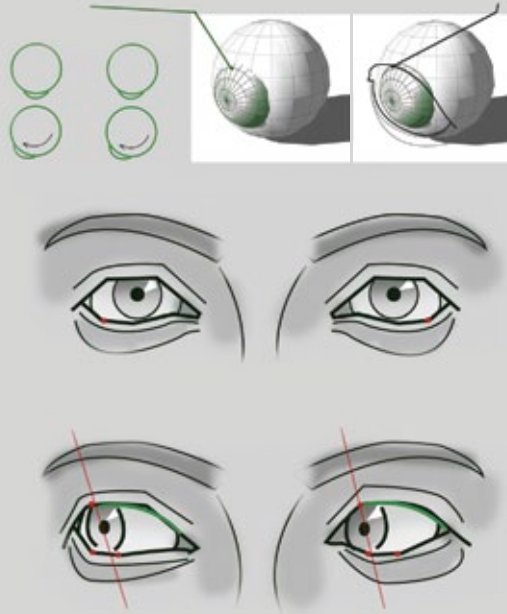
EVERY EYE HAS ITS OWN CHARACTER!











CORNEA PUSHES OUTWARD AND CHANGES THE EYELID SHAPE.

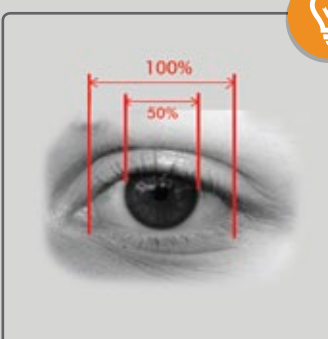


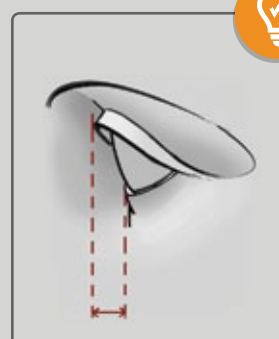










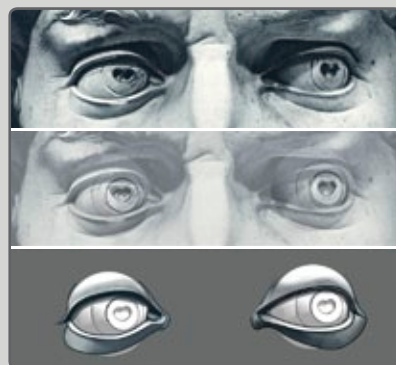












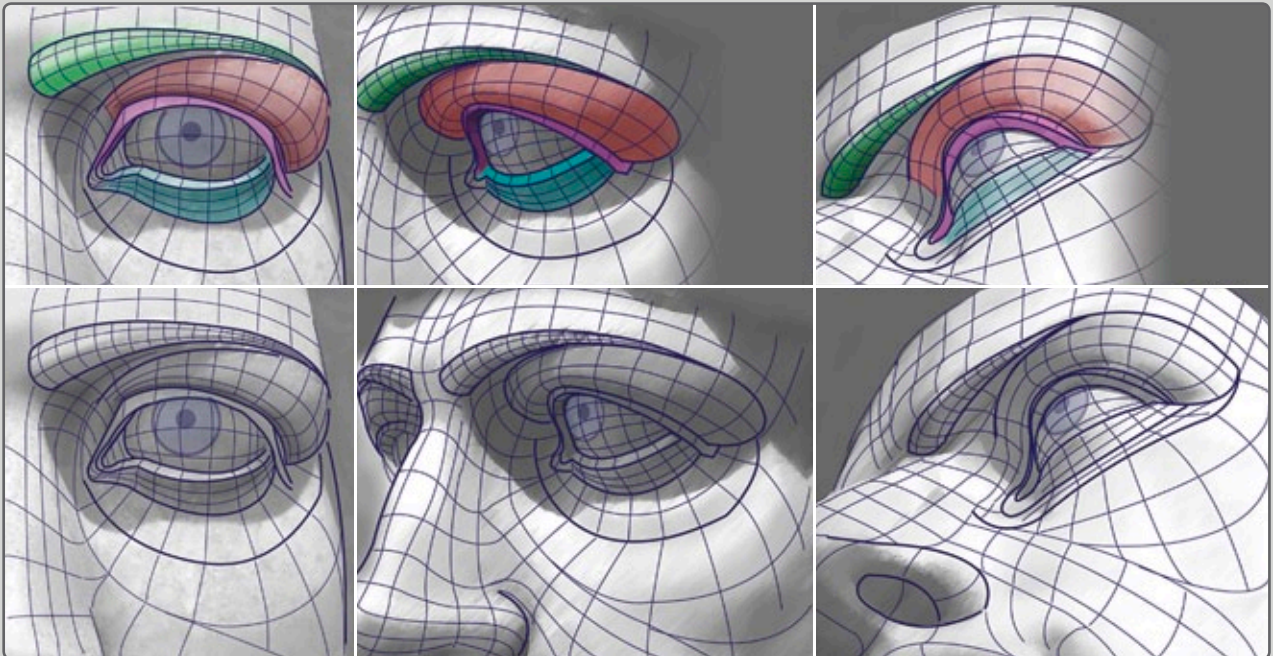
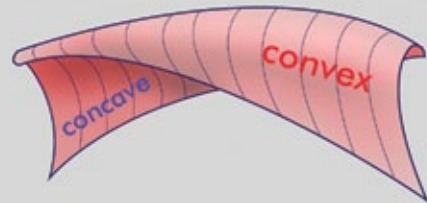
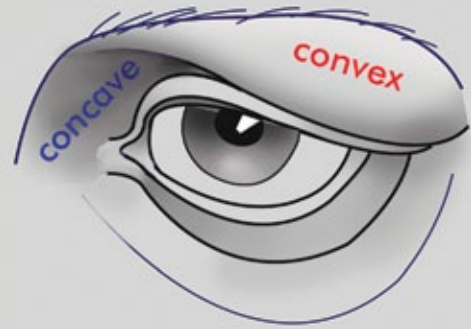
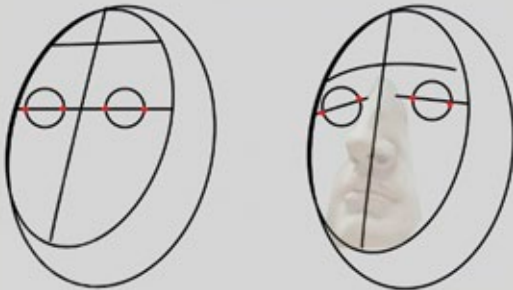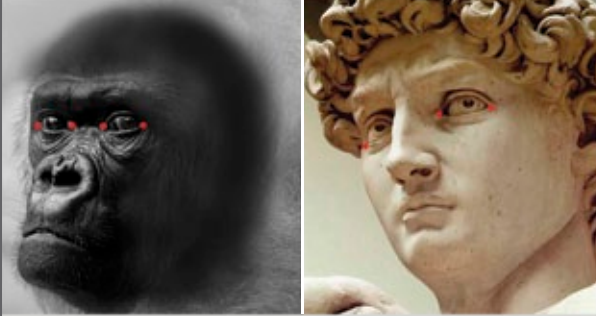
			
			
2/5 COVERED	1/4 COVERED	OPEN PUPIL	EYE WIDE OPEN



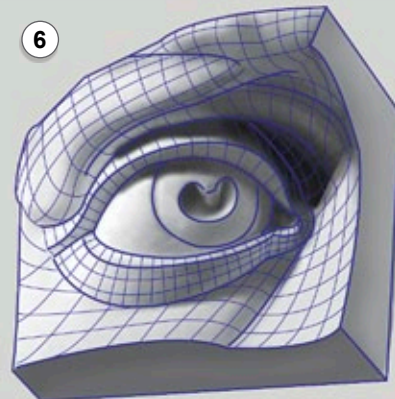
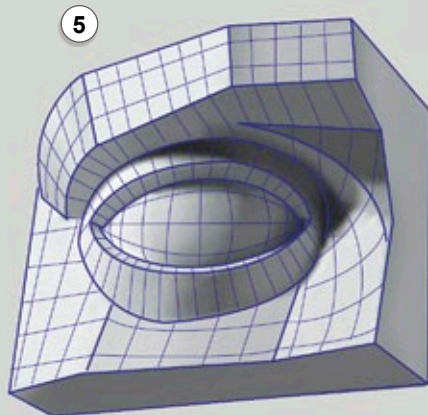
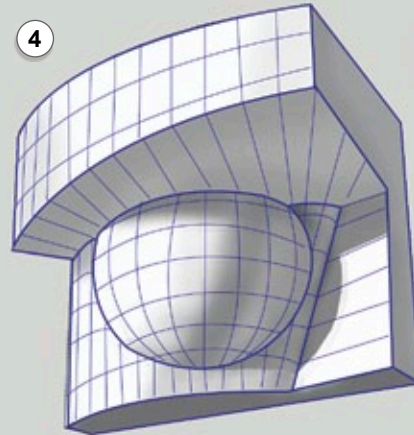
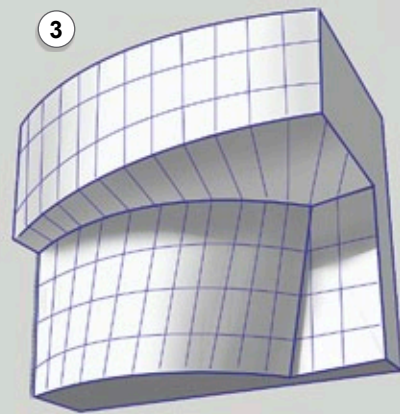
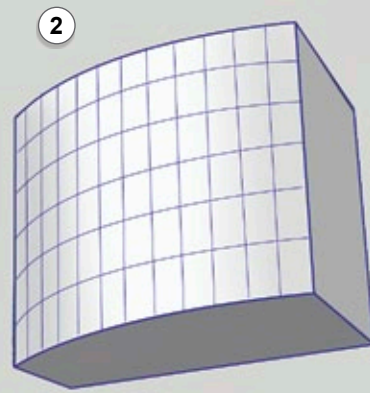
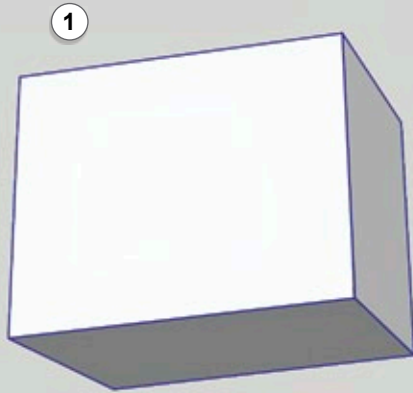


EYE

WHAT MAKES A FACE LOOK FLAT?



BLOCKING-OUT A CLASSICAL EYE (STEP-BY-STEP)



EYES COME IN A VARIETY OF SHAPES

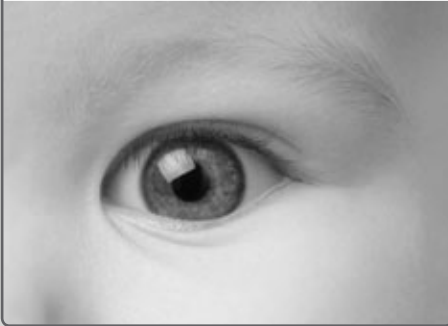ADULT FEMALE



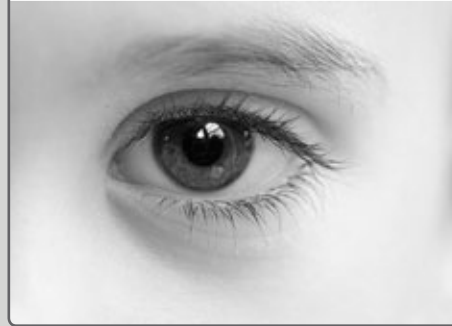ADULT MALE



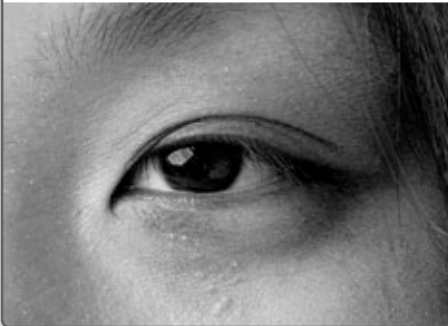BABY



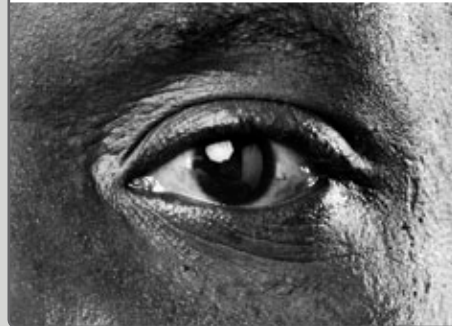CHILD



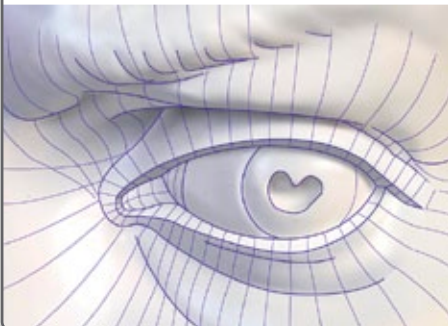
ASIAN



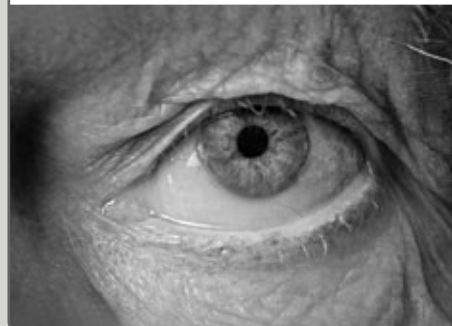BLACK



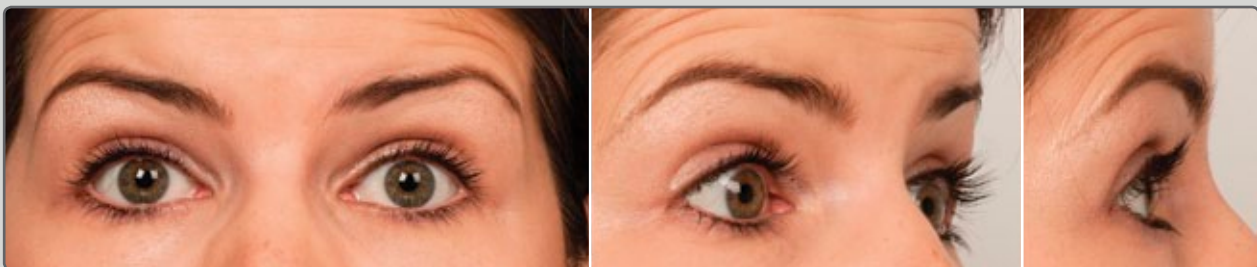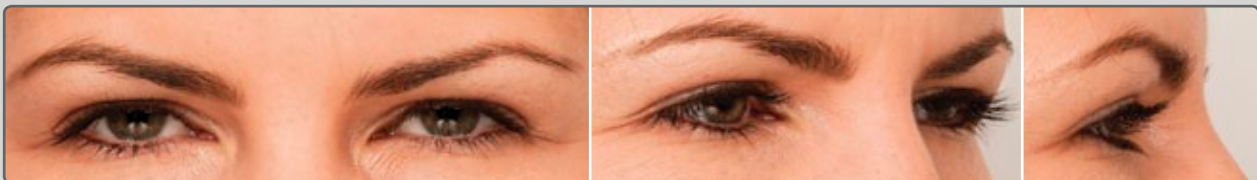
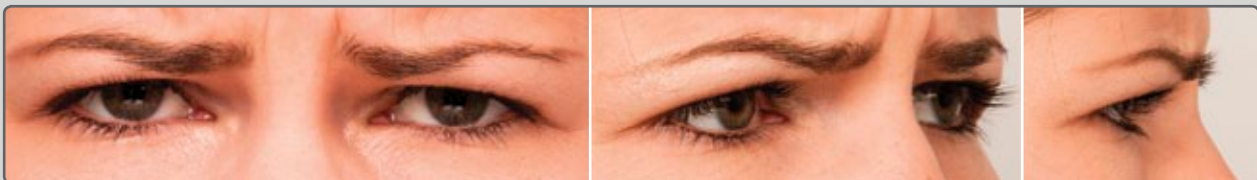
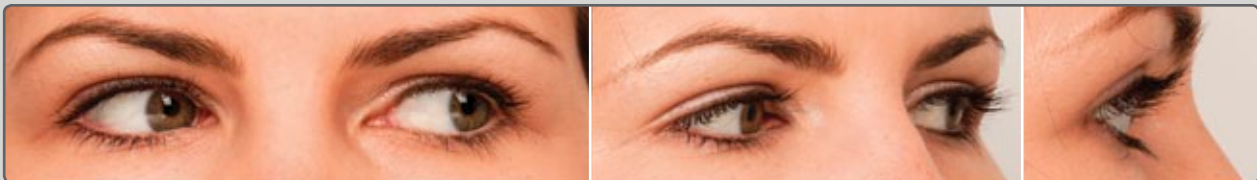
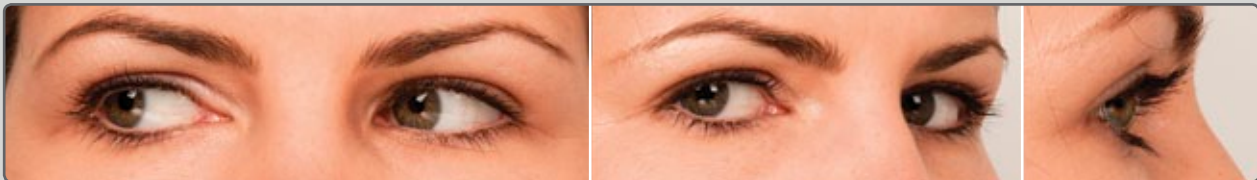
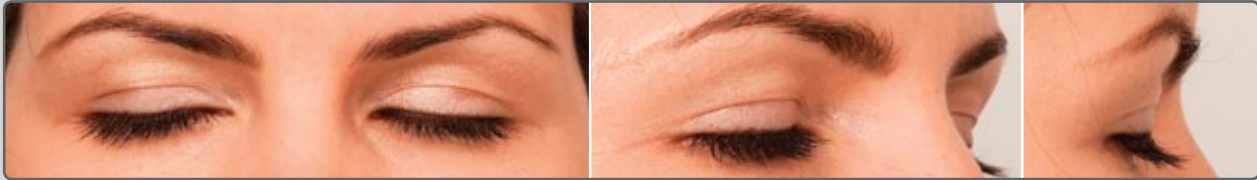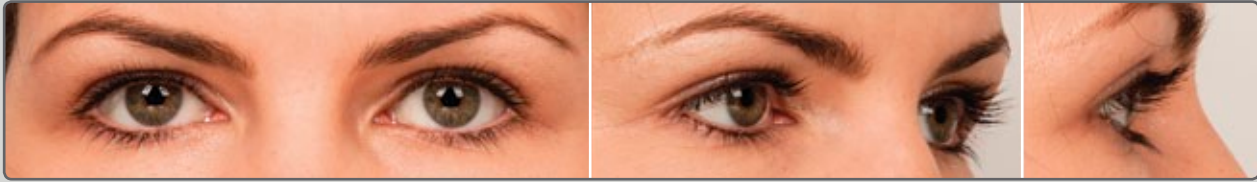CLASSICAL SCULPTURE



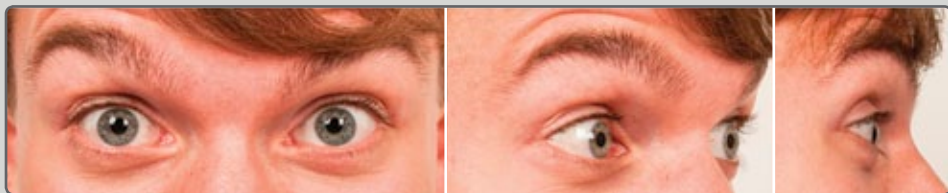
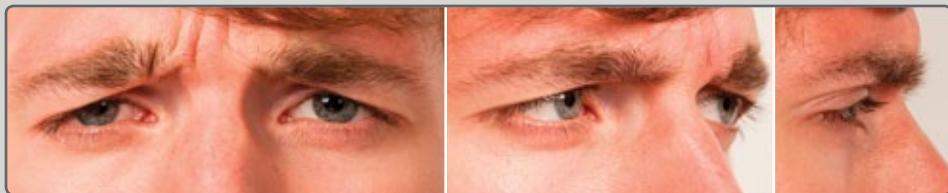
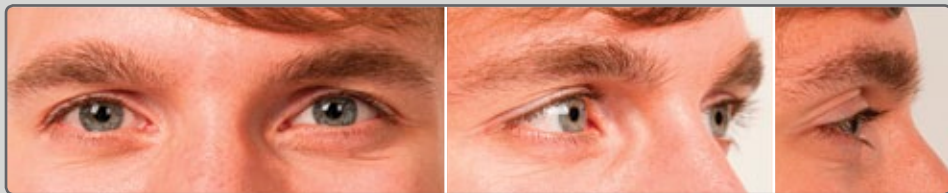
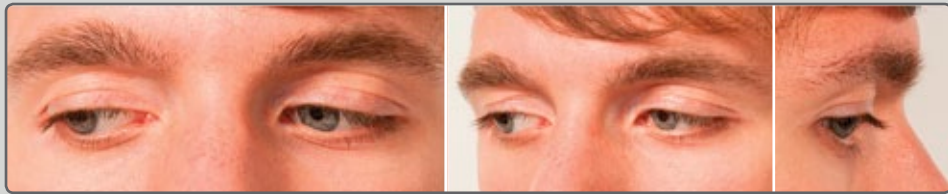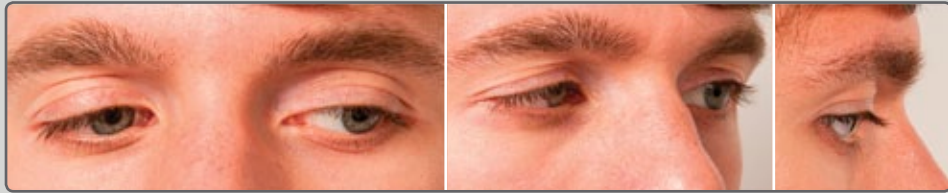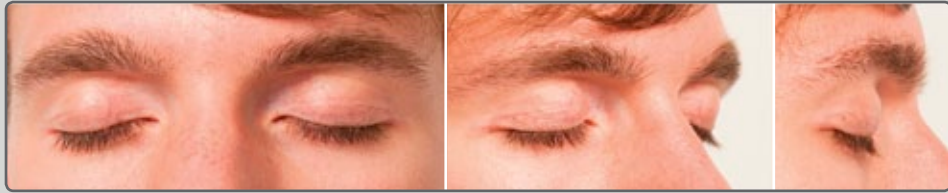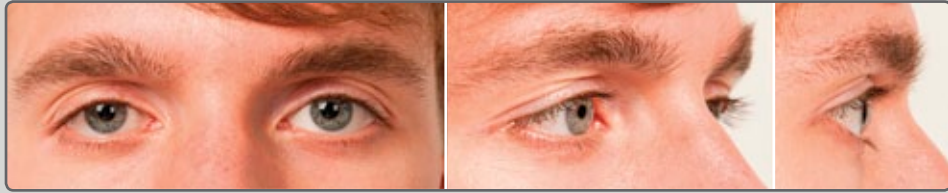SENIOR



EYE MOVEMENTS (EXPRESSIONS)



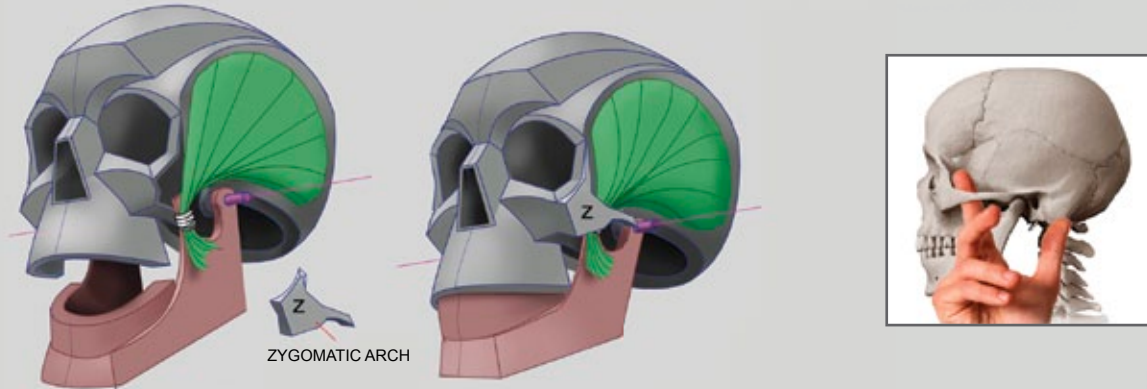
EYE MOVEMENTS (EXPRESSIONS)



WHAT STRONG JAWS YOU HAVE!

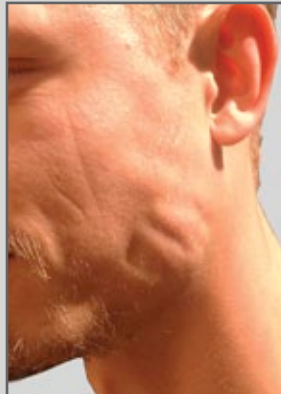
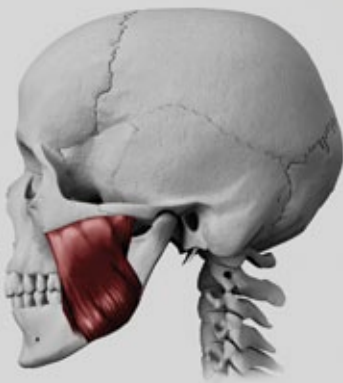i

TEMPORALIS MUSCLE – HELPS TO CLOSE THE MOUTH AND KEEP IT SHUT!



i

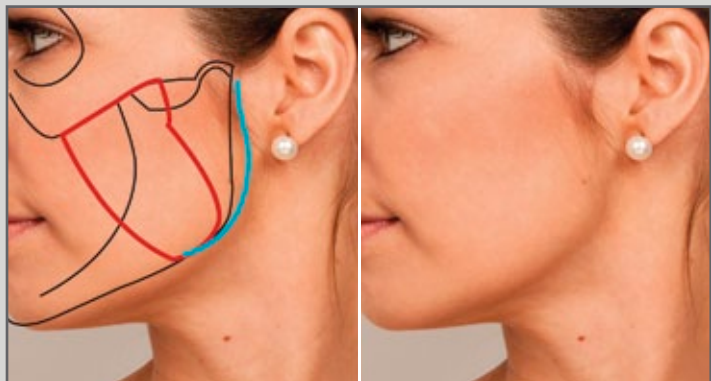
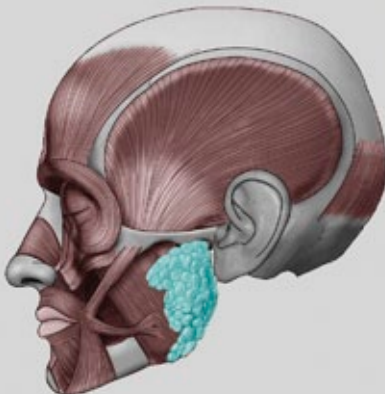
THE CHEWING MUSCLE (MASSETER MUSCLE).



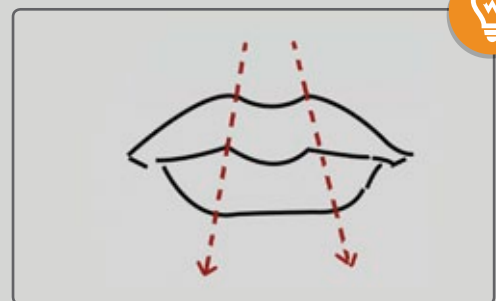
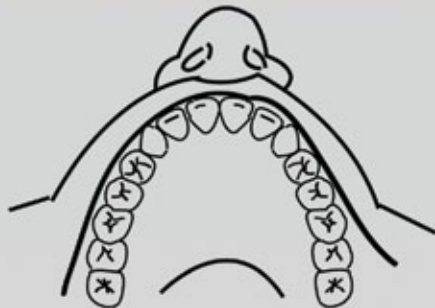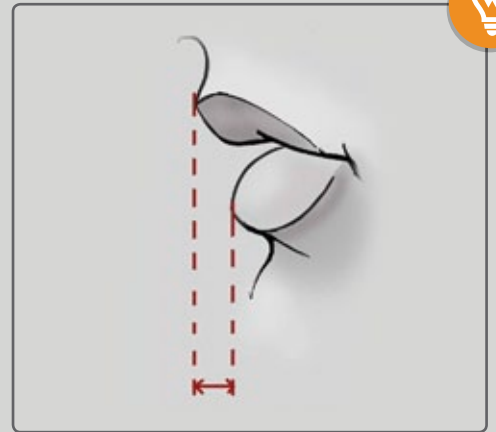
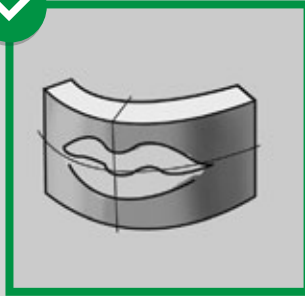
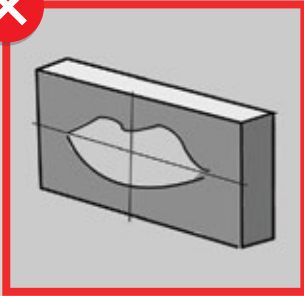
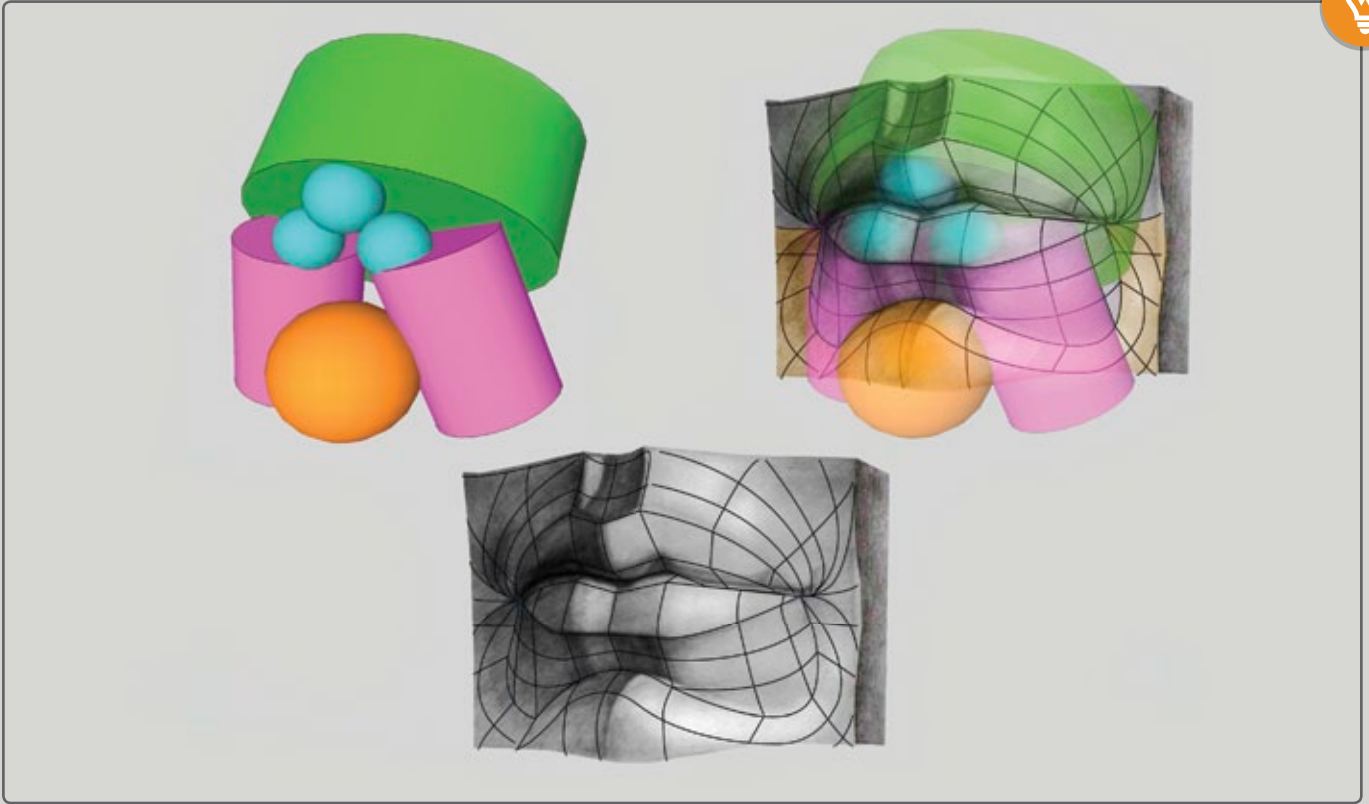
IT IS THE PRIMARY CHEWING MUSCLE AND PULLS THE JAWS CLOSED. ITS OUTER PORTION ORIGINATES FROM THE ZYGOMATIC ARCH AND INSERTS ON THE SURFACE OF THE RAMUS OF THE MANDIBLE.

i

PAROTID GLAND (SALIVARY GLAND) ALSO PLAYS IMPORTANT ROLE IN SHAPING THE JAWLINE AND FACE.

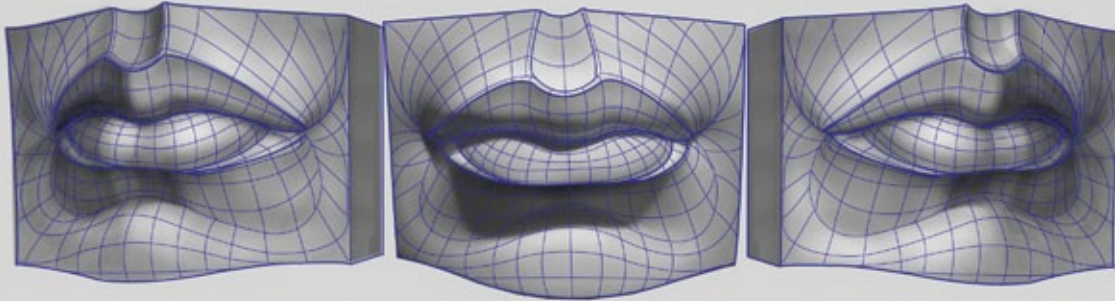


UNDERSTANDING MOUTH CURVATURE

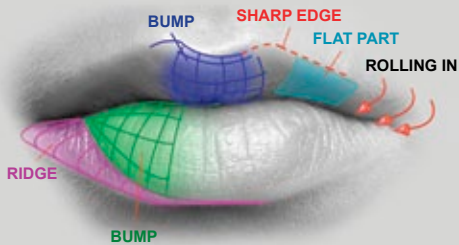


SHAPE OF STILL LIPS

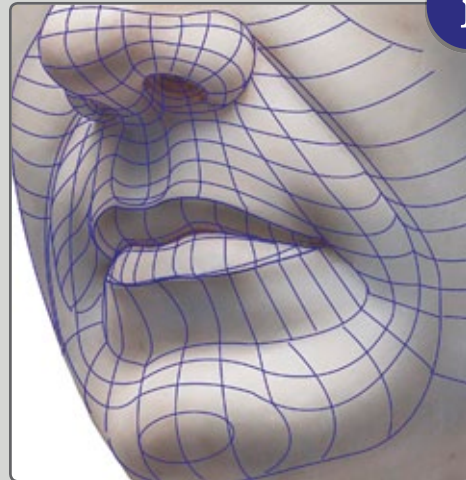
i



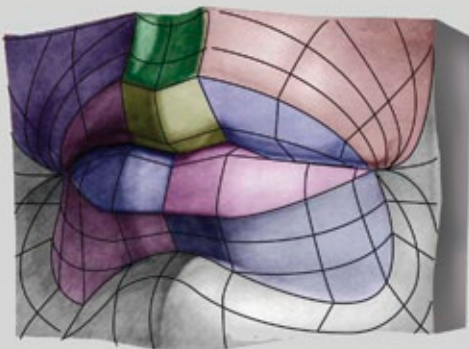
i



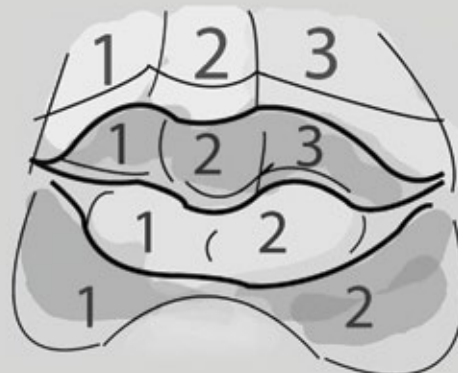i



i



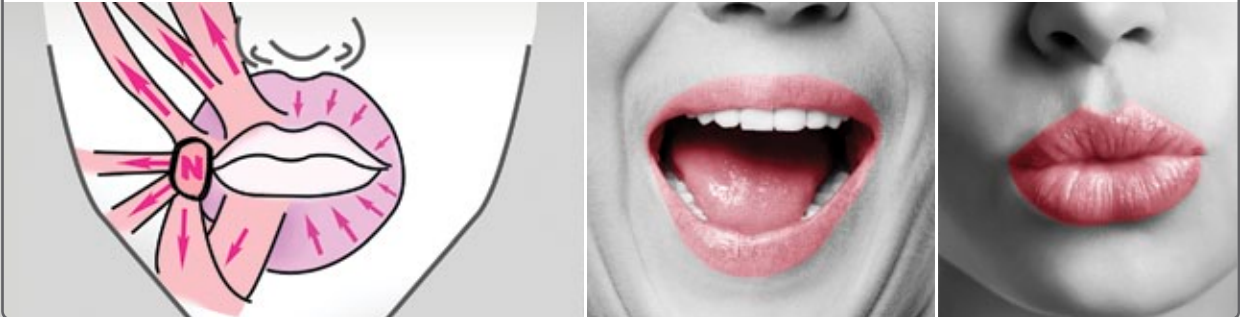i



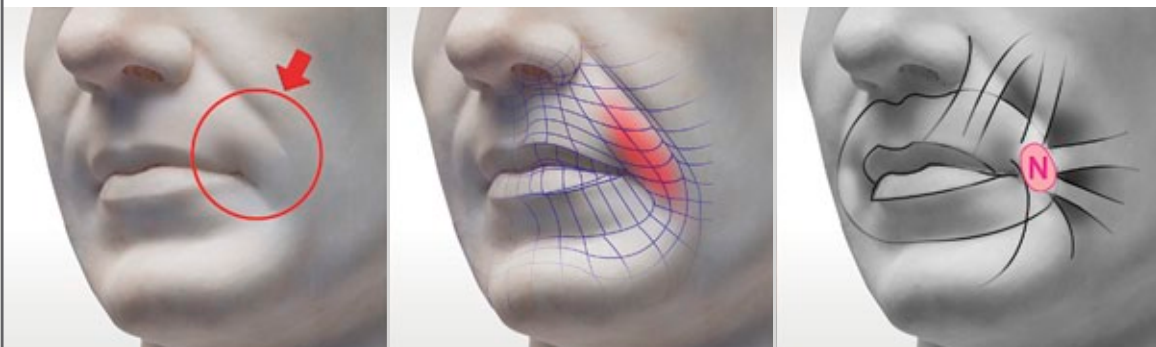
MOUTH



MOUTH EXPRESSIONS – IT'S ALL ABOUT PULLING AND SQUEEZING.



WHAT IS THIS BUMP?

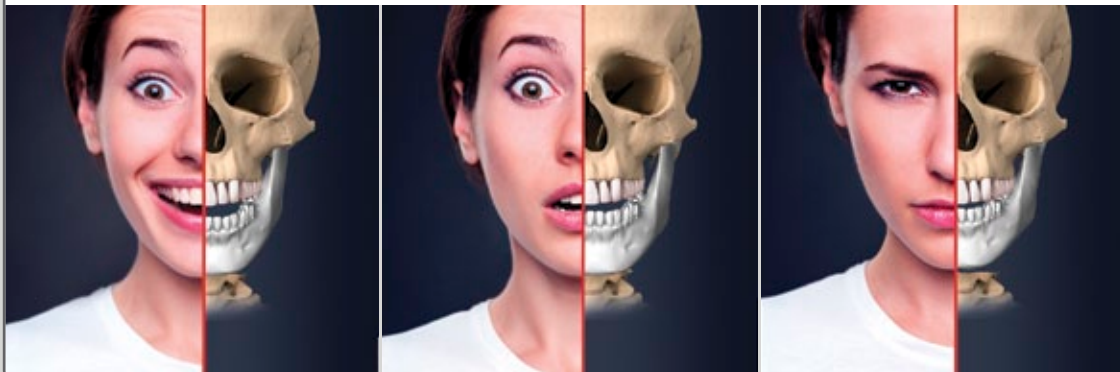

IT IS CALLED THE “**NODE**”.

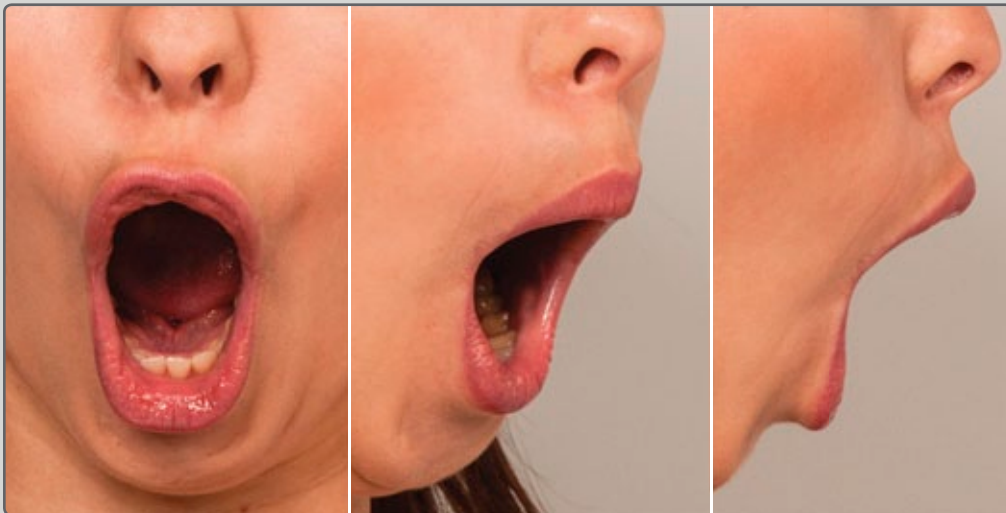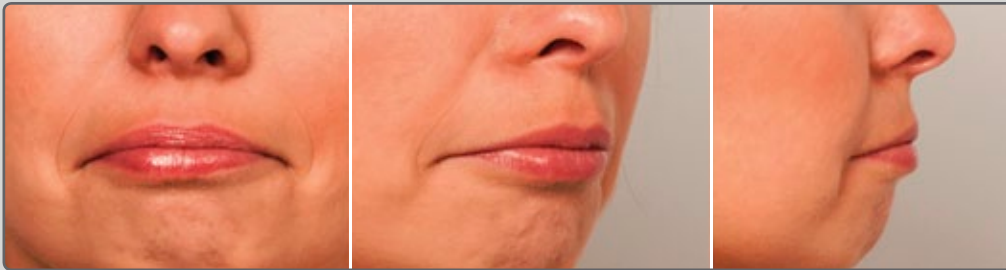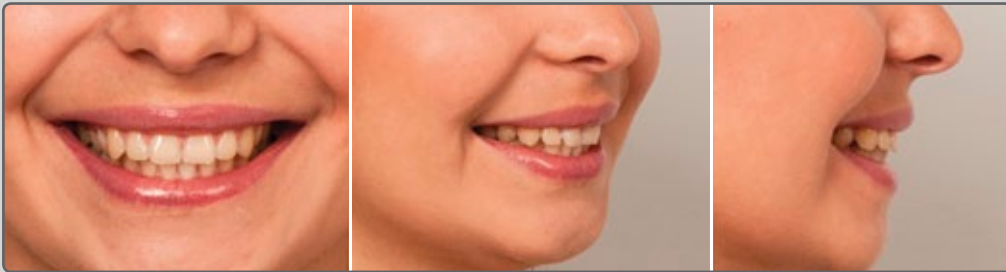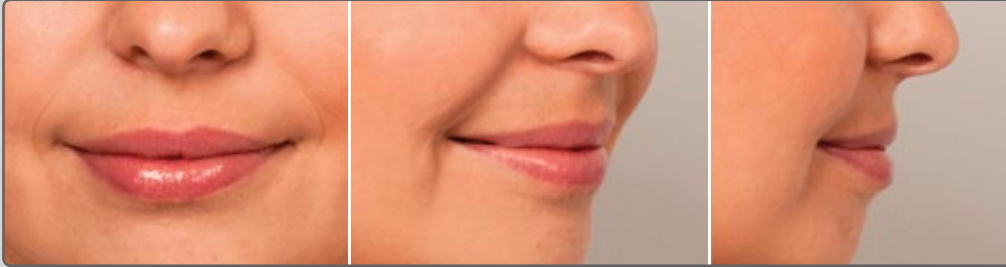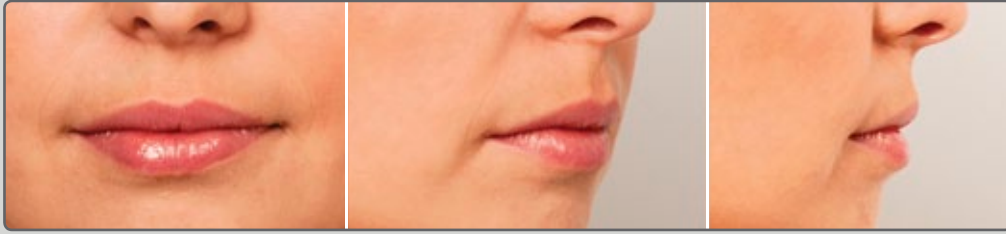IT IS THE POINT WHERE SEVERAL FACIAL MUSCLES CONNECT TO THE CORNER OF THE MOUTH.



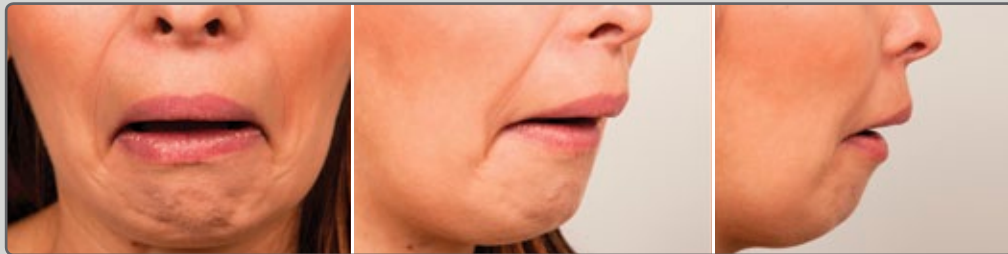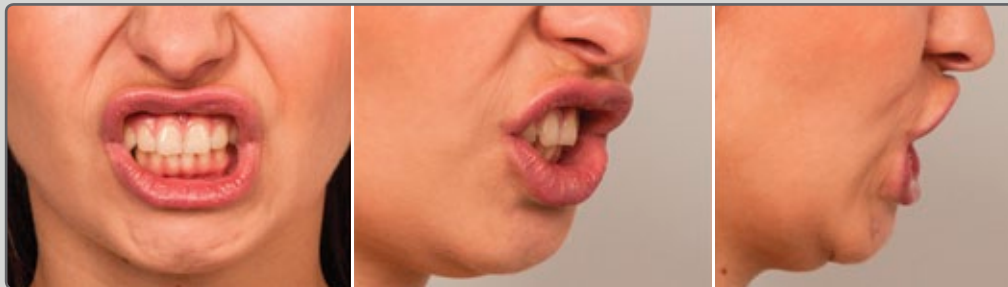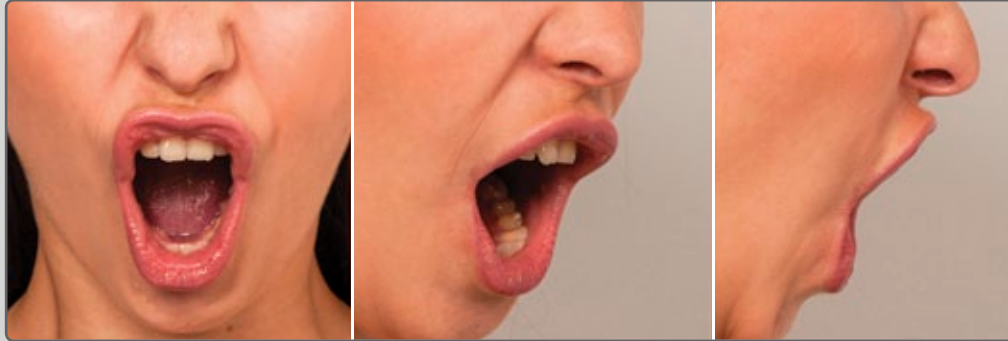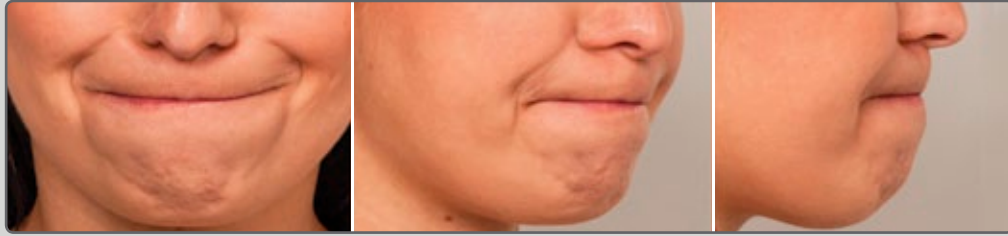WHEN YOU SCULPT EXPRESSIONS, REMEMBER BONY LANDMARKS! BY PULLING IN DIFFERENT DIRECTIONS, THESE MUSCLES CREATE THE EXPRESSIONS, WHILE SKULL REMAINS THE SAME.



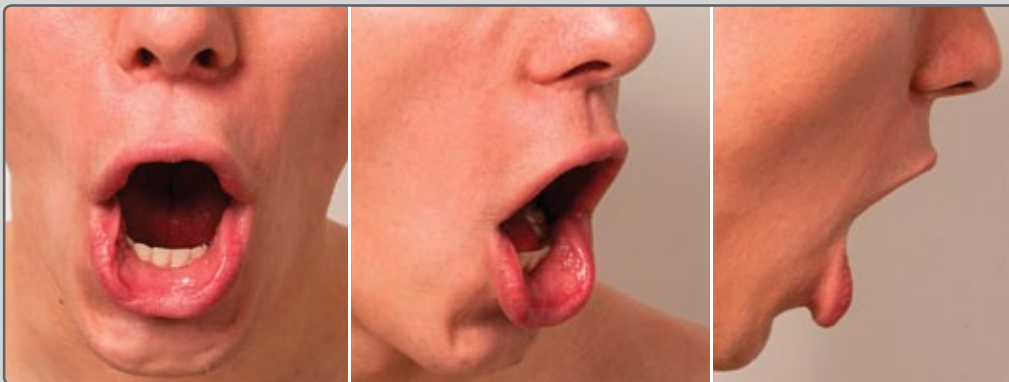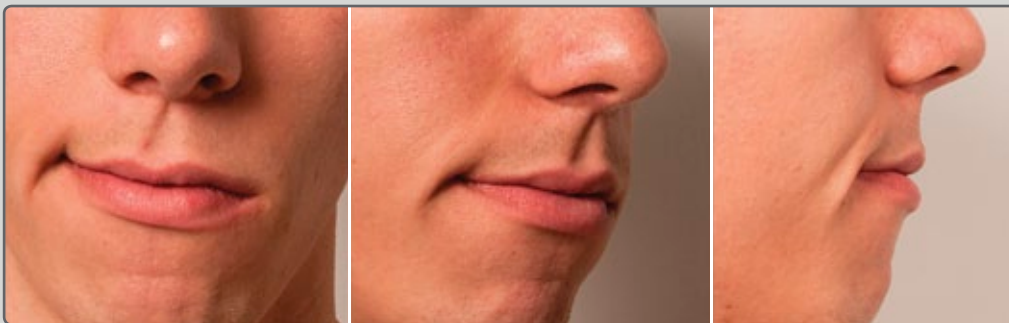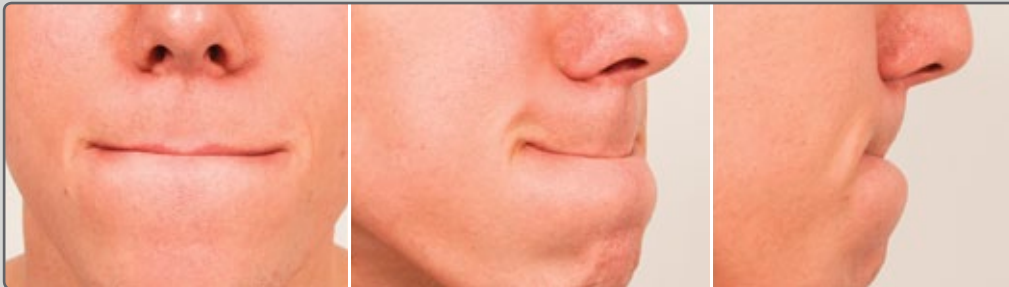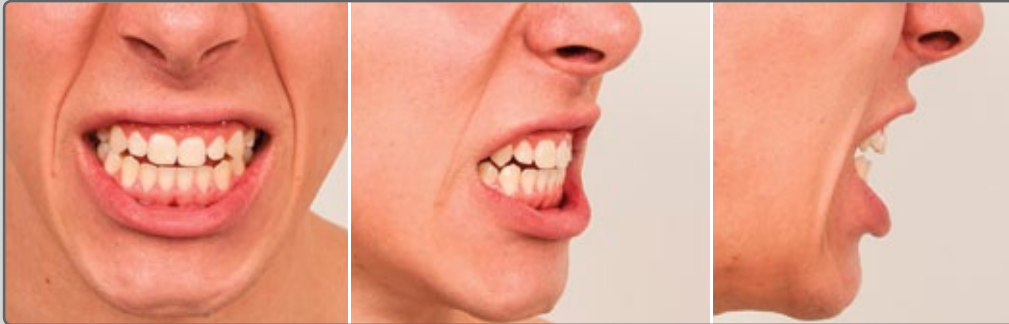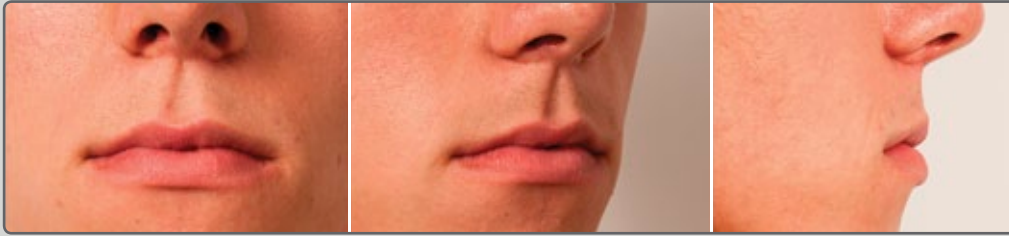MOUTH EXPRESSIONS



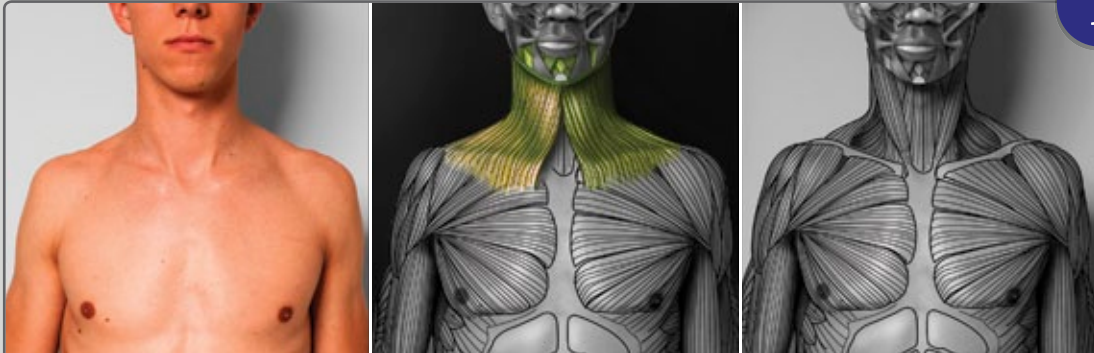
MORE MOUTH EXPRESSIONS



EVEN MORE MOUTH EXPRESSIONS

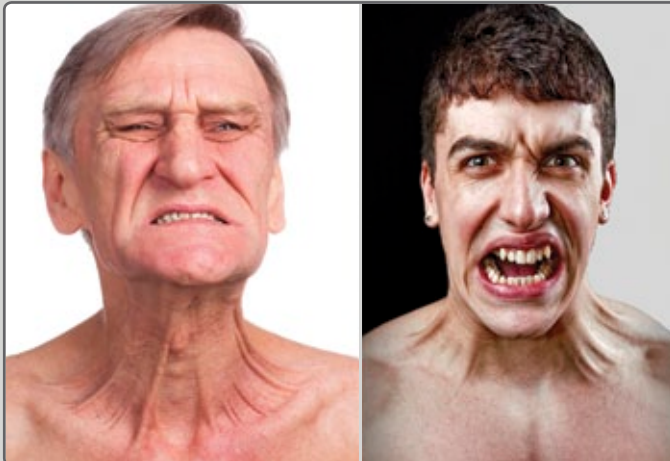

PLATYSMA MUSCLE



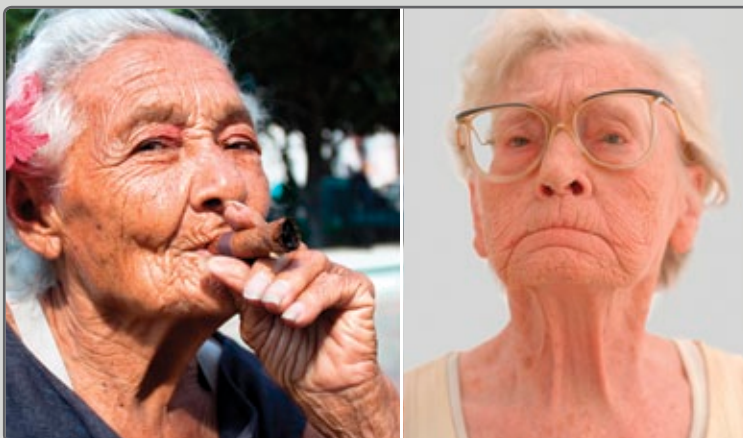i

THE PLATYSMA IS A BROAD, THIN LAYER OF MUSCLE THAT IS SITUATED ON EACH SIDE OF THE NECK IMMEDIATELY UNDER THE SUPERFICIAL FASCIA.



i

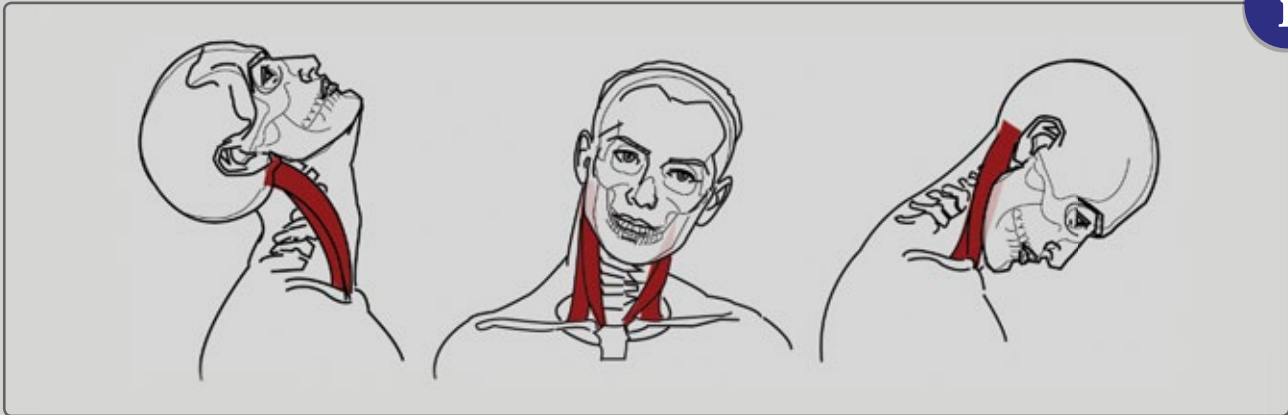
THE PLATYSMA BELONGS TO THE GROUP OF FACIAL MUSCLES AND DRAWS THE CORNERS OF THE LOWER LIP AND MOUTH TO THE SIDES AND DOWNWARD. WHEN FLEXED FORCEFULLY, IT EXPANDS THE NECK AND DRAWS ITS SKIN UPWARD.



!

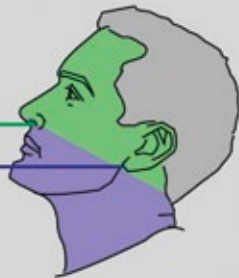WEAKNESS OF THIS MUSCLE IS OFTEN THE MAJOR FACTOR IN CAUSING SAGGING UNDER THE CHIN IN OLDER PEOPLE (THIS IS NOT DUE TO AGING SKIN OR FROM FAT ACCUMULATION).

STERNOCLEIDOMASTOID MUSCLE IN ACTION



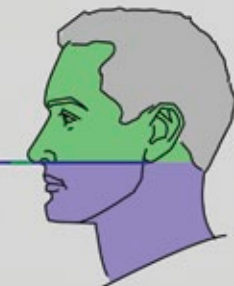
HEAD UP (BN) ABOVE (BE)

BOTTOM OF NOSE (BN)
BOTTOM OF EAR (BE)



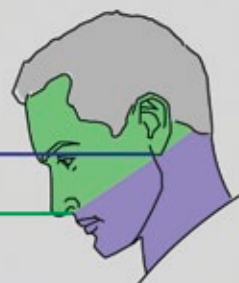
HEAD STRAIGHT (BN) LINED UP WITH (BE)

(BN) = (BE)



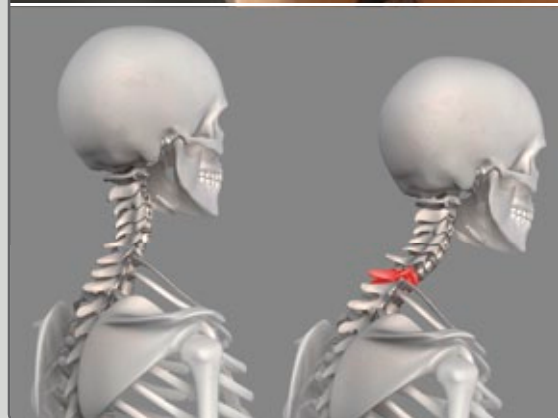
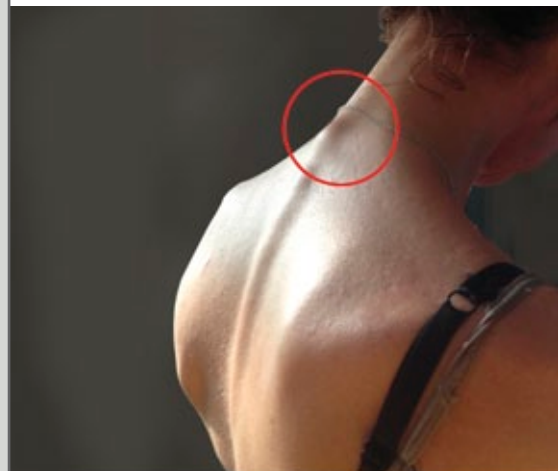HEAD DOWN (BE) ABOVE (BN)

BOTTOM OF EAR (BE)
BOTTOM OF NOSE (BN)

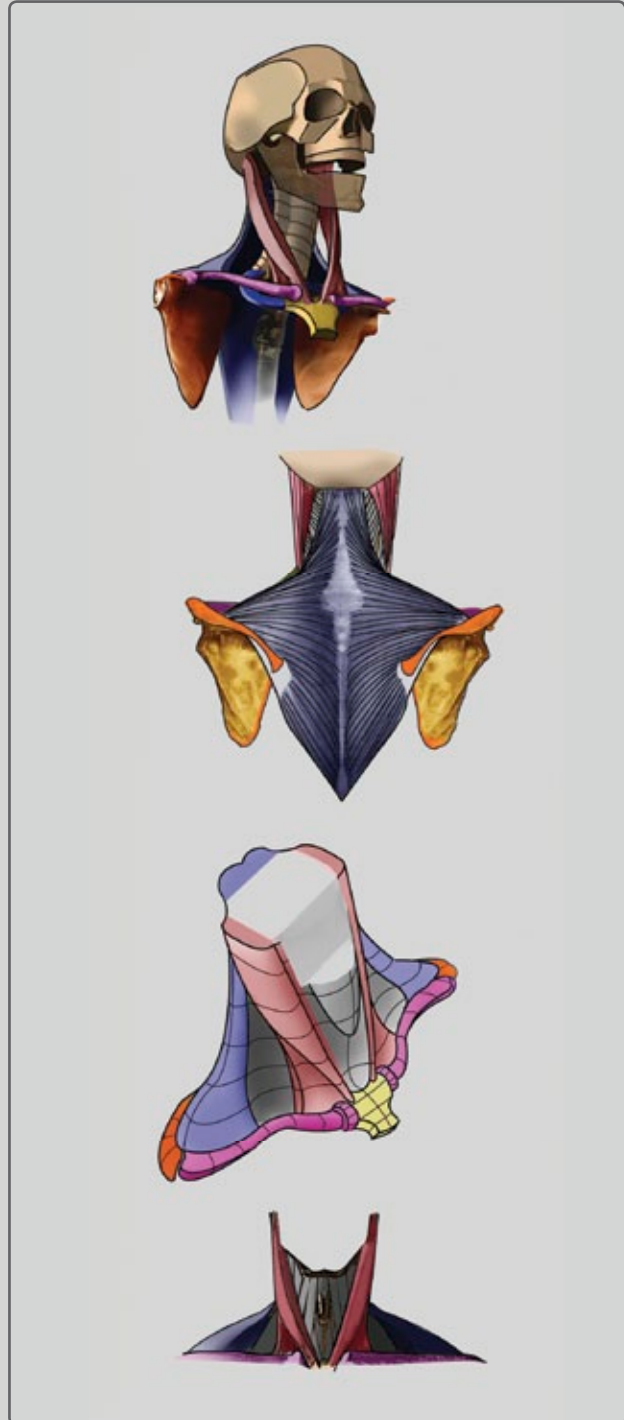
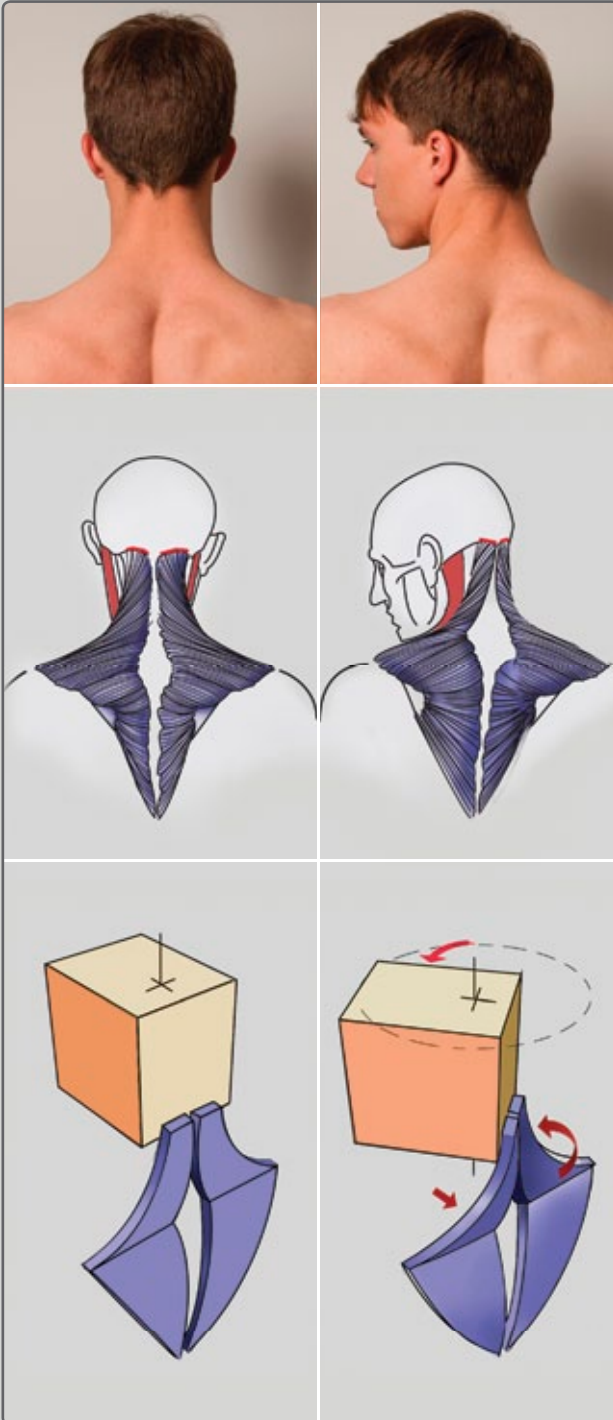


7TH CERVICAL VERTEBRAL BONE
(WHERE THE NECK MEETS THE SHOULDERS).

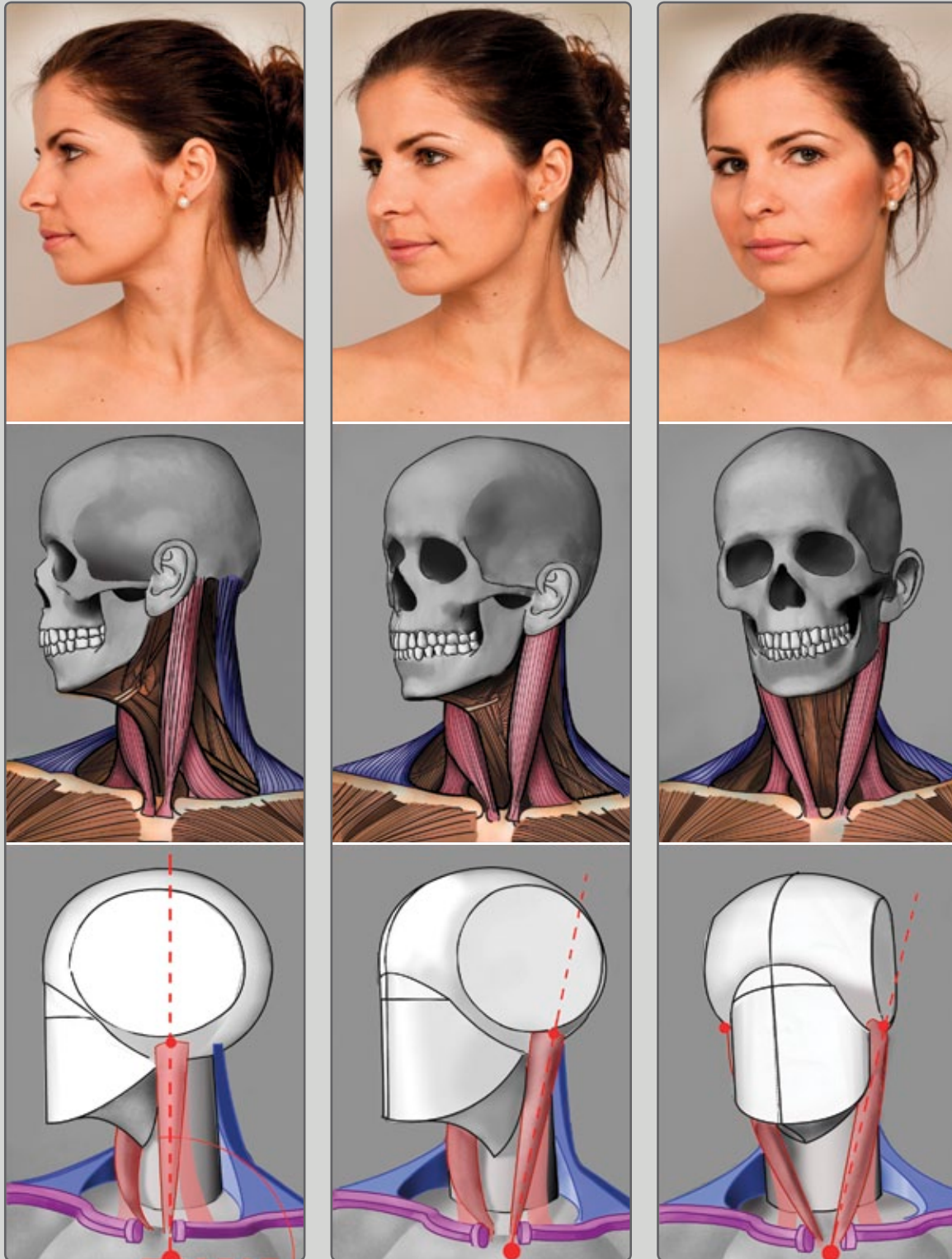
WHEN HEAD IS BENT FORWARD, YOU CAN SEE PROMINENT VERTEBRA AT THE TOP OF THE SPINE PROTRUDING OUTWARD SLIGHTLY.



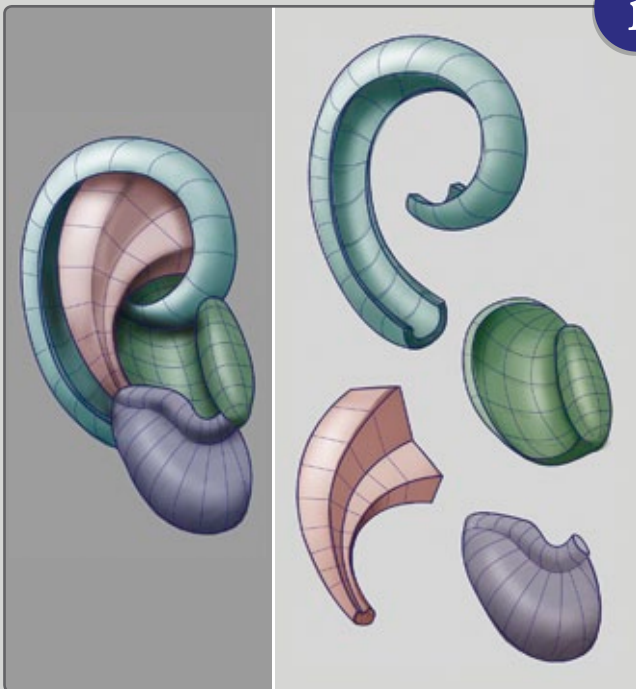

TRAPEZIUS MUSCLE, STERNOCLEIDOMASTOID MUSCLE



MAJOR NECK MUSCLES (**TRAPEZIUS** AND **STERNOCLEIDOMASTOID**)



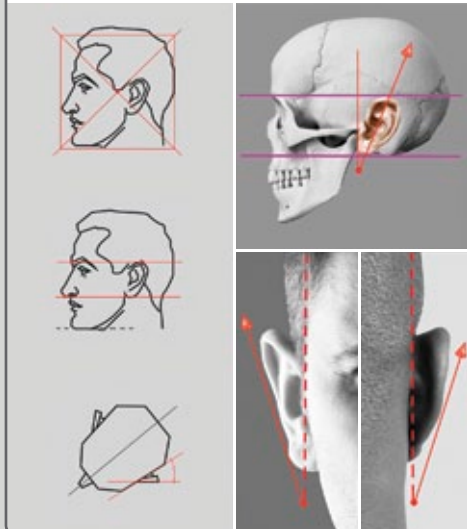
EAR



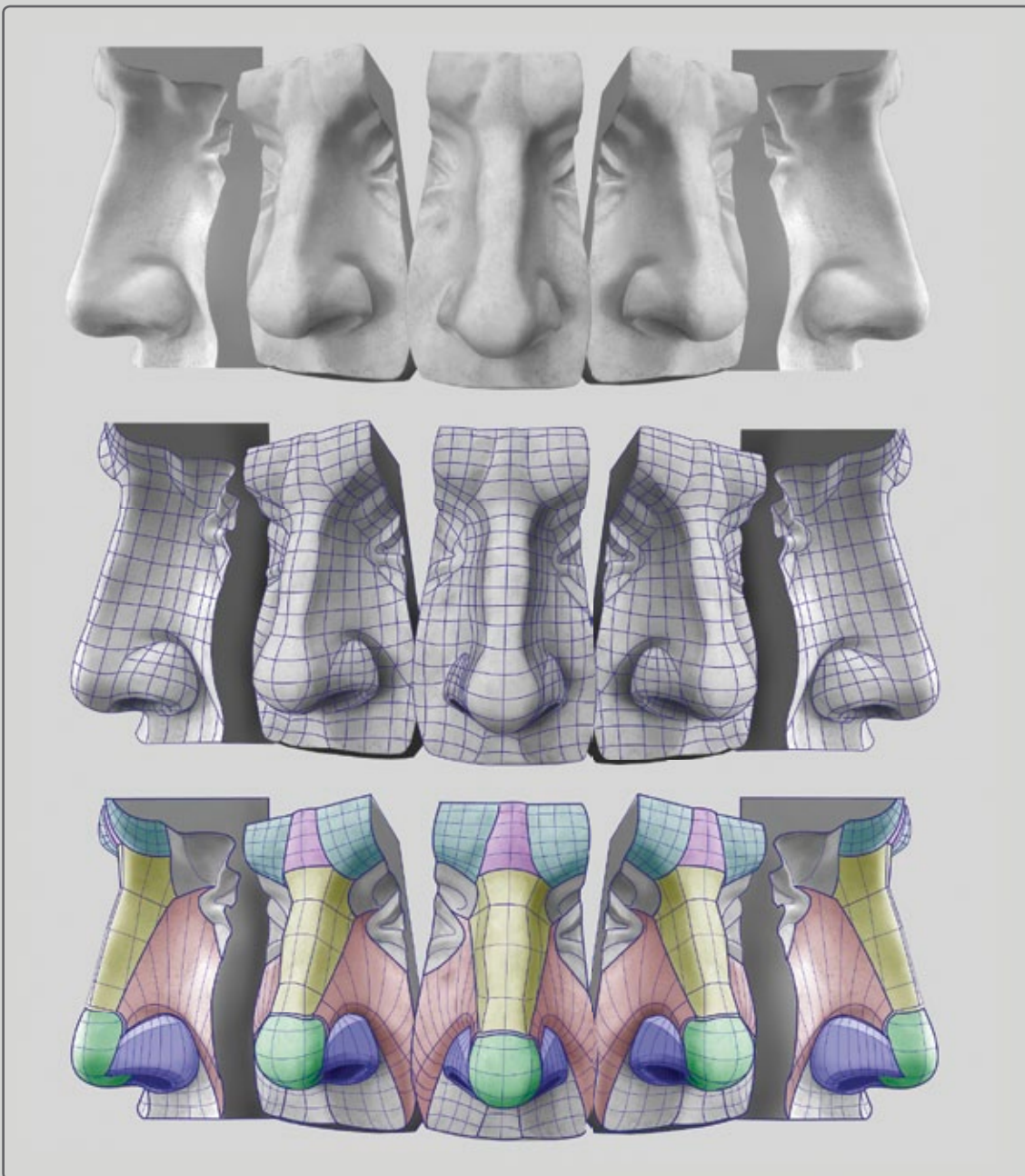

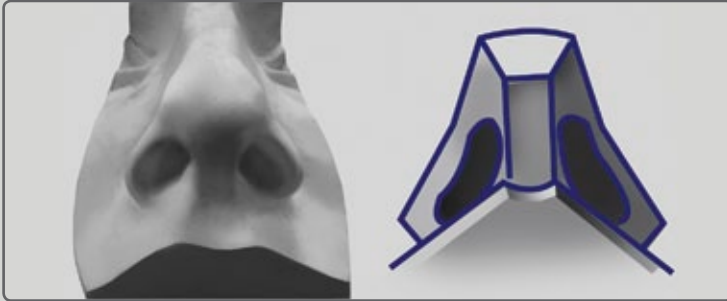
i

LOCATION & ORIENTATION

i



CLASSICAL NOSE



ALL ABOUT NOSES

NOSES CHANGE WITH AGE

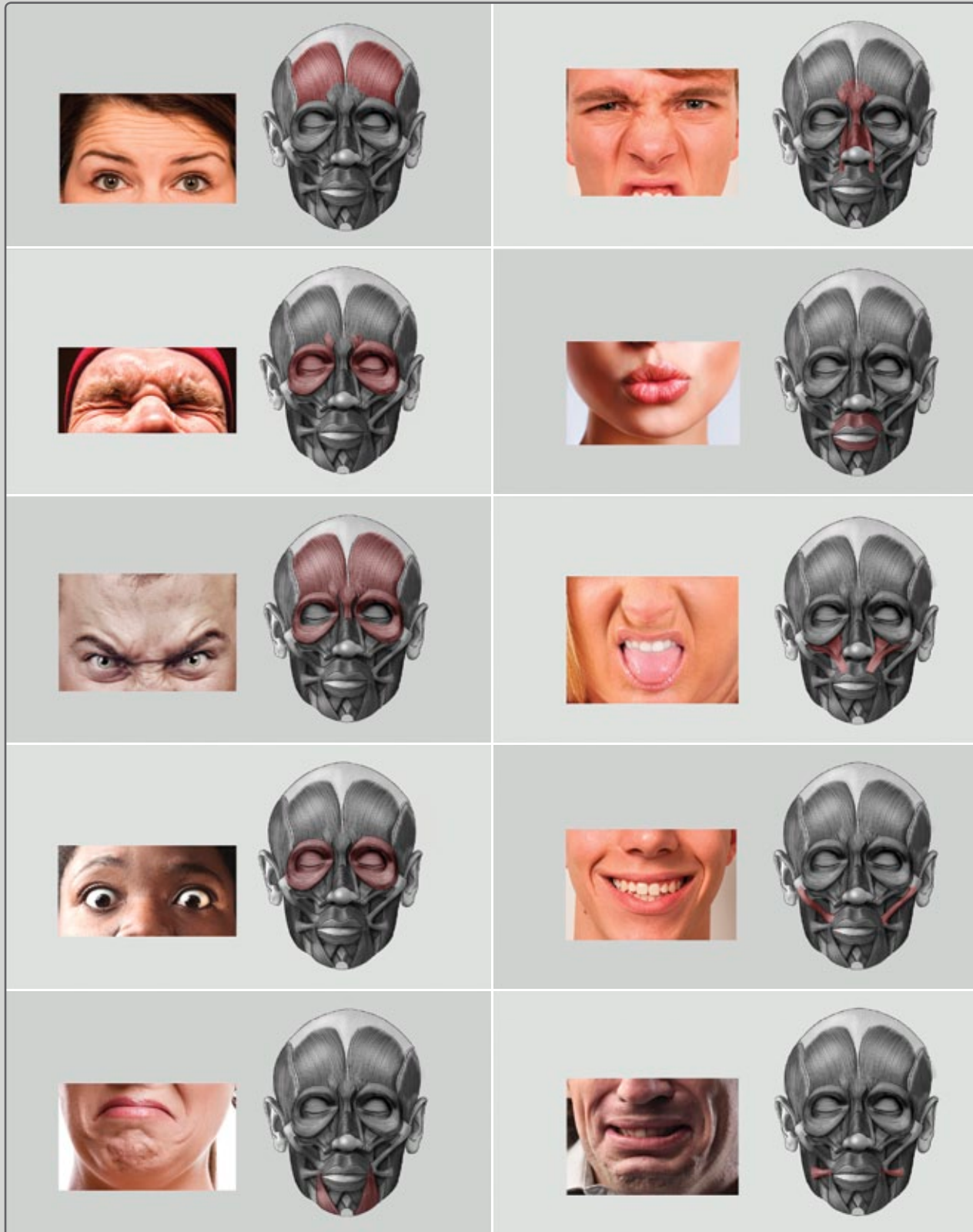
PARTS OF A NOSE

FEMALE VS. MALE NOSE

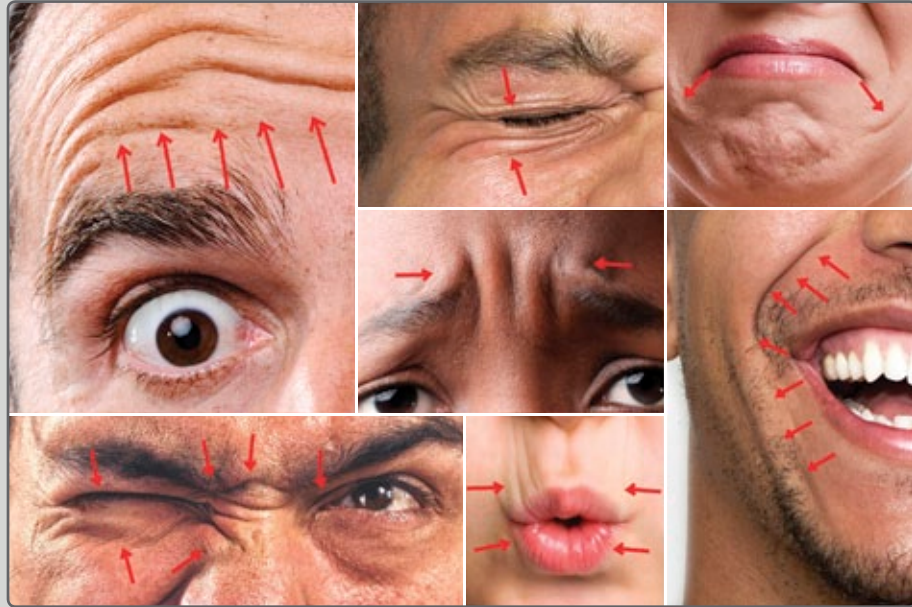IDEALISTIC NOSE

! TIPPING UP THE POINT OF THE NOSE WILL MAKE IT LOOK CHILD-LIKE. GIVING IT A CONCAVE OR THIN BRIDGE WILL MAKE IT LOOK MORE FEMININE!

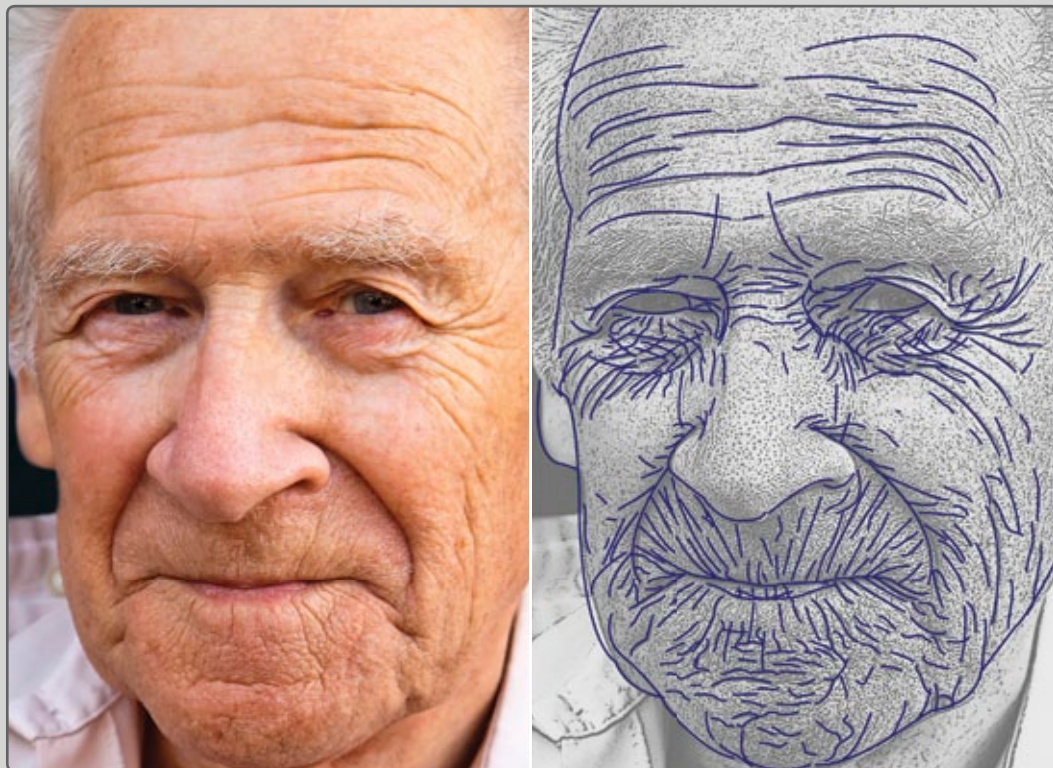
FUNCTIONS OF FACIAL MUSCLES



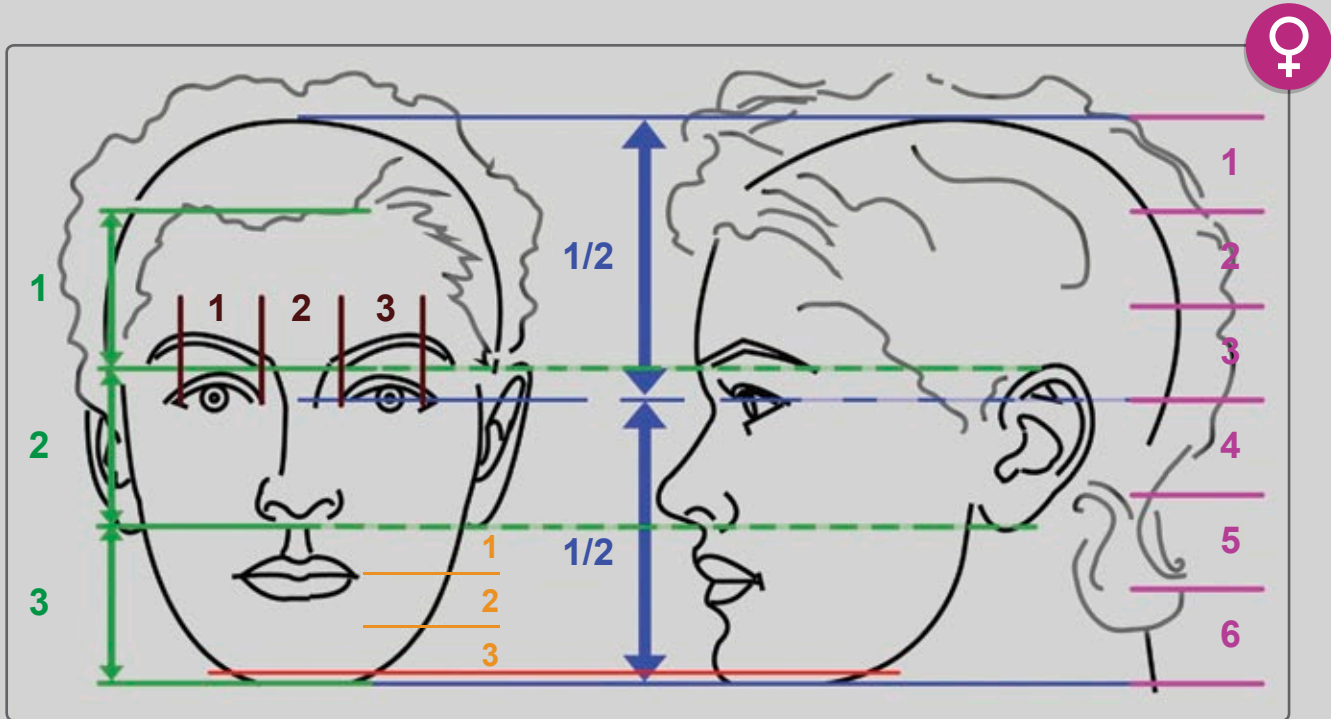
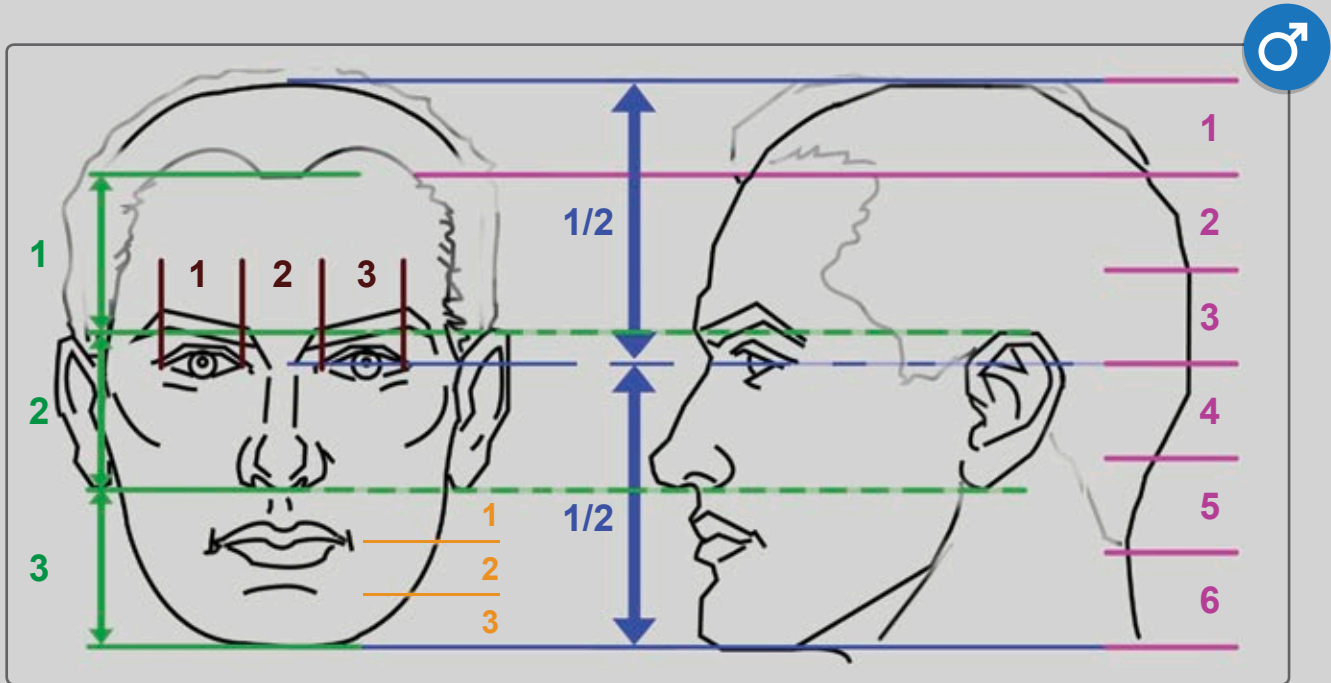
DYNAMIC WRINKLES



AGING WRINKLES

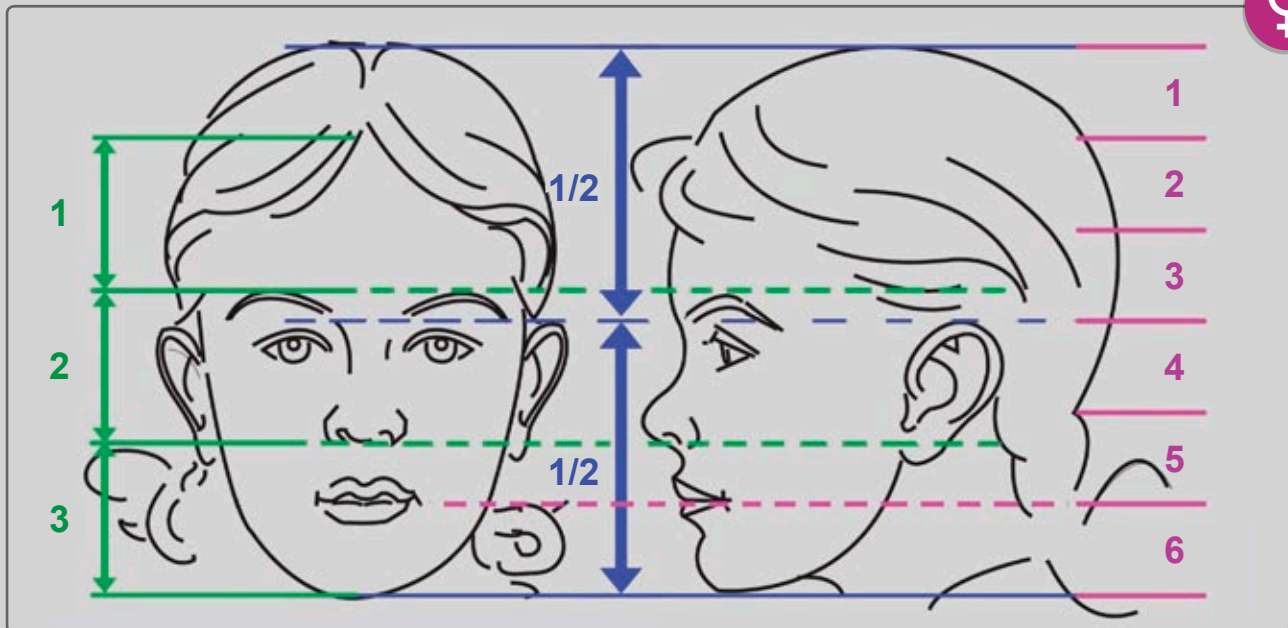
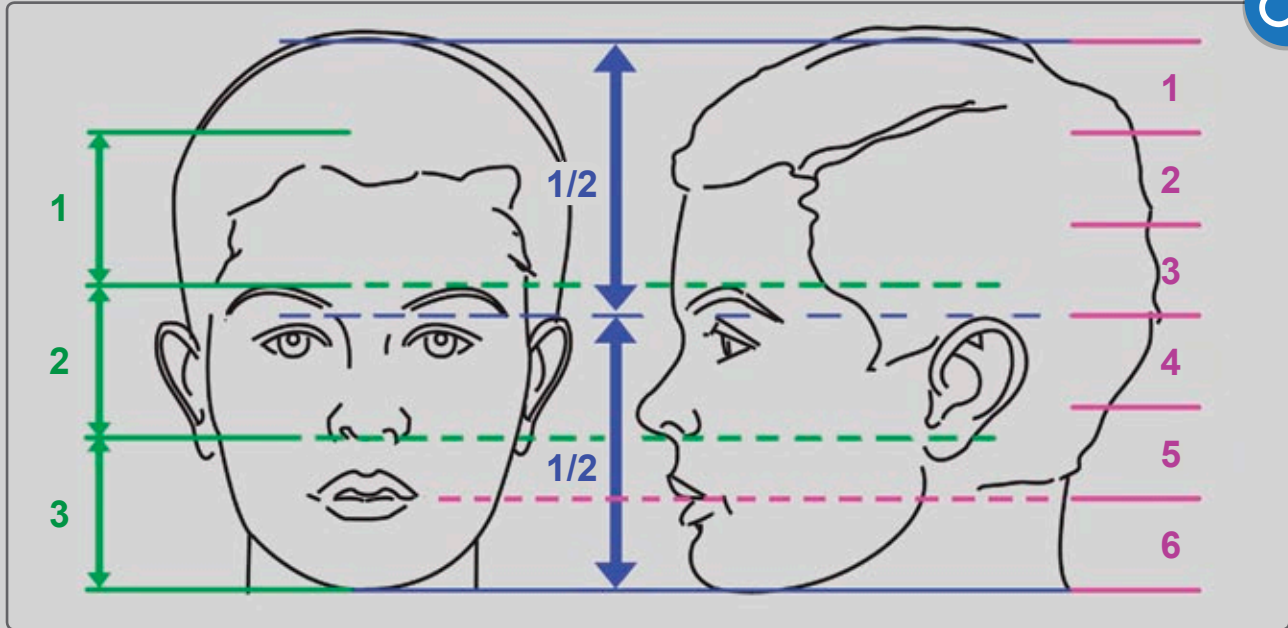


IDEALIZED PROPORTIONS OF ADULT HEADS

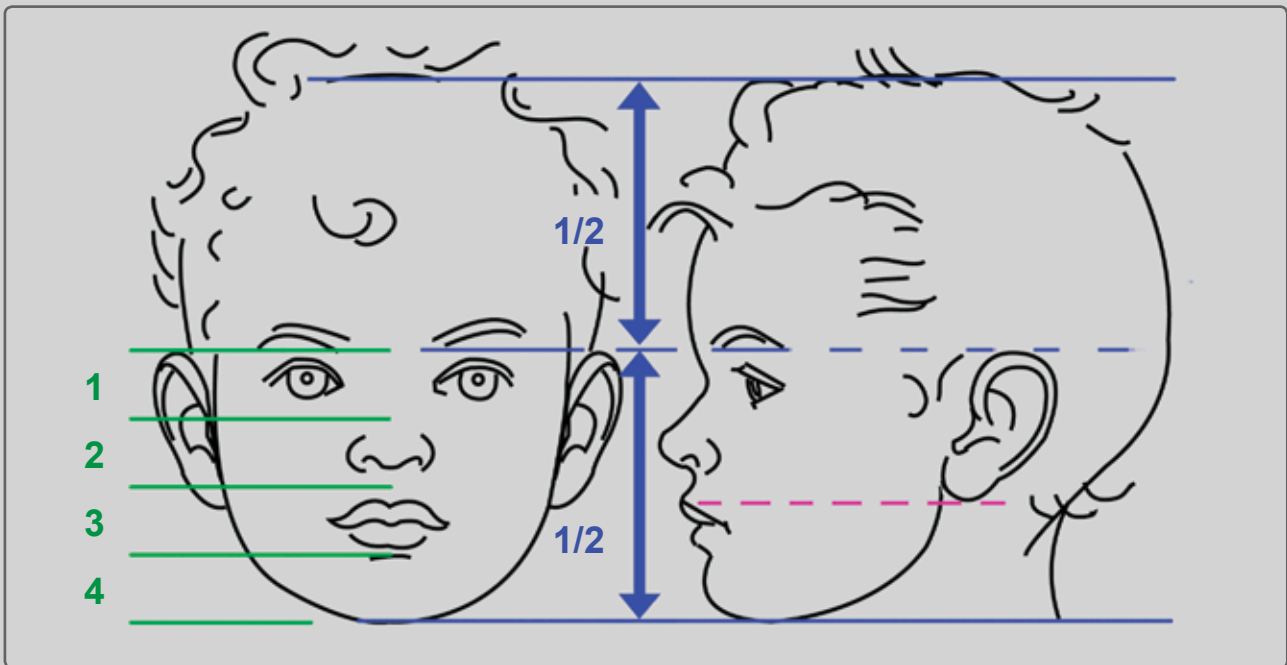
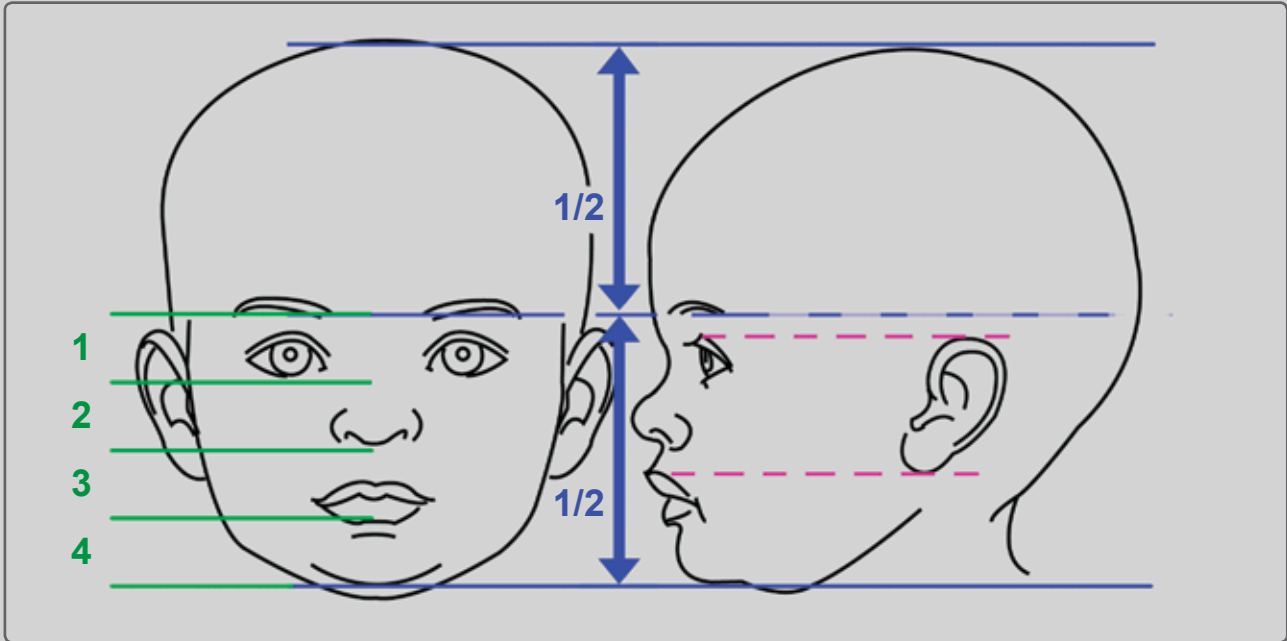


! FEMALES HAVE A SLIGHTLY THINNER CHIN AND JAW.

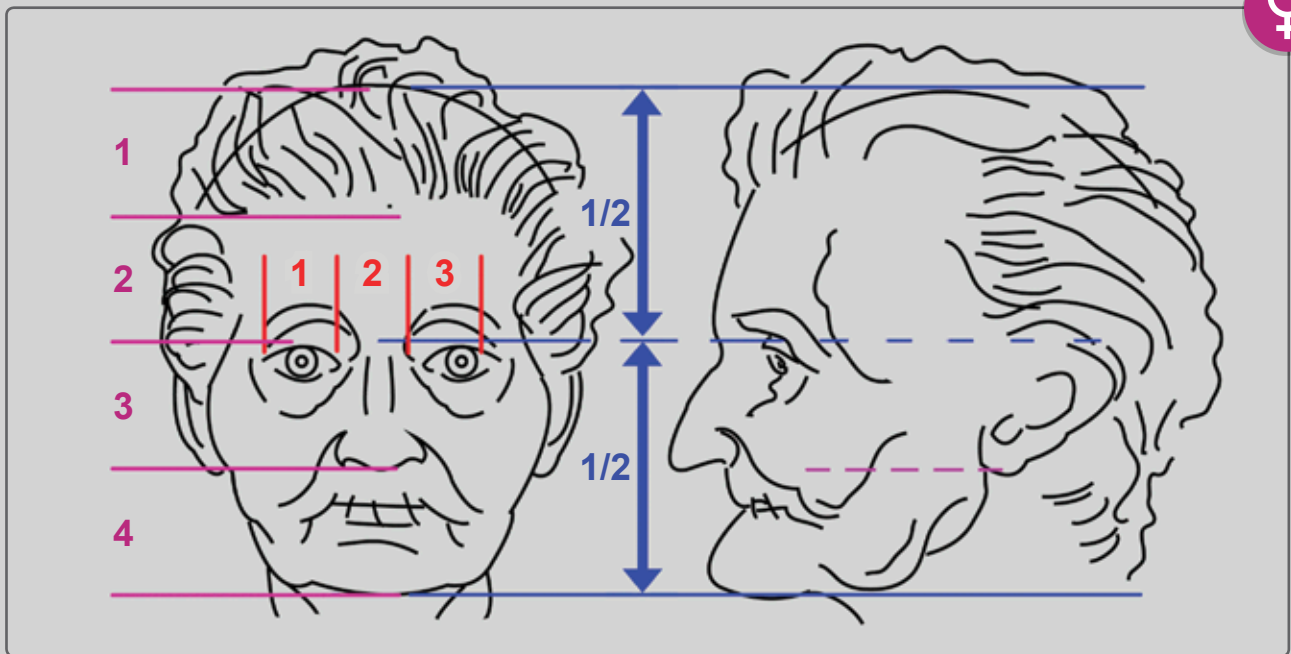
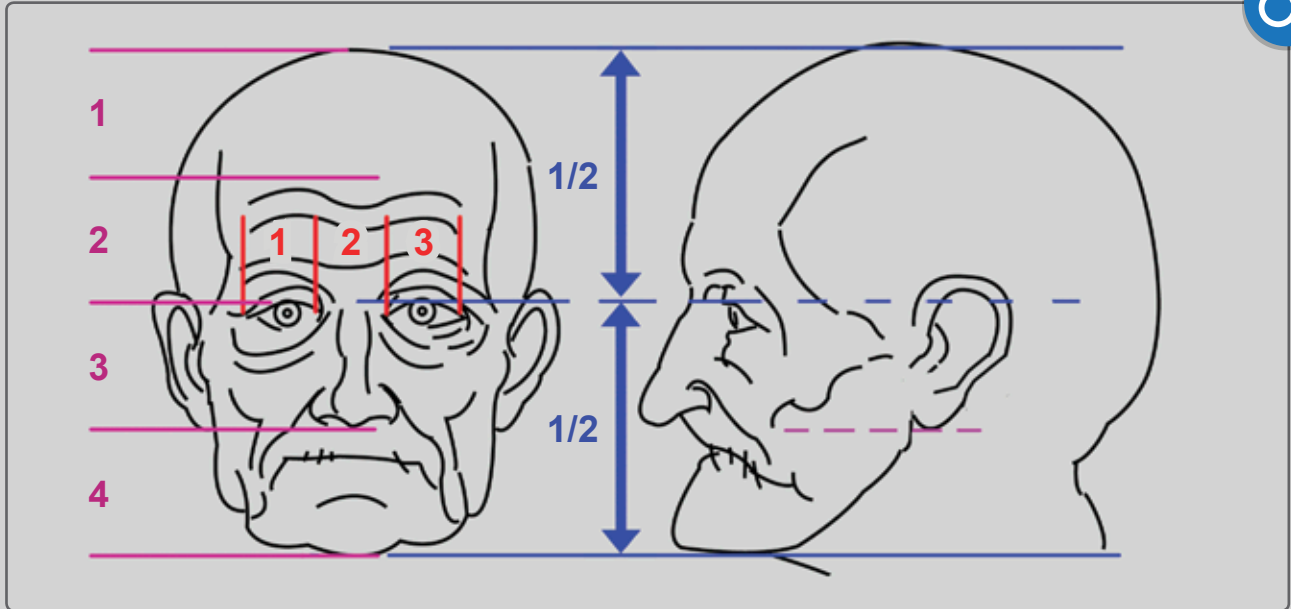
PROPORTIONS OF CHILDREN'S HEADS



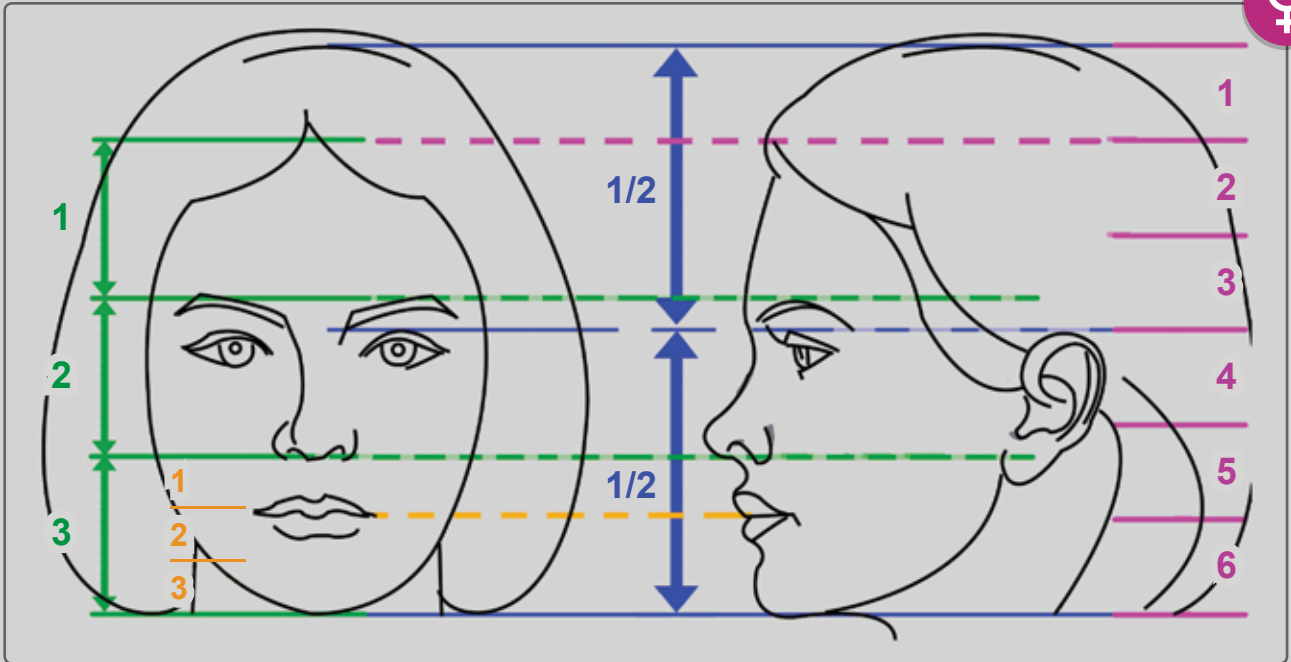
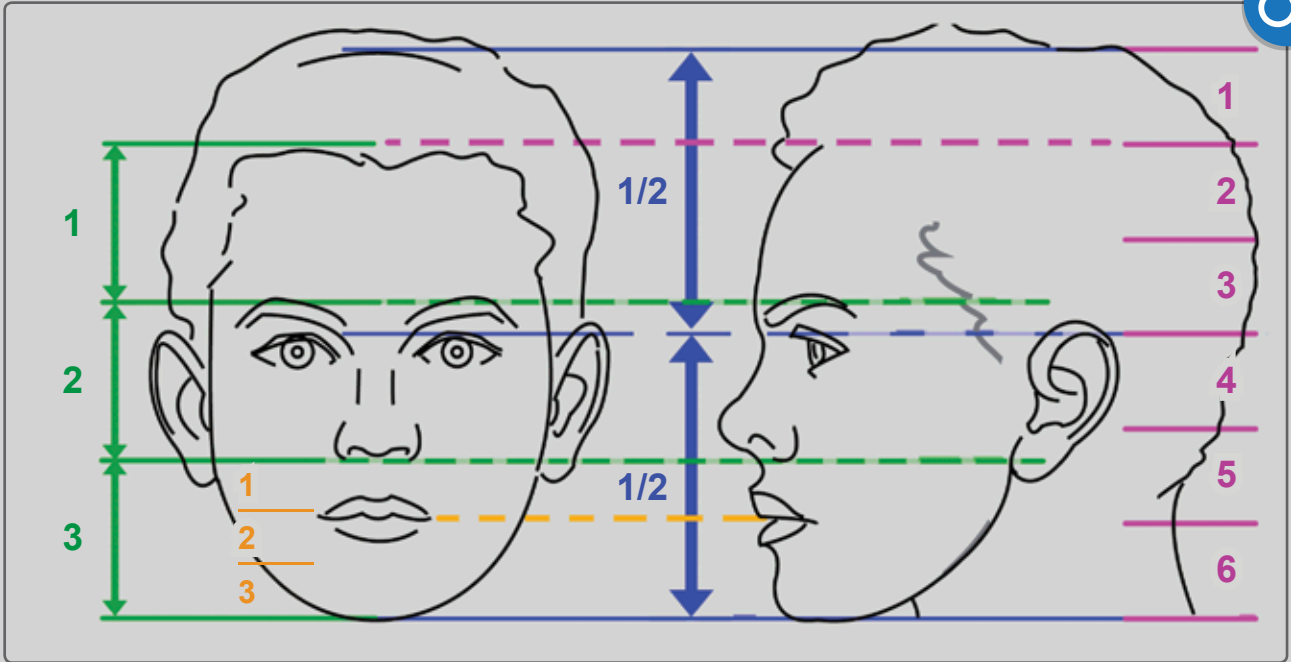
PROPORTIONS OF BABY AND TODDLER HEADS



PROPORTIONS OF ELDERLY HEADS



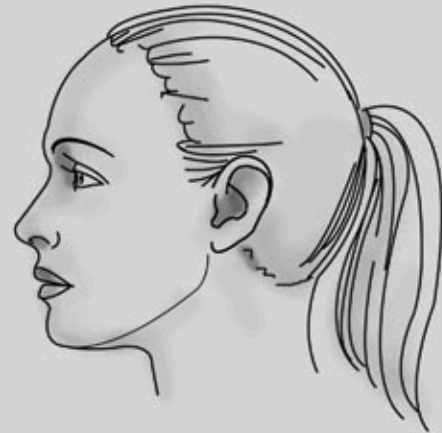PROPORTIONS OF TEEN HEADS



GENDER DIFFERENCES BETWEEN IDEALIZED ADULT HEADS



- DISTINCT PROTRUDING **BROW RIDGES**
- **NOSE ROOT** IS USUALLY EXPRESSED CLEARLY AND CAN BE QUITE DEEP
- **PLANE OF FOREHEAD** HAS A SMALL SLOPE TOWARDS THE REAR, CONTOUR OF FOREHEAD IS NOT STRAIGHT BUT SOMEWHAT WAVY
- **CHEEKBONES** EXPRESSED CLEARLY
- BUSHY **EYEBROWS** STAND OUT, AS A RULE ARE LESS ARCHED SHAPE AND SIT LOWER OVER EYES
- **UPPER EYELID** IS NOT PARTICULARLY DISTINGUISHED AND IS LOCATED CLOSE TO EDGE OF THE INFRAORBITAL FORAMEN
- LONGER **NOSE** COMPARED TO A FEMALE
- UNDERLYING **THE NOSE** IS A CLEARLY VISIBLE BONE-SKELETAL STRUCTURE, IT IS USUALLY LARGE. FORM IS ALMOST STRAIGHT OR SLIGHTLY CONVEX.
- **NOSE** IS THICK AND BROAD
- BASE OF **NOSE** LIES ON A HORIZONTAL PLANE
- TIP OF **NOSE** IS LARGE AND ROUNDED
- FOLD CONTOUR OF **UPPER LIP** IS SLIGHTLY CONVEX
- CAUCASIAN MALE **LIPS** ARE NOT AS FULL AND PUFFY AS A FEMALE'S
- PROTRUDING **CHEEKBONES**
- **CHIN** IS MASSIVE, CLEARLY DEFINED, OFTEN DIMPLED
- **LOWER JAW'S** WIDEST CORNERS ARE MARKED CLEARLY AND SOMEWHAT SHIFTED LATERALLY (DUE TO DEVELOPED CHEWING MUSCLES)



- CLEARLY EXPRESSED **EYEBROWS**
- SMALLER **NOSE ANGLE**
- MORE VERTICAL, PROMINENT AND ROUNDER **PLANE OF FOREHEAD**
- PROTRUDING **CHEEKBONES**
- THIN **EYEBROWS** WITH AN ARCHED FORM, USUALLY MUCH HIGHER THAN THE EYES OF MALES
- LARGER **UPPER EYELID**
- DEEPENING OF **ROOT OF THE NOSE** IS ALMOST UNNOTICEABLE
- STRUCTURE OF **NOSE** IS THIN AND USUALLY STRAIGHT OR SLIGHTLY CONCAVE
- **NOSE**, THIN WELL-DEFINED
- **BASE OF NOSE** ON PLANE, TILTED SOMEWHAT UPWARD
- **TIP OF THE NOSE** CLEARLY EXPRESSED (DUE TO CARTILAGE STRUCTURE)
- UPPER LIP OFTEN HAS A SLIGHT INDENTATION CENTERED UNDER THE NOSE CALLED THE PHILTRUM
- **LIPS** ARE SMALL, OFTEN FULL AND POUTY
- **CHEEKS** ARE SMOOTH, AND SOMETIMES PUBESCENT, FLAT OR SLIGHTLY CONVEX
- A SMALL **CHIN** WITH A ROUND SHAPE
- **LOWER JAW** IS MARKEDLY DEFINED, WITH A ROUNDED ANGLE
- IN RELATION TO THE SIZE OF HEAD AND SHOULDERS, WOMEN HAVE A LONG, SLENDER **NECK**

EMOTION – EXCITEMENT



EMOTION – HAPPINESS



EMOTION – ANGER



EMOTION – SURPRISE



EMOTION – DISGUST



EMOTION – FEAR



EMOTION – INTEREST



EMOTION – WORRY



ETHNICITIES



BABY EMOTIONS

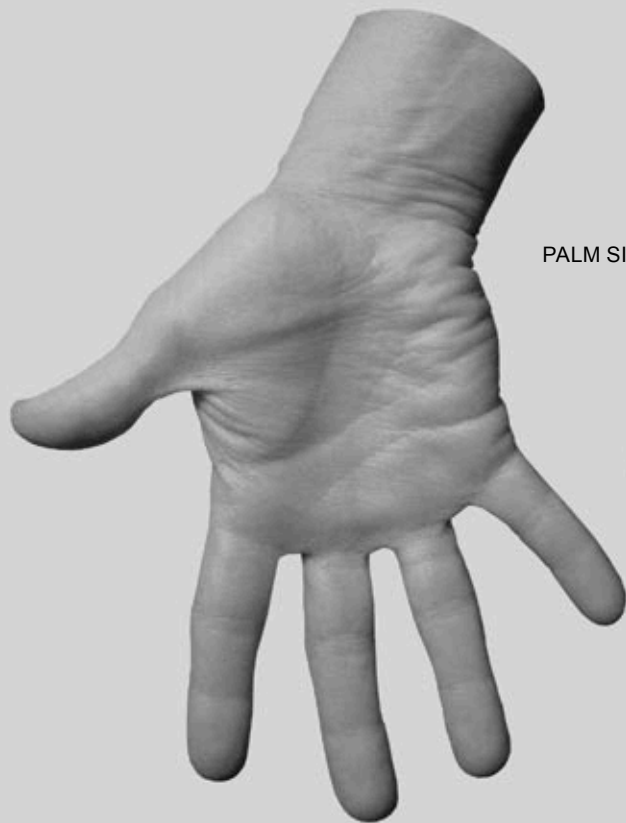

SENIOR EMOTIONS

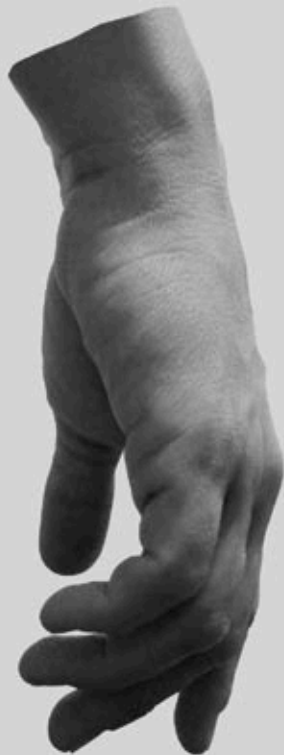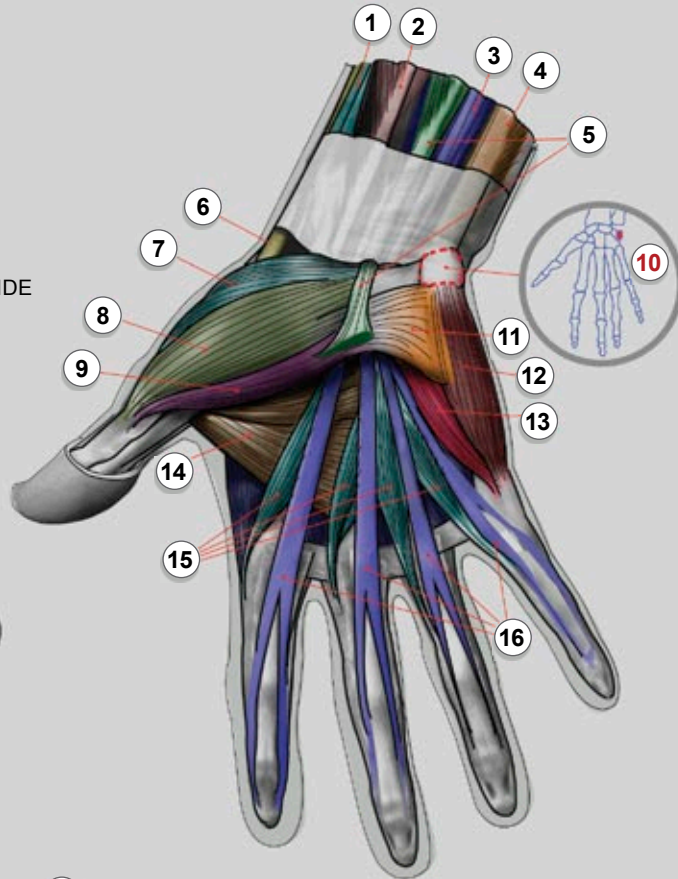




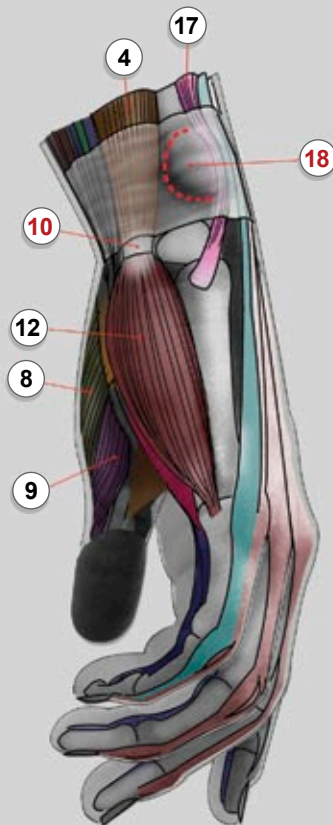
HAND AND WRIST MUSCLES



PALM SIDE



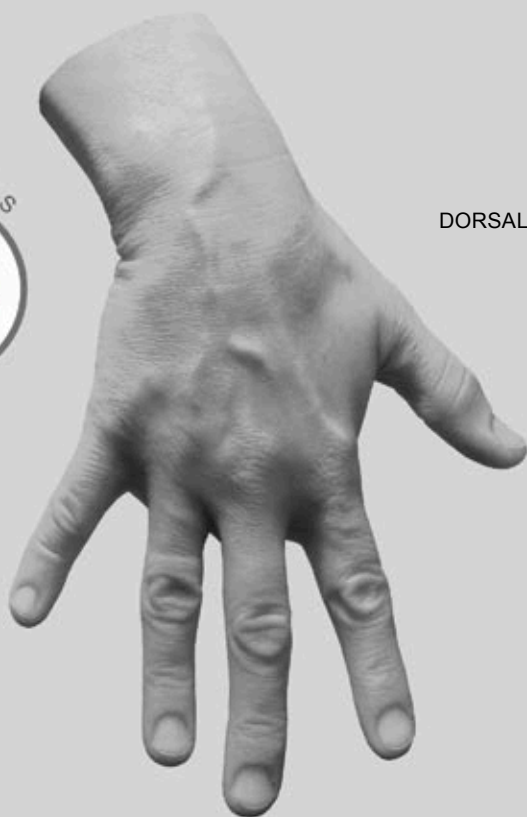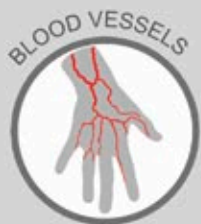LITTLE FINGER SIDE



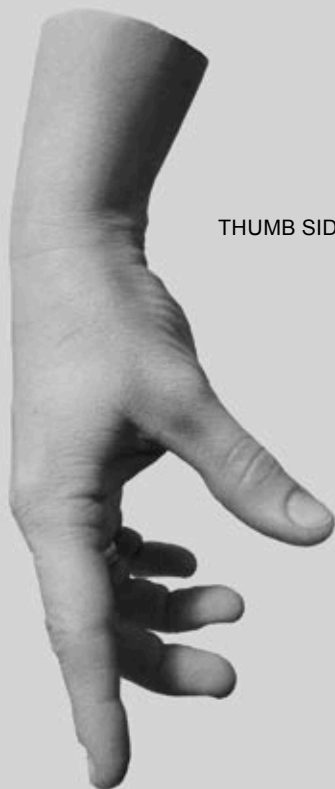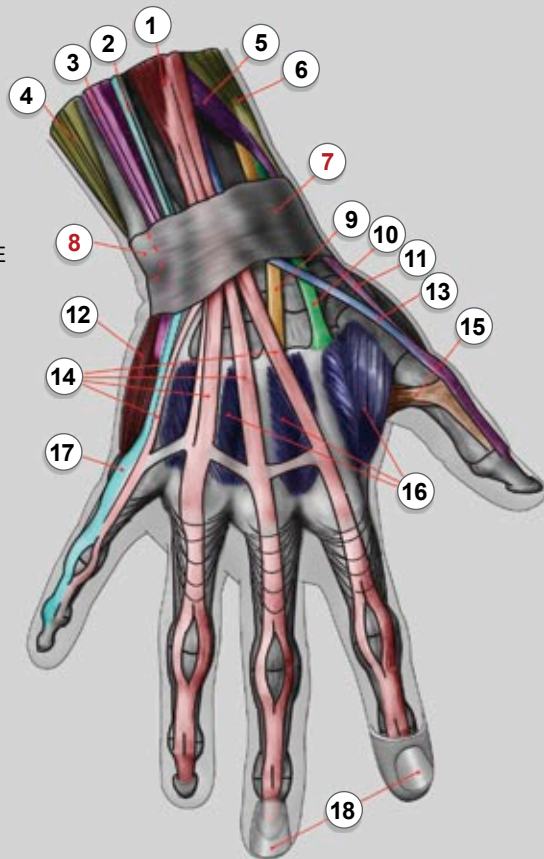
- 1 BRACHIORADIALIS
- 2 FLEXOR CARPI RADIALIS
- 3 f.d.s.*
- 4 FLEXOR CARPI ULNARIS
- 5 PALMARIS LONGUS
- 6 ABDUCTOR POLLICIS LONGUS
- 7 OPONENS POLLICIS
- 8 ABDUCTOR POLLICIS BREVIS
- 9 FLEXOR POLLICIS BREVIS
- 10 PISIFORM BONE
- 11 PALMARIS BREVIS
- 12 ABDUCTOR DIGITI MINIMI
- 13 FLEXOR DIGITI MINIMI BREVIS
- 14 ADDUCTOR POLLICIS
- 15 LUMBRICALS
- 16 TENDONS OF f.d.s.*
- 17 EXTENSOR CARPI ULNARIS
- 18 THE HEAD OF THE ULNA

flexor digitorum superficialis *

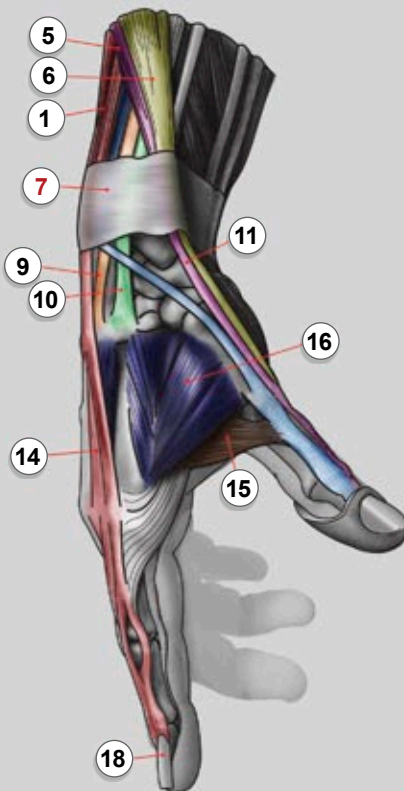
HAND AND WRIST MUSCLES



DORSAL SIDE



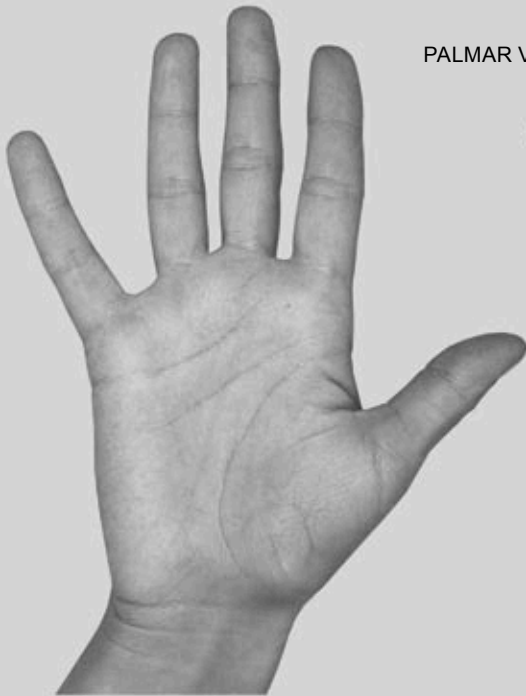
THUMB SIDE



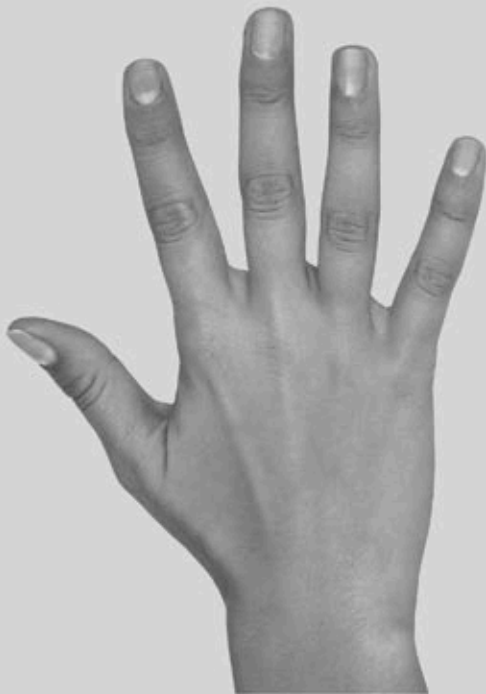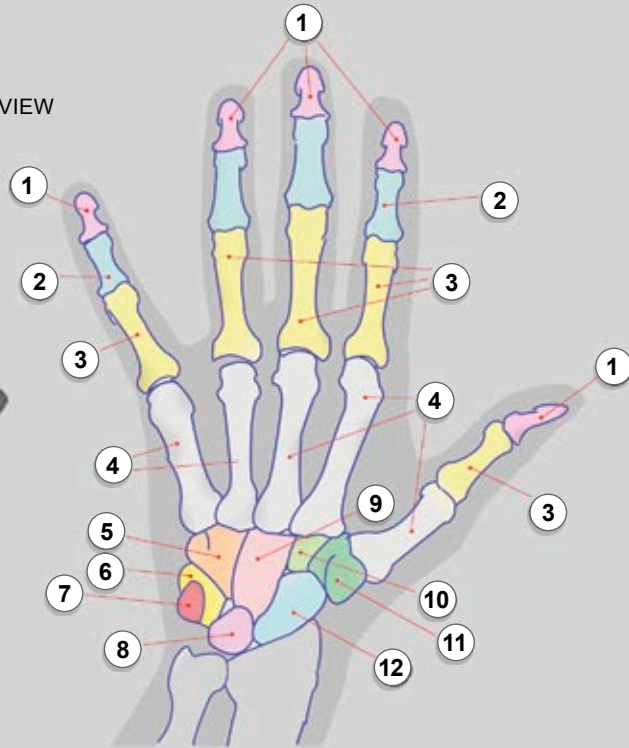
- 1 EXTENSOR DIGITORUM
- 2 EXTENSOR DIGITI MINIMI
- 3 EXTENSOR CARPI ULNARIS
- 4 FLEXOR CARPI ULNARIS
- 5 EXTENSOR POLLICIS BREVIS
- 6 ABDUCTOR POLLICIS LONGUS
- 7 EXTENSOR RETINACULUM
- 8 **THE HEAD OF THE ULNA BONE**
- 9 TENDON OF e.c.r.b.*
- 10 TENDON OF e.c.r.l.**
- 11 TENDON OF e.p.b.***
- 12 ABDUCTOR DIGITI MINIMI
- 13 TENDON OF e.p.l.****
- 14 TENDONS OF e.d.*****
- 15 ADDUCTOR POLLICIS
- 16 DORSAL INTEROSSEI MUSCLES
- 17 EXTENSOR OF e.d.m.*****
- 18 NAIL

extensor carpi radialis brevis *
 extensor carpi radialis longus **
 extensor pollicis brevis ***
 extensor pollicis longus ****
 extensor digitorum *****
 extensor digiti minimi *****

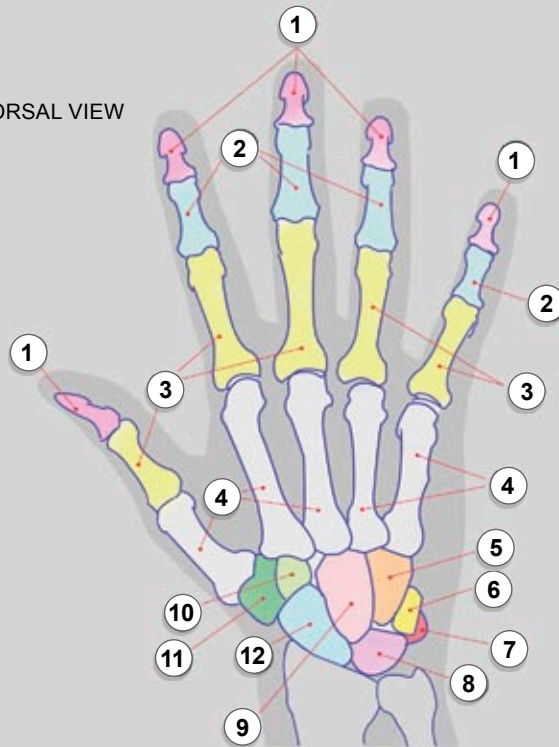HAND AND WRIST BONES



PALMAR VIEW

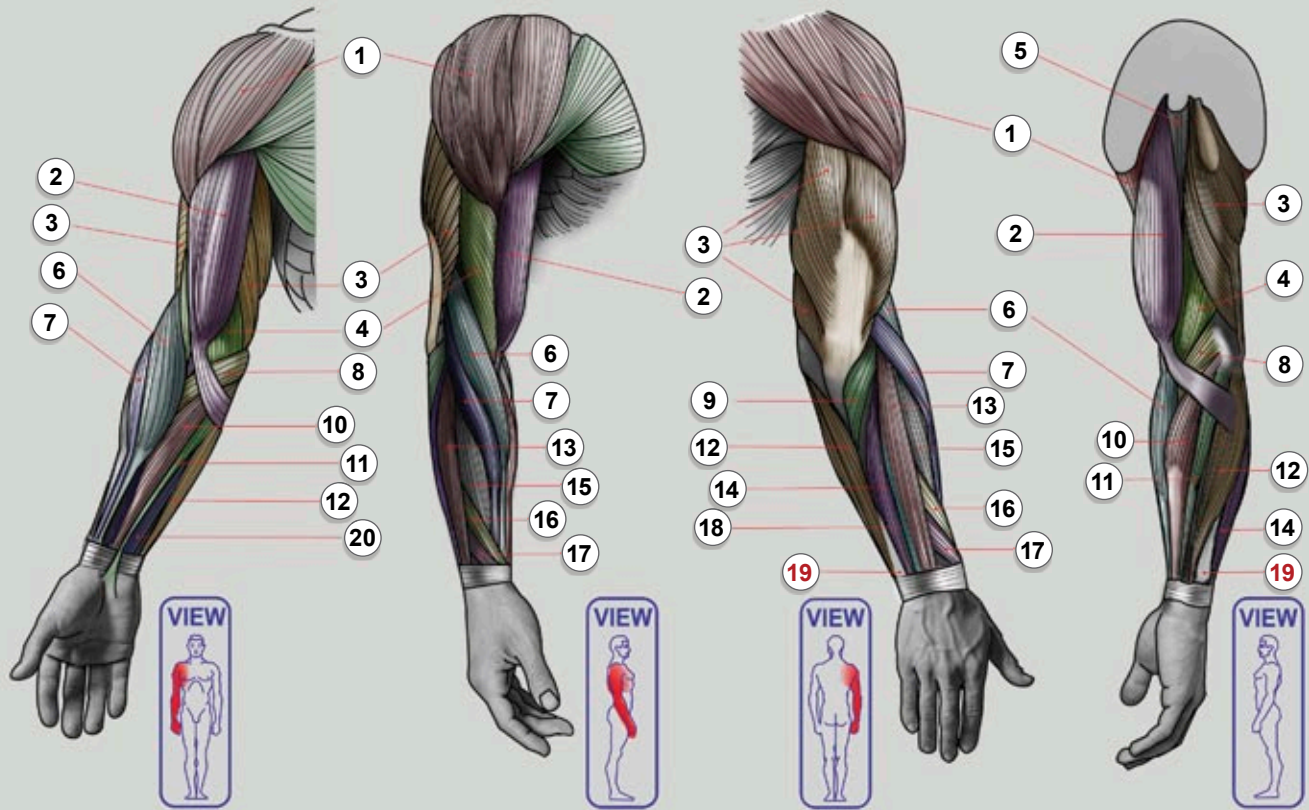


DORSAL VIEW



- | | | | |
|----------------------|---------------|------------|--------------|
| 1 DISTAL PHALANGES | 4 METACARPALS | 7 PISIFORM | 10 TRAPEZOID |
| 2 MIDDLE PHALANGES | 5 HAMATE | 8 LUNATE | 11 TRAPEZIUM |
| 3 PROXIMAL PHALANGES | 6 TRIQUETRUM | 9 CAPITATE | 12 SCAPHOID |

MAJOR MUSCLES OF UPPER LIMB



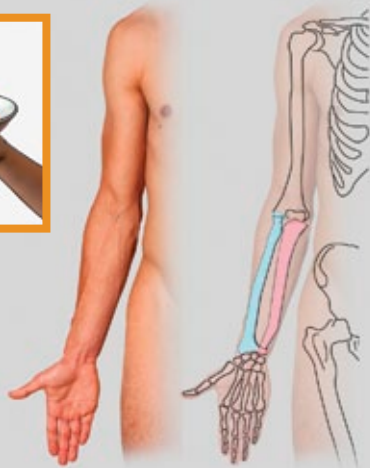- | | |
|----------------------------------|-----------------------------------|
| 1 SHOULDER MUSCLE (deltoid) | 11 PALMARIS LONGUS |
| 2 BICEPS BRACHII | 12 FLEXOR CARPI ULNARIS |
| 3 TRICEPS BRACHII | 13 EXTENSOR DIGITORUM |
| 4 BRACHIALIS | 14 EXTENSOR CARPI ULNARIS |
| 5 CORACOBRACHIALIS | 15 EXTENSOR CARPI RADIALIS BREVIS |
| 6 BRACHIORADIALIS | 16 ABDUCTOR POLLICIS LONGUS |
| 7 EXTENSOR CARPI RADIALIS LONGUS | 17 EXTENSOR POLLICIS BREVIS |
| 8 PRONATOR TERES | 18 EXTENSOR DIGITI MINIMI |
| 9 ANCONEUS | 19 THE HEAD OF ULNA BONE |
| 10 FLEXOR CARPI RADIALIS | 20 FLEXOR DIGITORUM SUPERFICIALIS |

SUPINATION AND PRONATION

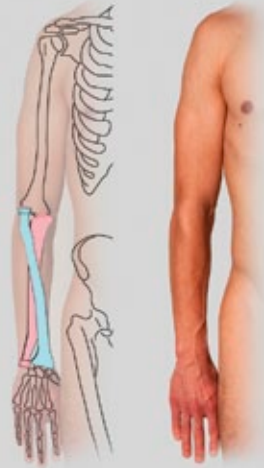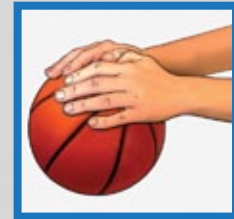i

IN THE POSITION OF THE ARM CALLED **SUPINATION**, THE **RADIUS** AND **ULNA** ARE PARALLEL, THE PALM OF THE HAND FACES FORWARD OR UPWARD, AND THE THUMB IS AWAY FROM THE BODY. IN THE POSITION CALLED **PRONATION**, THE **RADIUS** AND **ULNA** ARE CROSSED, THE PALM FACES TO THE REAR OR DOWNWARD, AND THE THUMB IS TOWARD THE BODY.

SUPINATION – LIKE YOU'RE A WAITER CARRYING SOUP.

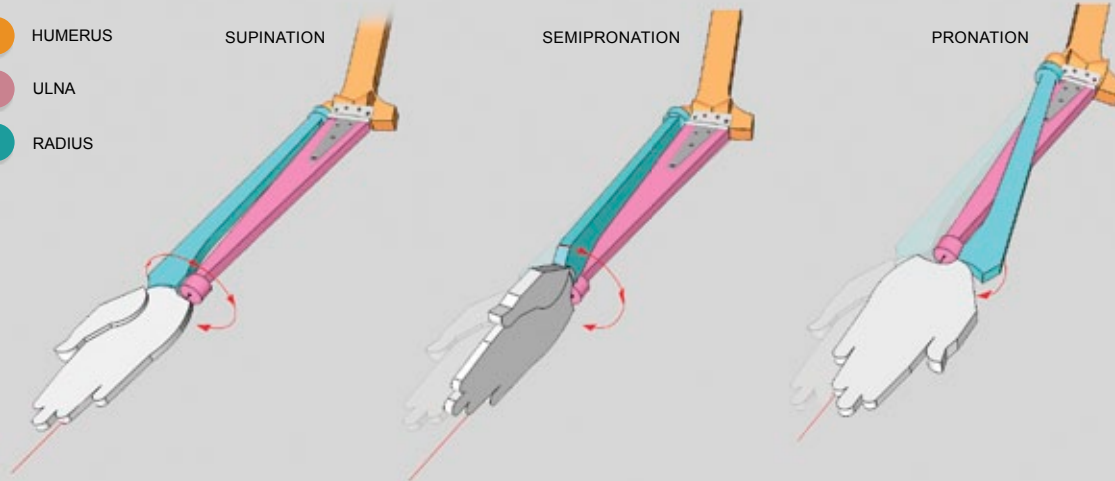


PRONATION – LIKE YOU'RE A PRO BASKETBALL PLAYER.



NOTE THAT PRONATION OF THE FOREARM DOES NOT INVOLVE ROTATION OF THE UPPER-ARM FROM THE SHOULDER JOINT!

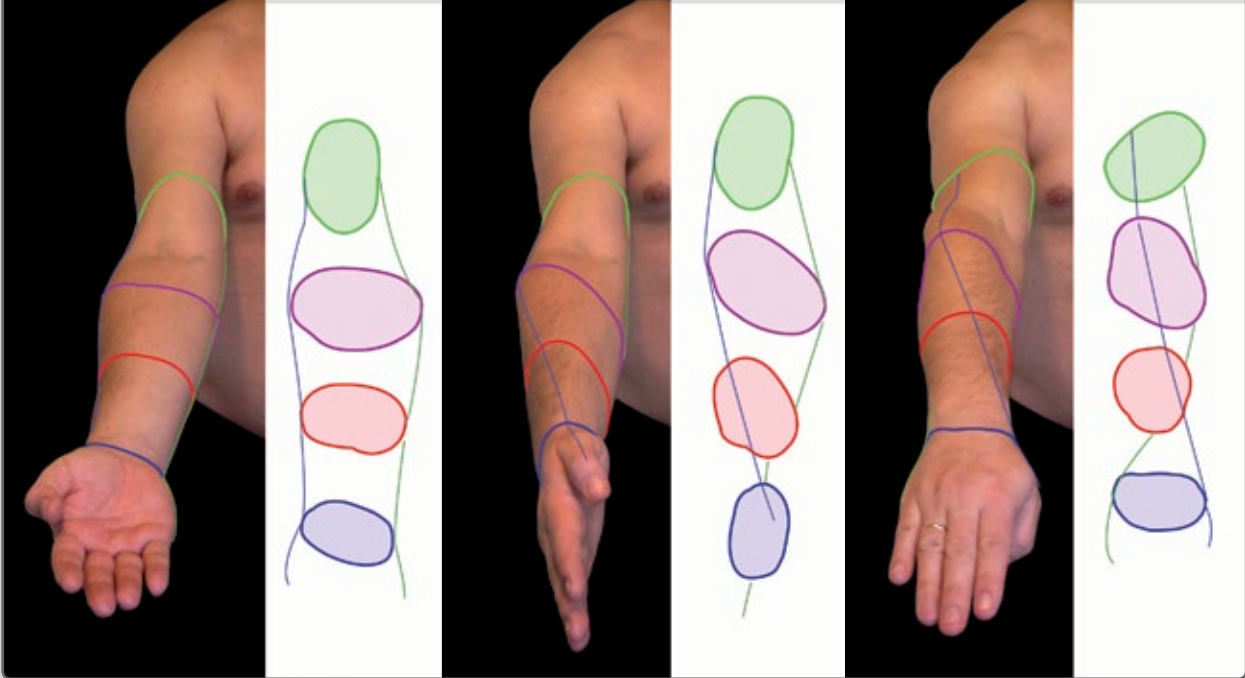
- HUMERUS
- ULNA
- RADIUS



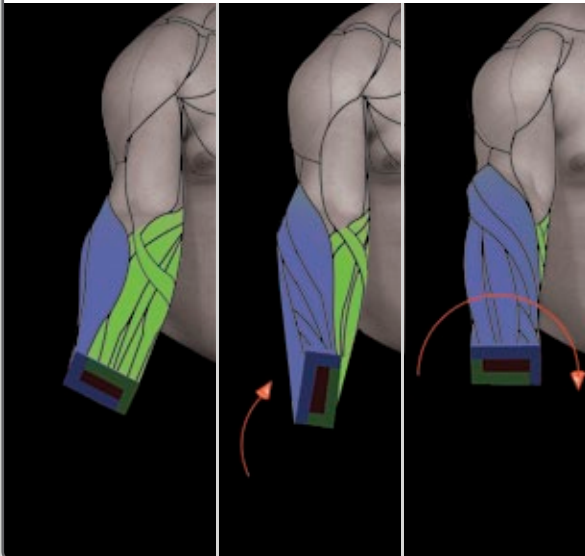
DURING **PRONATION**, **RADIUS** ROLLS AROUND **THE ULNA**

PRONATION AND FORM CHANGES

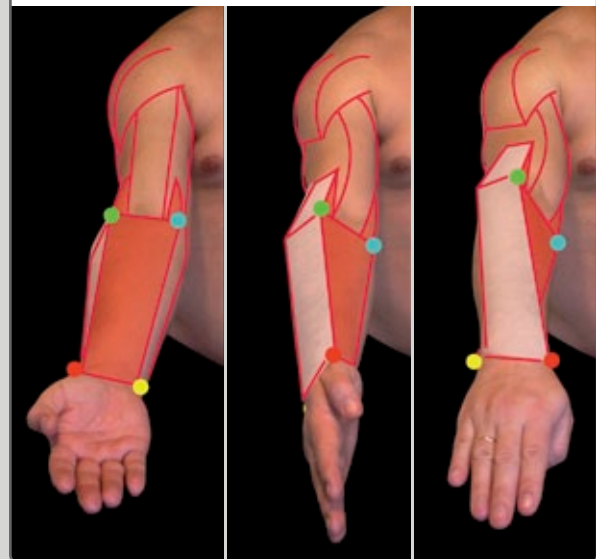
CROSS SECTIONS OF ARM DURING PRONATION



FLEXORS AND EXTENSORS



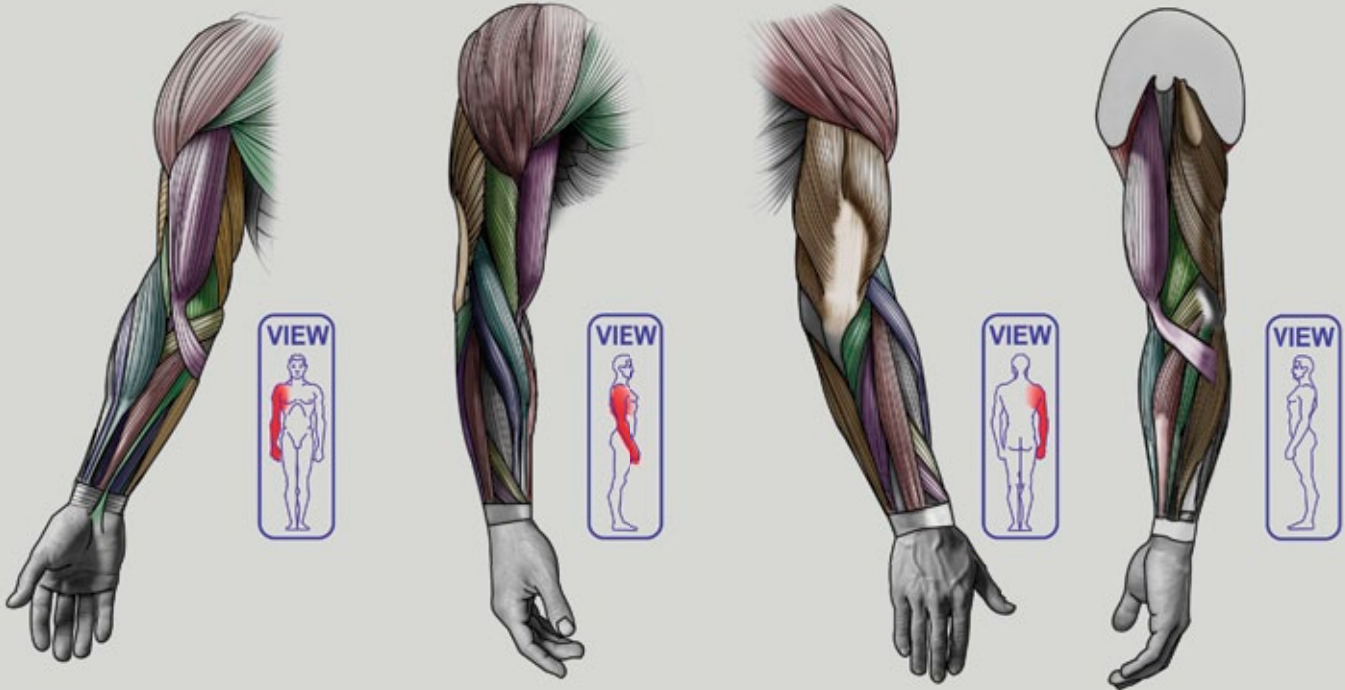
THIS IS AN EXAMPLE OF HOW IMPORTANT IT IS TO KNOW THE ORIGIN AND INSERTION POINTS OF MUSCLES.



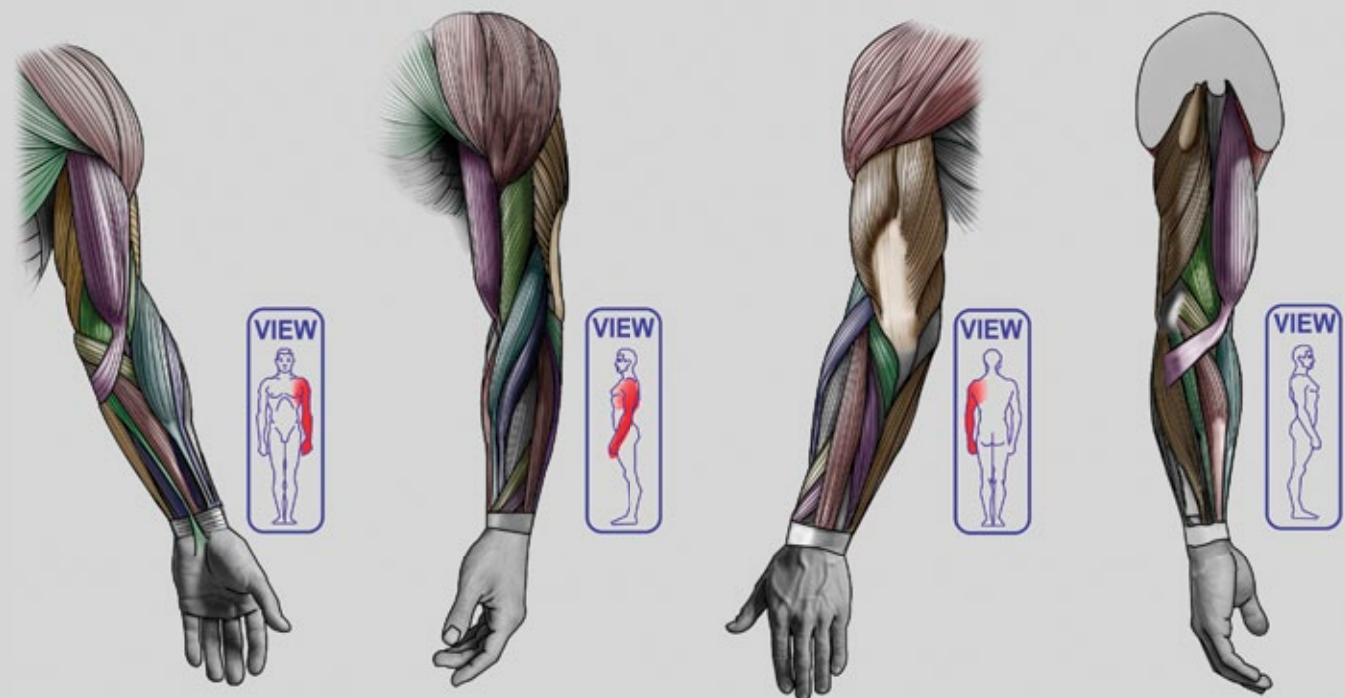
SUPINATED UPPER LIMB

(WHEN THE FOREARM OR PALM FACES TOWARD THE FRONT)

RIGHT

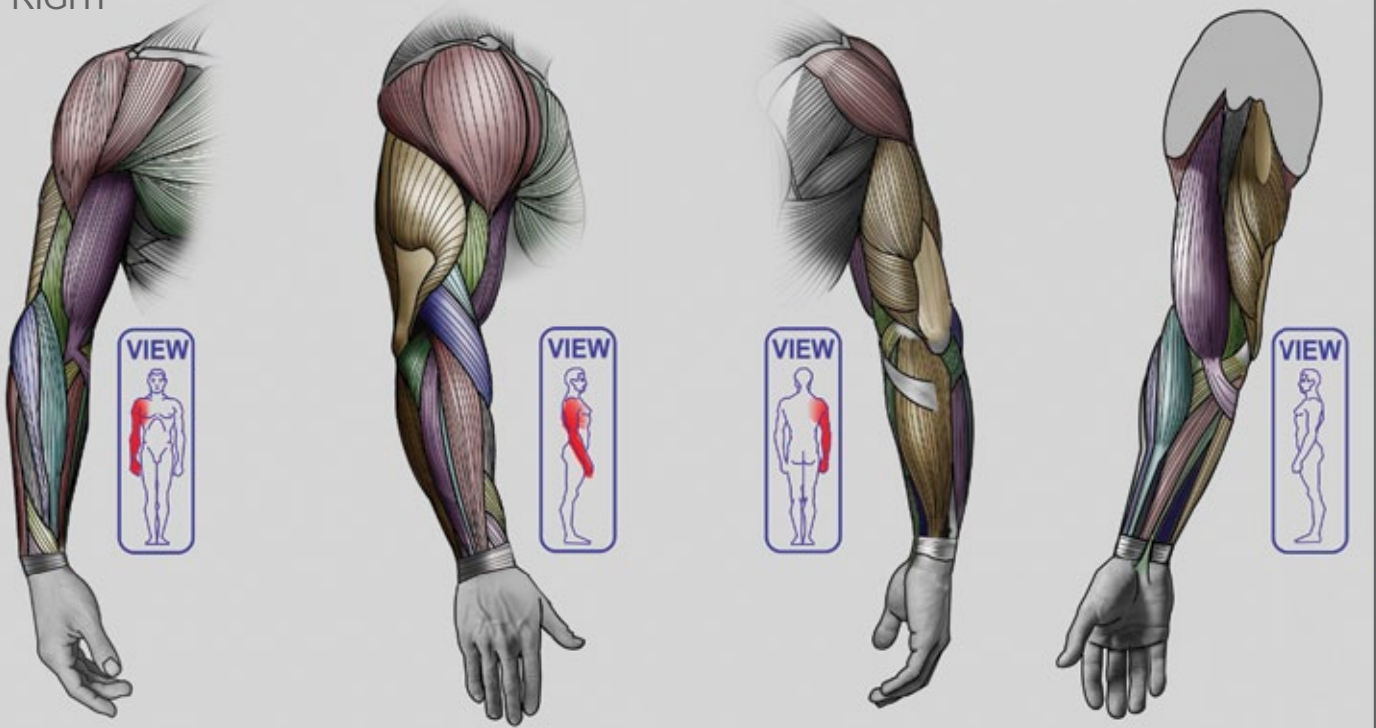


LEFT

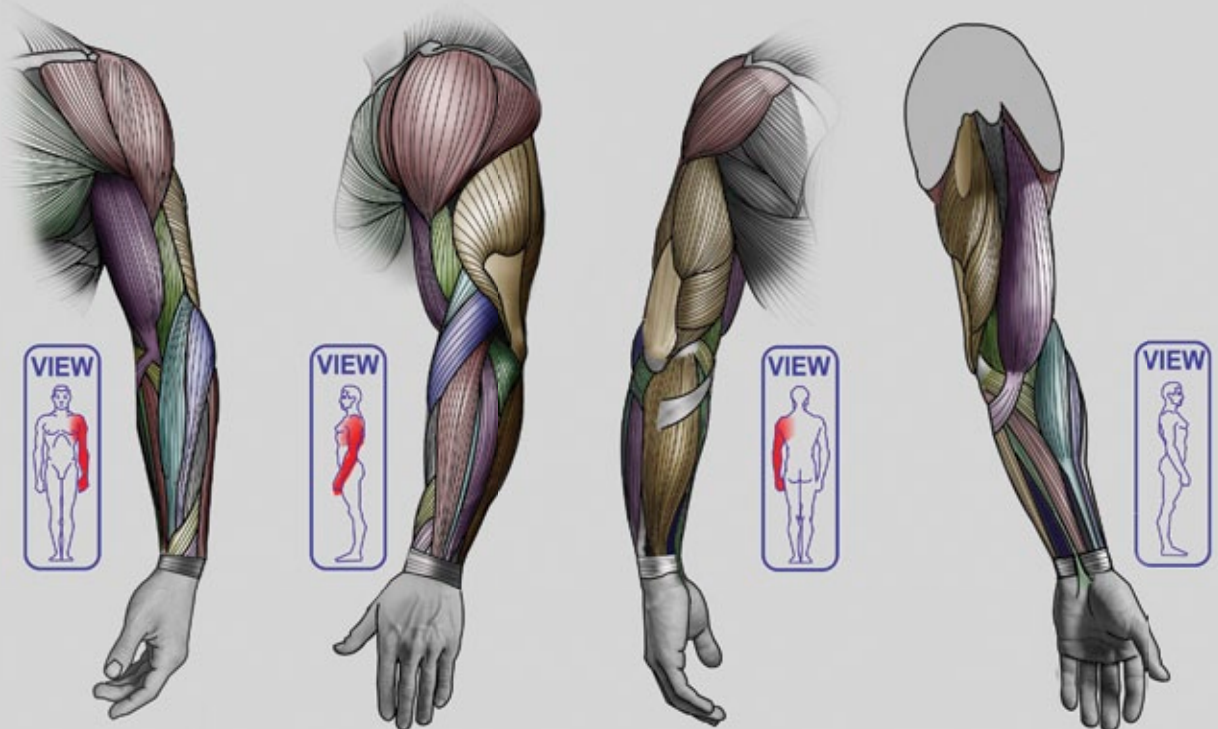


SEMPRONATED UPPER LIMB (WHEN THE FOREARM OR PALM FACES TOWARD THE TRUNK)

RIGHT

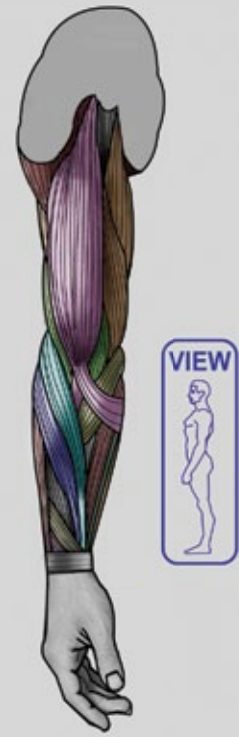
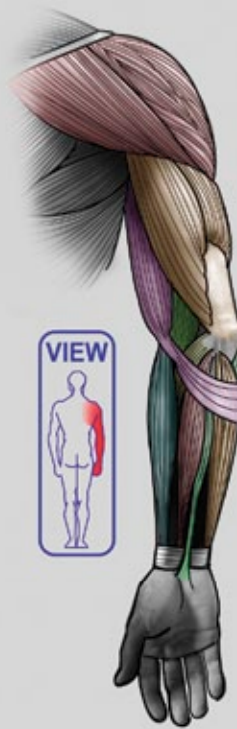
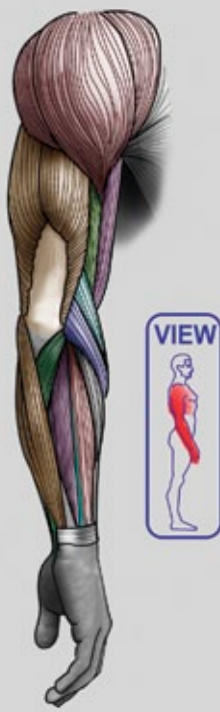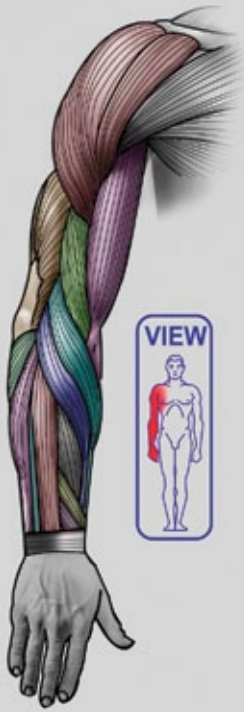LEFT

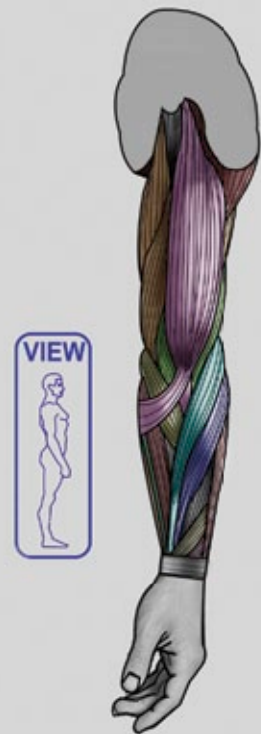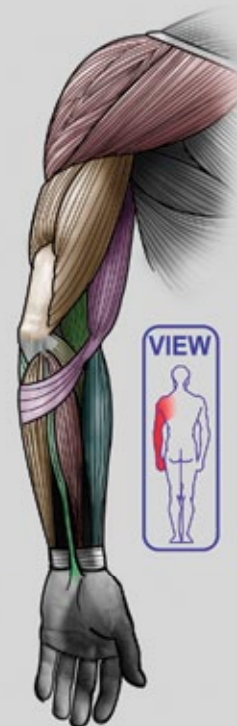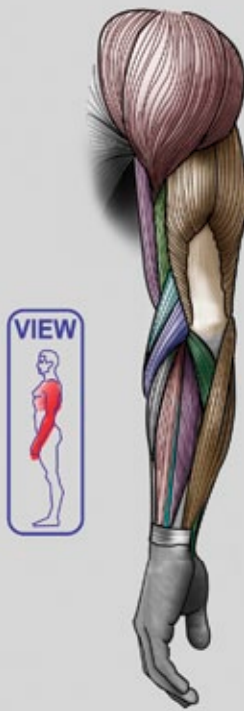
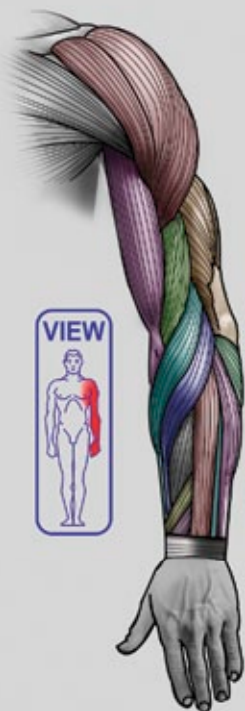


PRONATED UPPER LIMB (WHEN FOREARM OR PALM FACES TOWARD THE BACK)

RIGHT

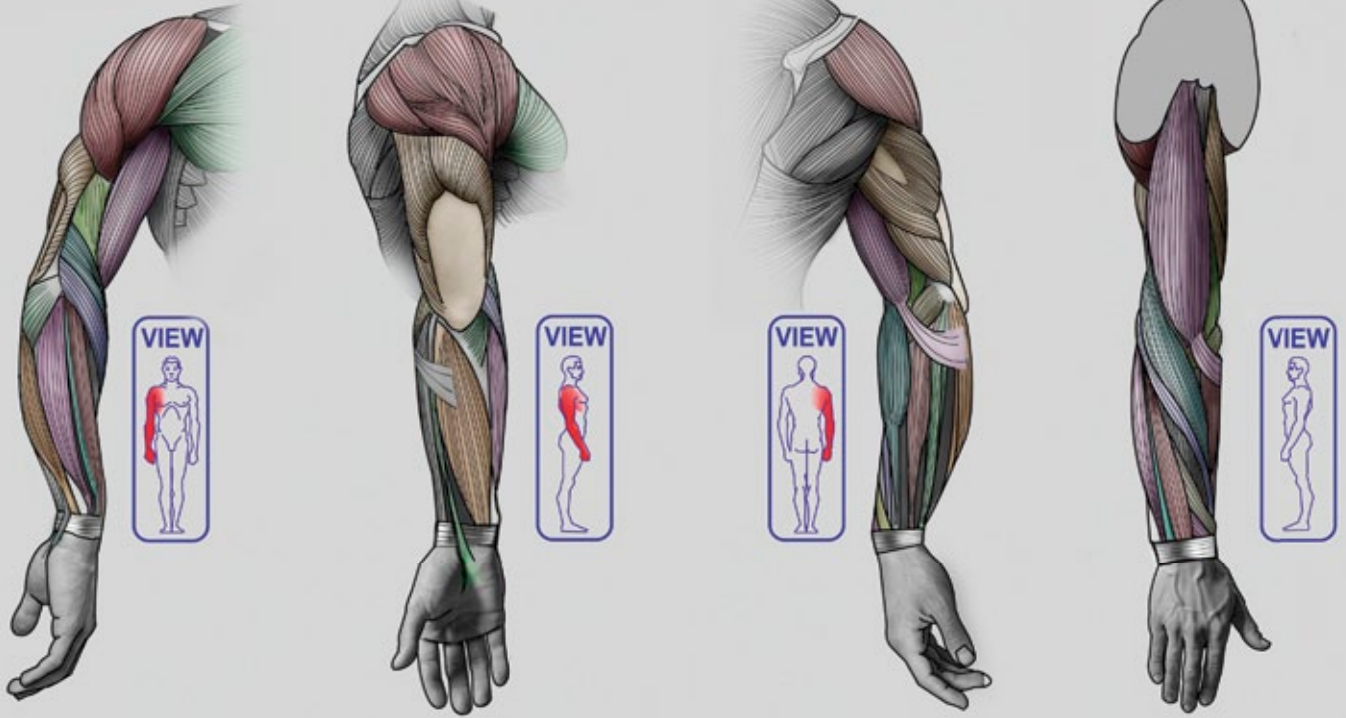


LEFT

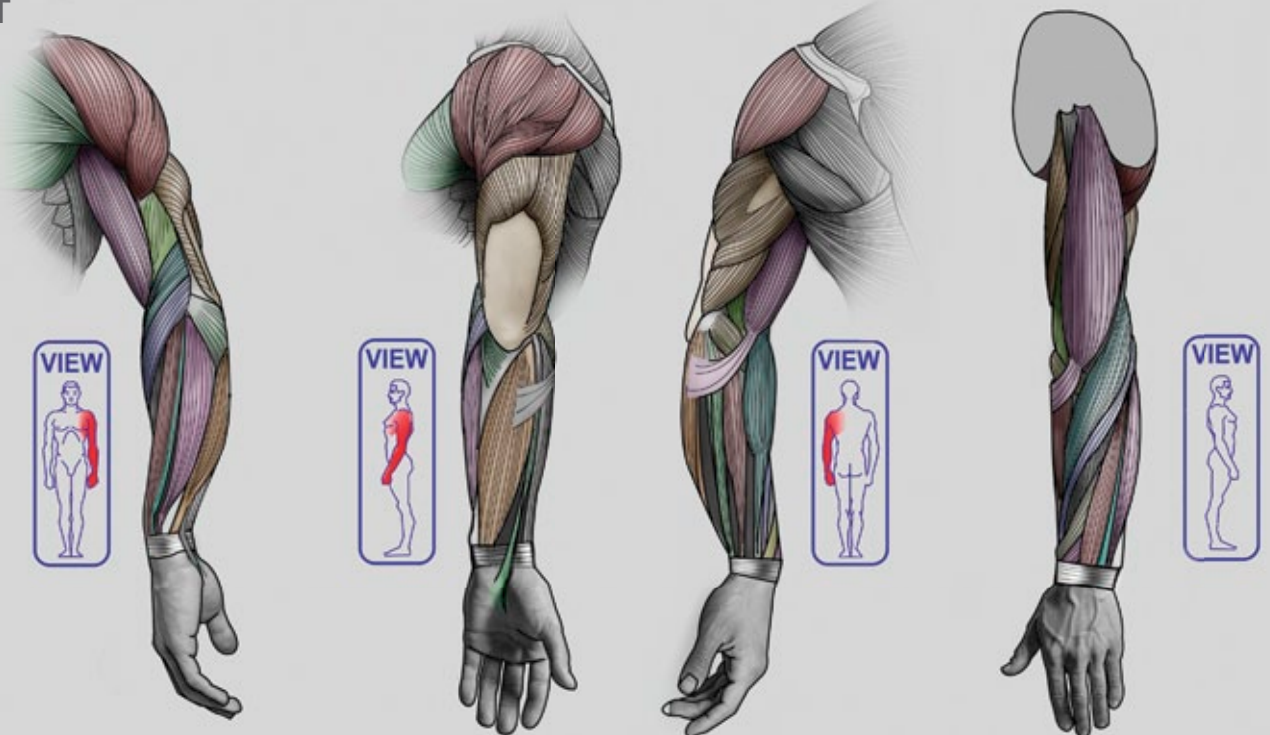


FORCED PRONATION OF THE UPPER LIMB (WHEN THE FOREARM OR PALM FACES AWAY FROM THE TRUNK)

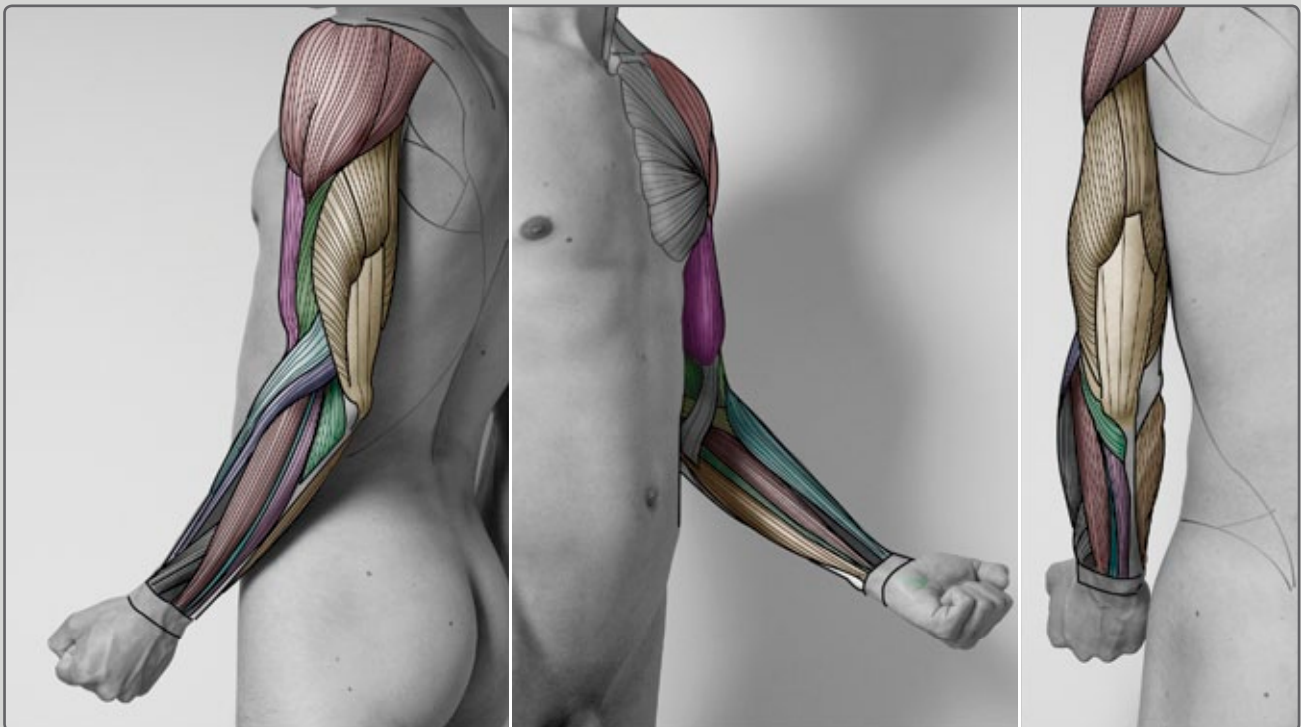
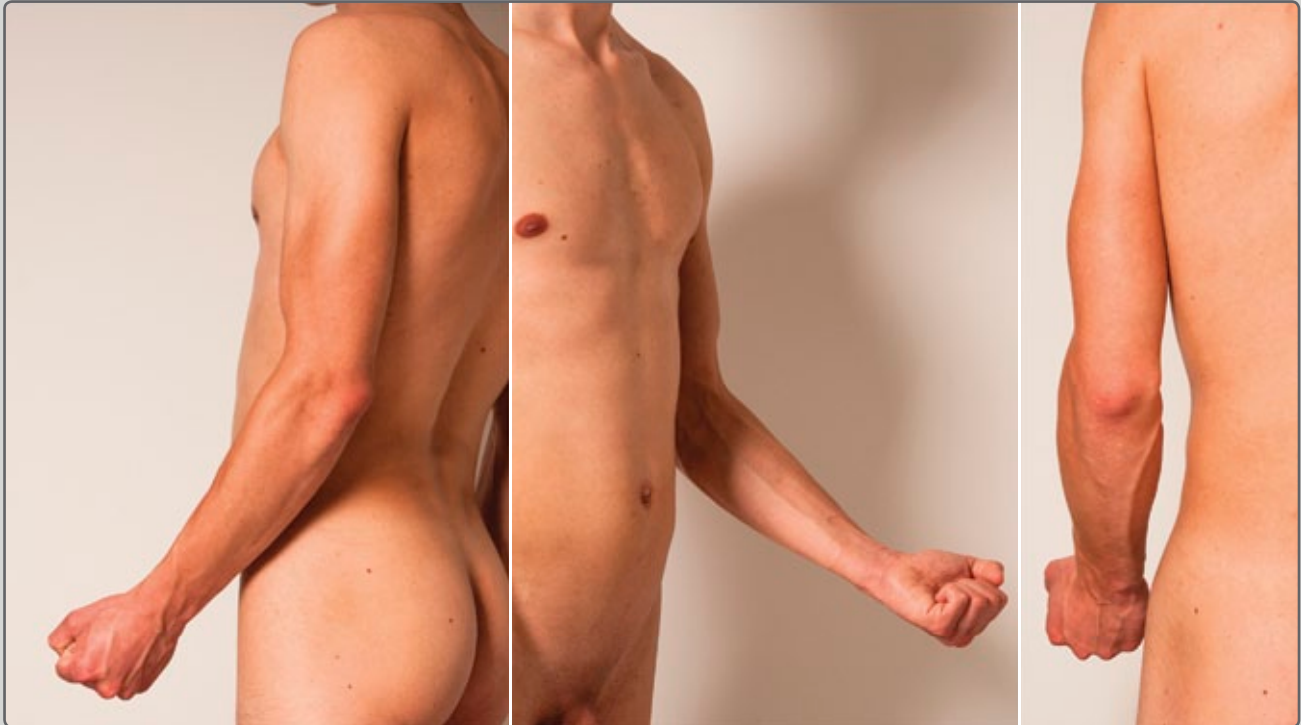RIGHT



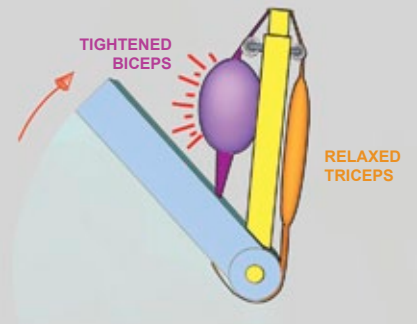
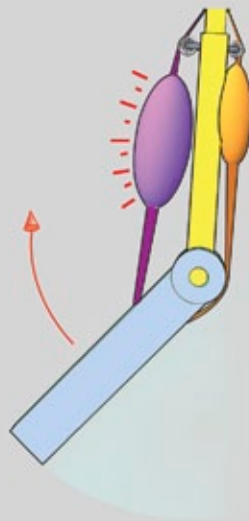
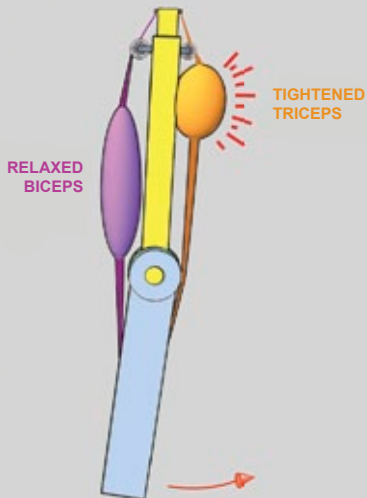
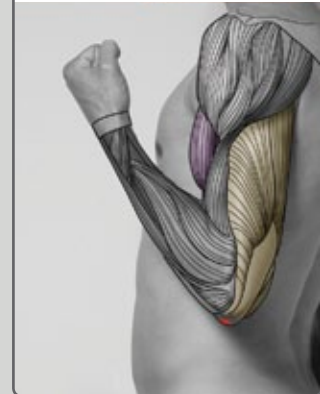
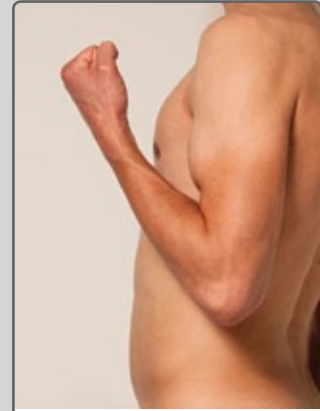
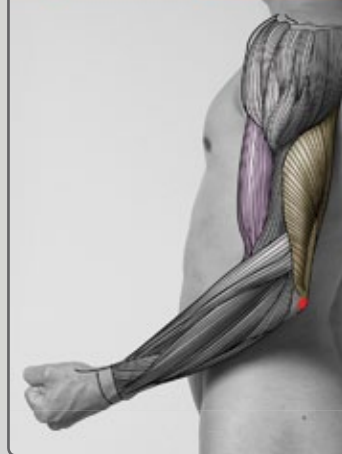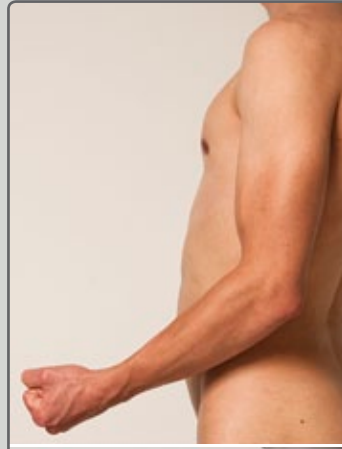
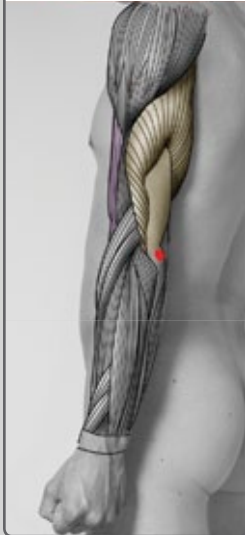
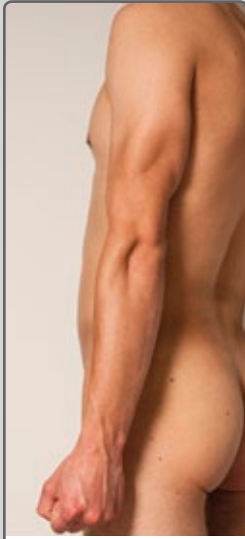
LEFT



PARTIALLY FLEXED ARM (AS IF HOLDING AN OBJECT)

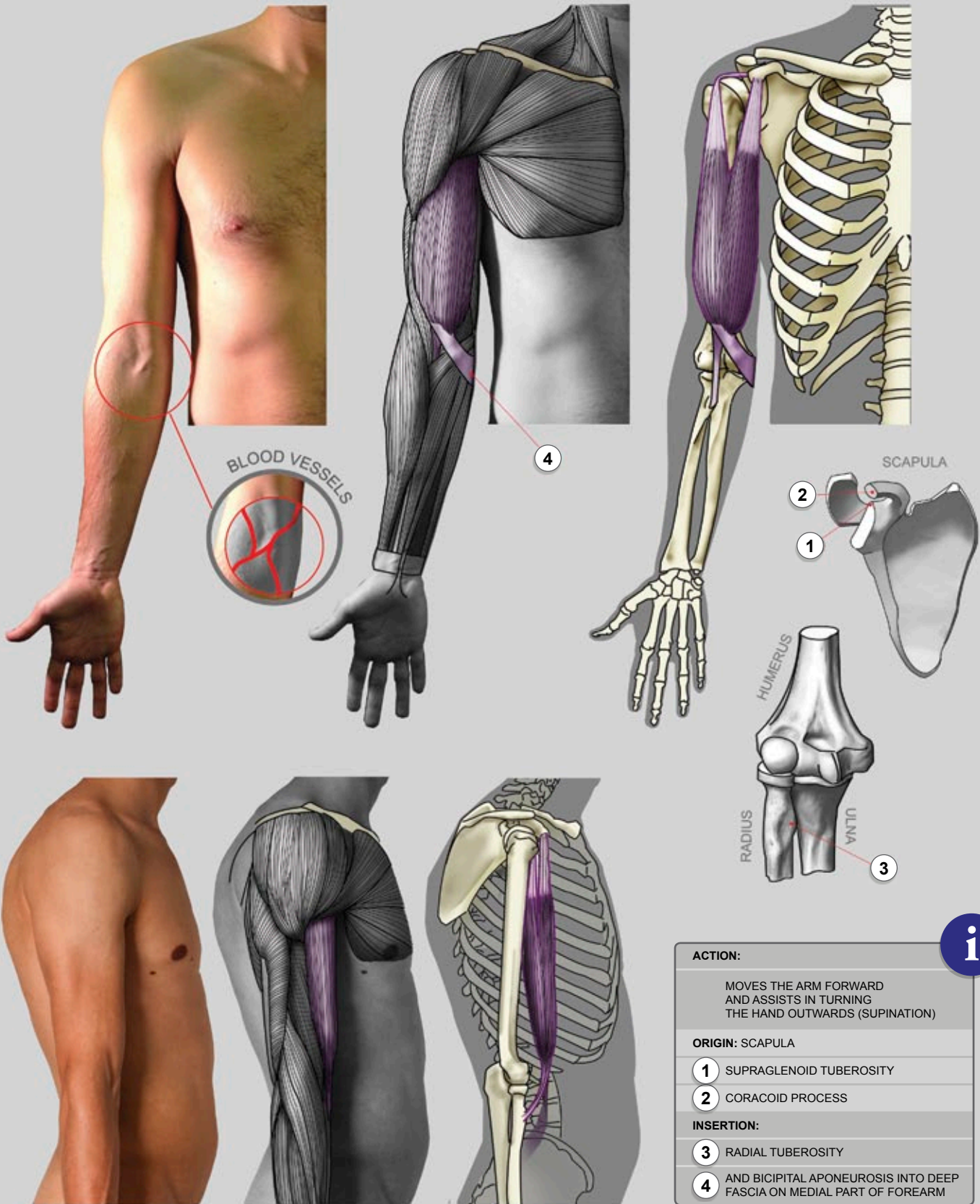


BICEPS AND TRICEPS IN ACTION



ELBOW BELONGS TO THE FOREARM.

BICEPS BRACHII MUSCLE



ACTION:

MOVES THE ARM FORWARD AND ASSISTS IN TURNING THE HAND OUTWARDS (SUPINATION)

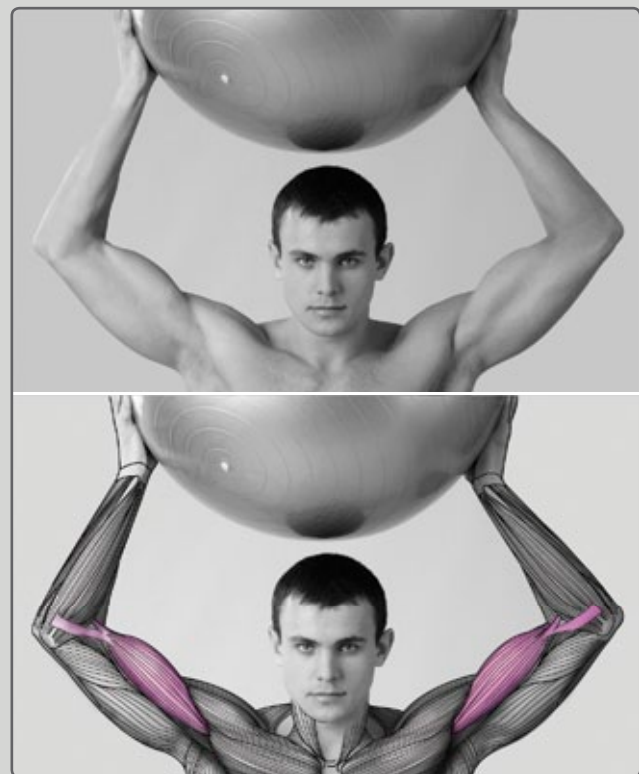
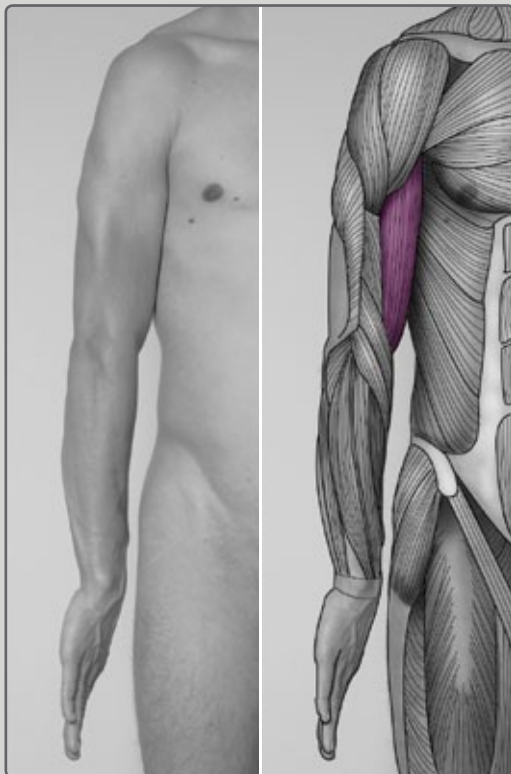
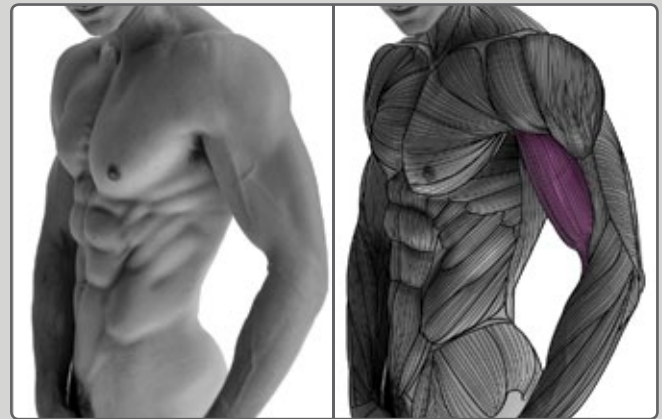
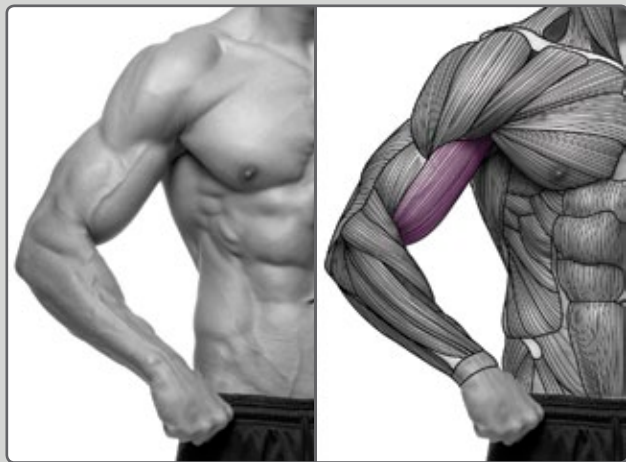
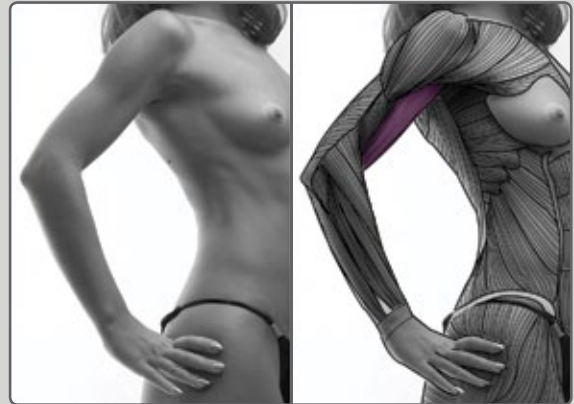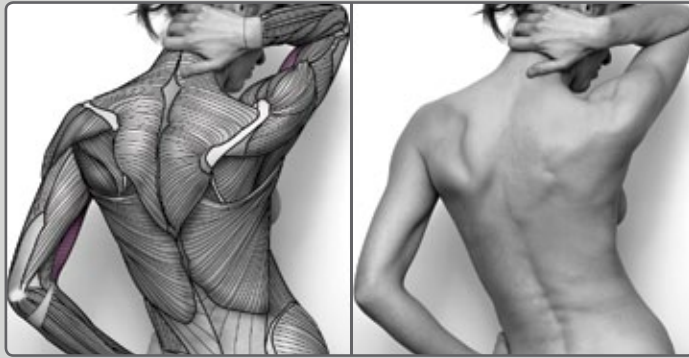
ORIGIN: SCAPULA

- 1 SUPRAGLENOID TUBEROSITY
- 2 CORACOID PROCESS

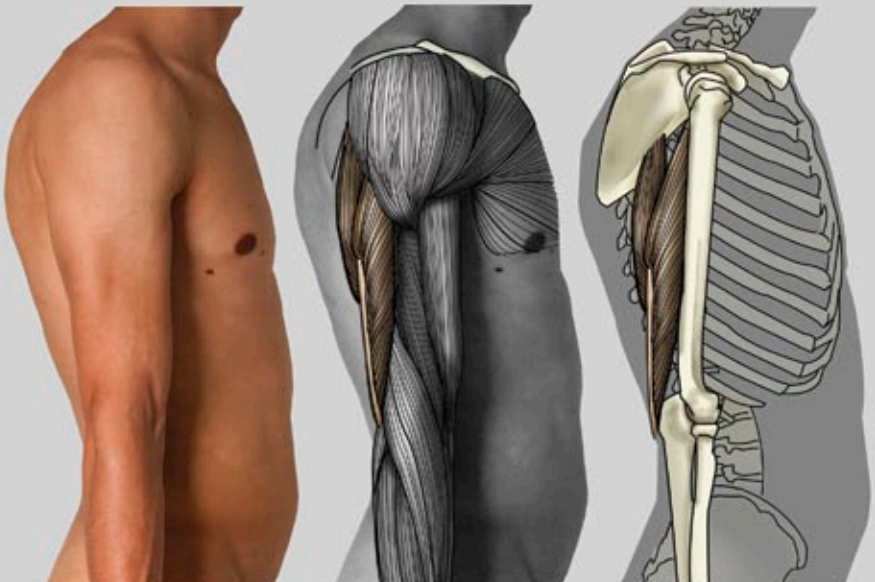
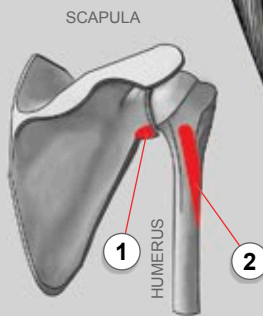
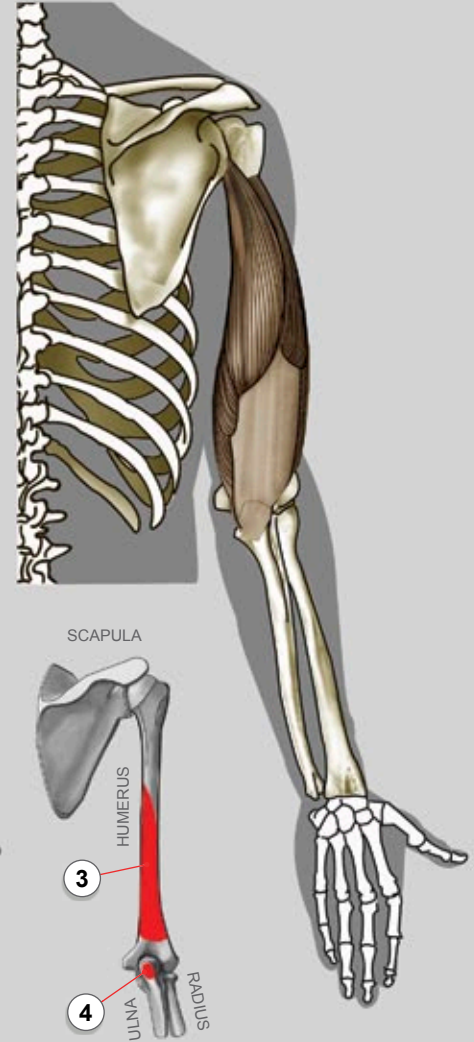
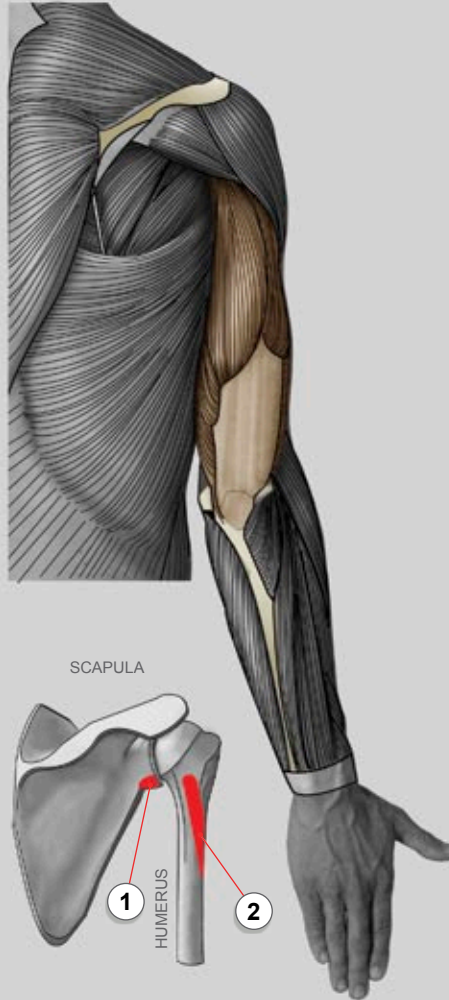
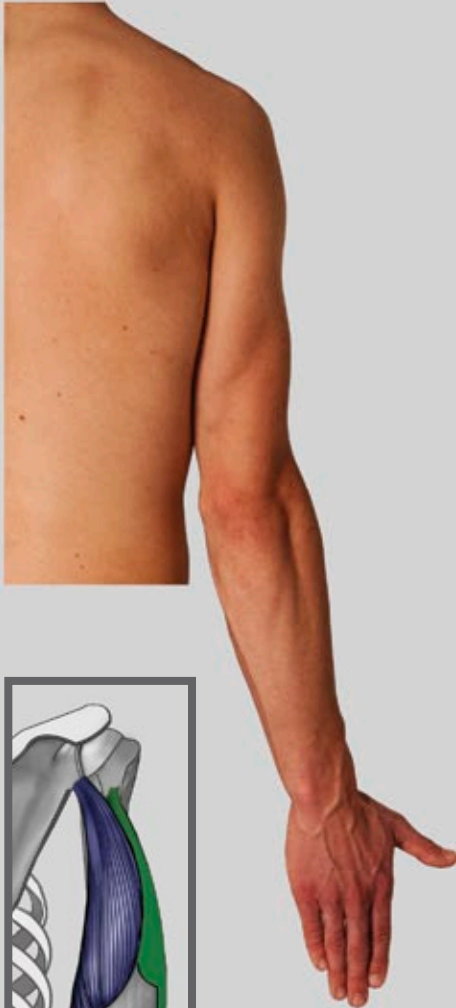INSERTION:

- 3 RADIAL TUBEROSITY
- 4 AND BICIPITAL APONEUROSIS INTO DEEP FASCIA ON MEDIAL PART OF FOREARM

BICEPS BRACHII MUSCLE

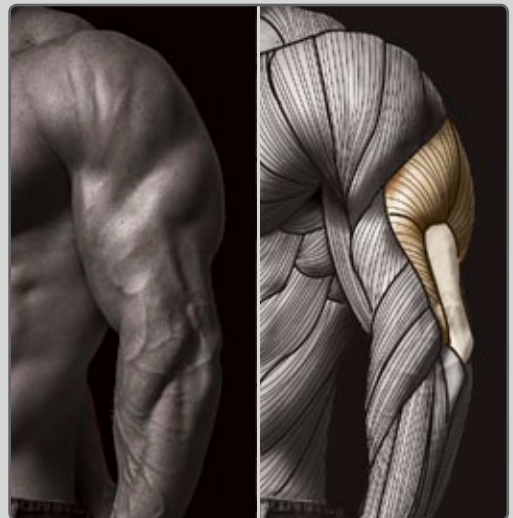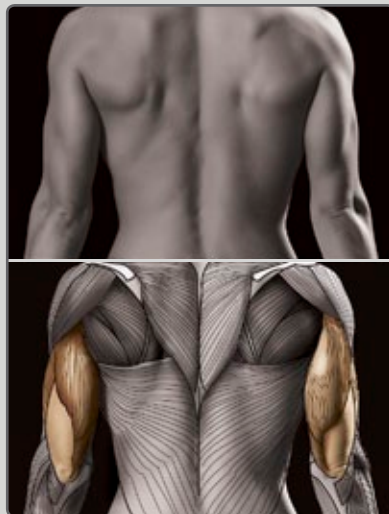
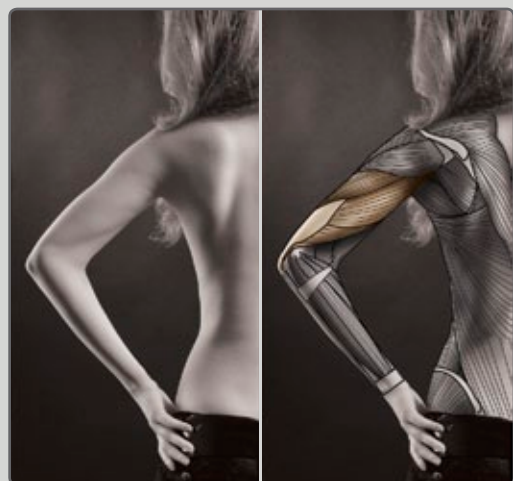
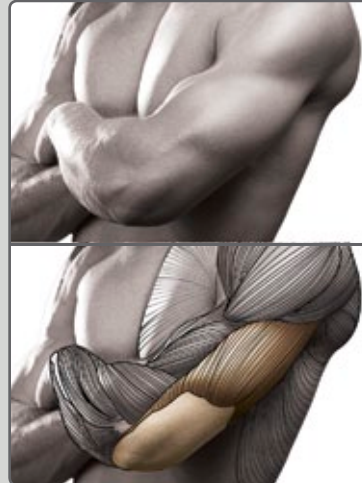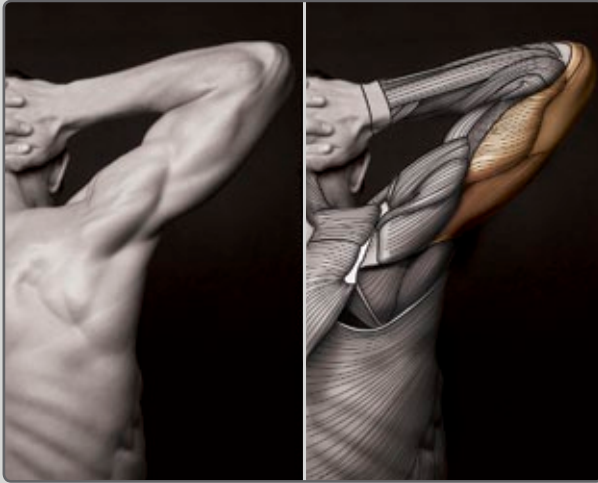


TRICEPS BRACHII MUSCLE

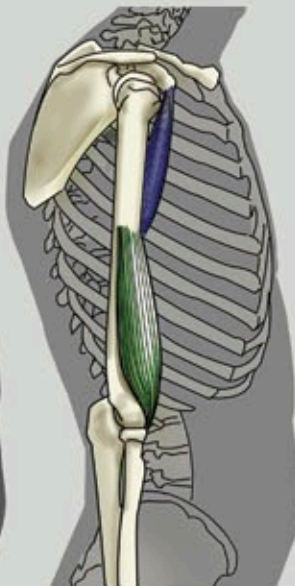
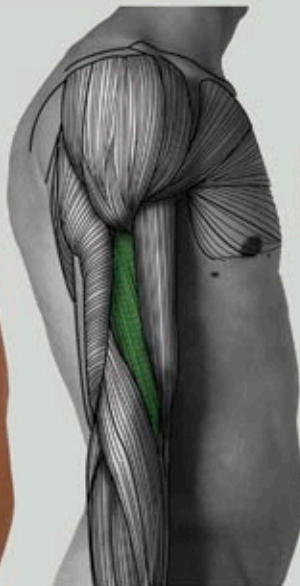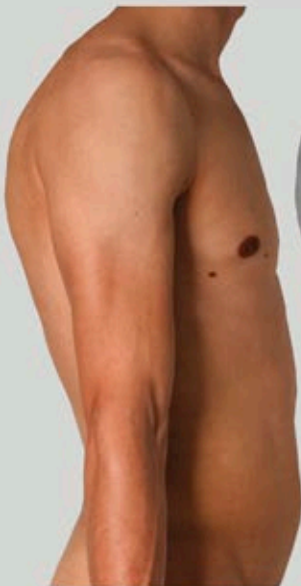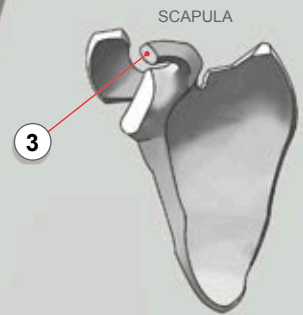
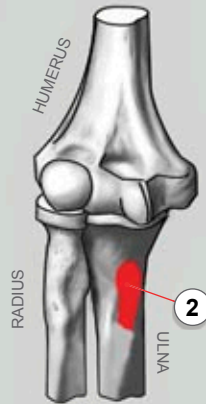
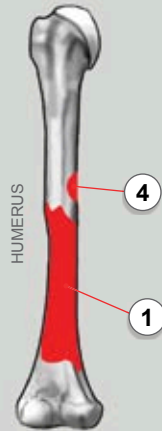
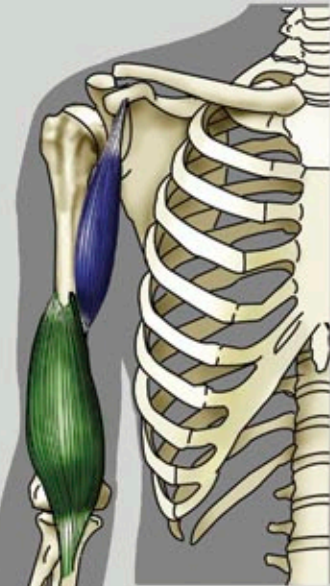
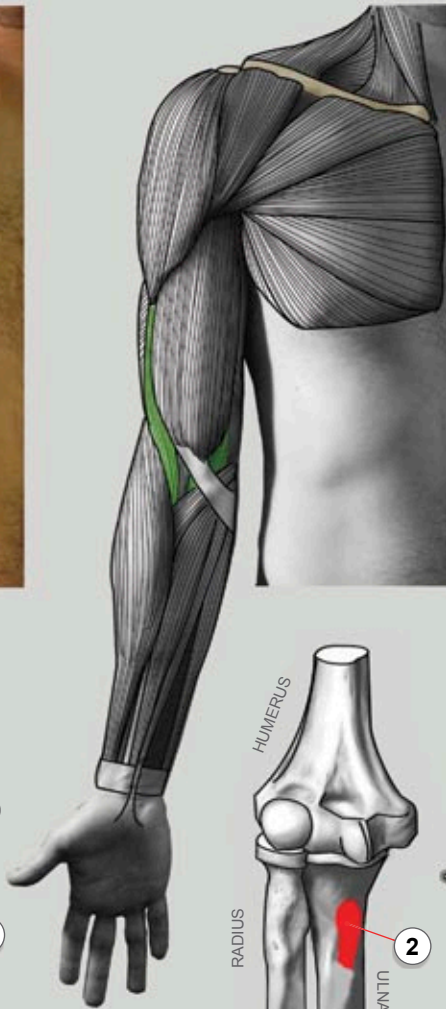


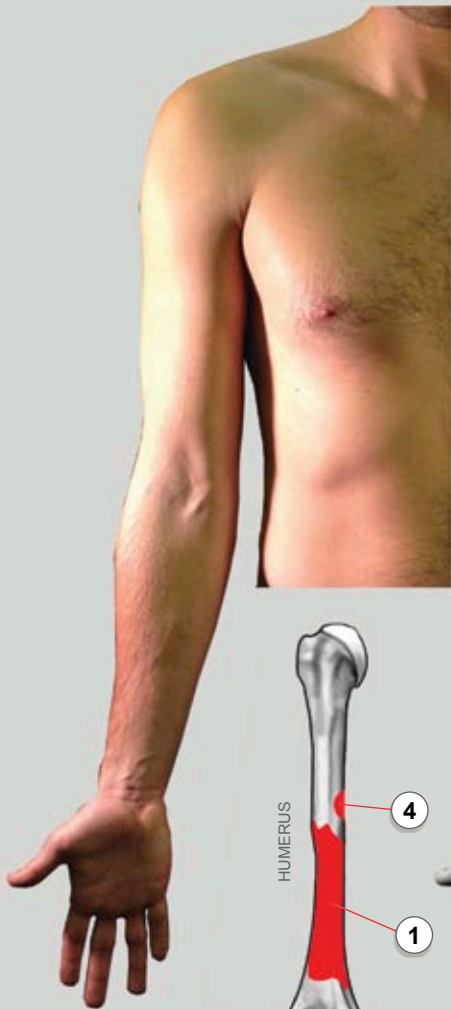ACTION:
EXTENDS FOREARM LONG HEAD EXTENDS SHOULDER
ORIGIN:
1 LONG HEAD: INFRAGLENOID TUBERCLE OF SCAPULA
2 LATERAL HEAD: ABOVE THE RADIAL SULCUS
3 MEDIAL HEAD: BELOW THE RADIAL SULCUS
INSERTION:
4 OLECRANON PROCESS OF ULNA

TRICEPS BRACHII MUSCLE



BRACHIALIS AND CORACOBRAHIALIS MUSCLES



BRACHIALIS

ACTION:

FLEXION AT ELBOW JOINT

ORIGIN:

1 ANTERIOR SURFACE OF THE HUMERUS

INSERTION:

2 CORONOID PROCESS AND THE TUBEROSITY OF THE ULNA

CORACOBRAHIALIS

ACTION:

ADDUCTS HUMERUS, FLEXES THE ARM AT GLENOHUMERAL JOINT

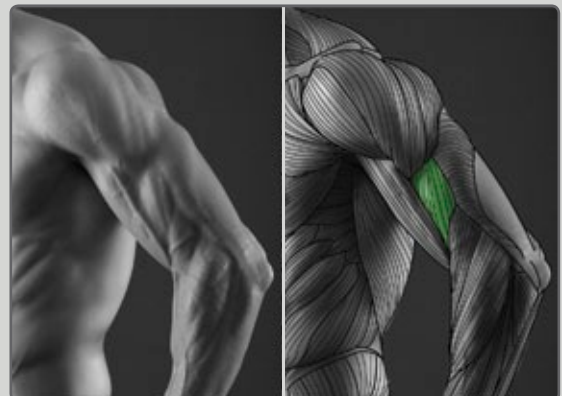
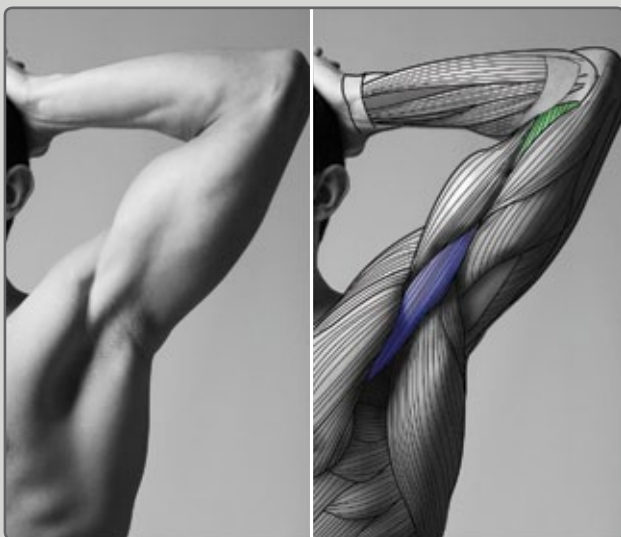
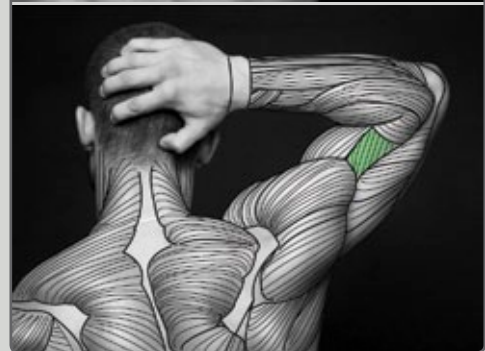
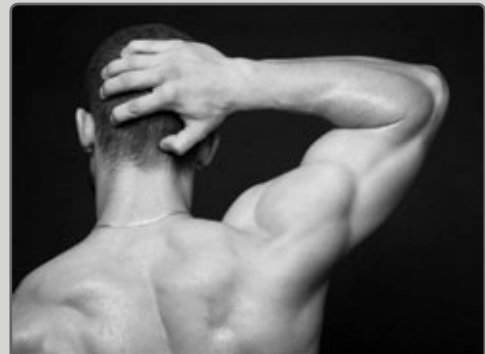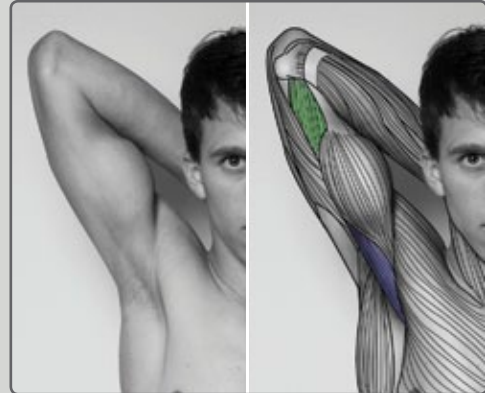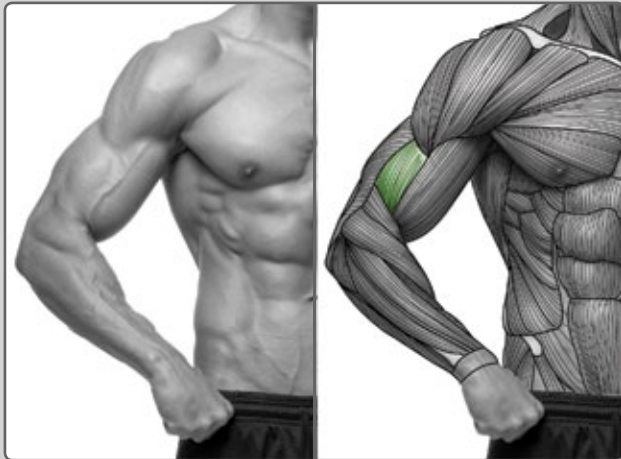
ORIGIN:

3 CORACOID PROCESS OF SCAPULA

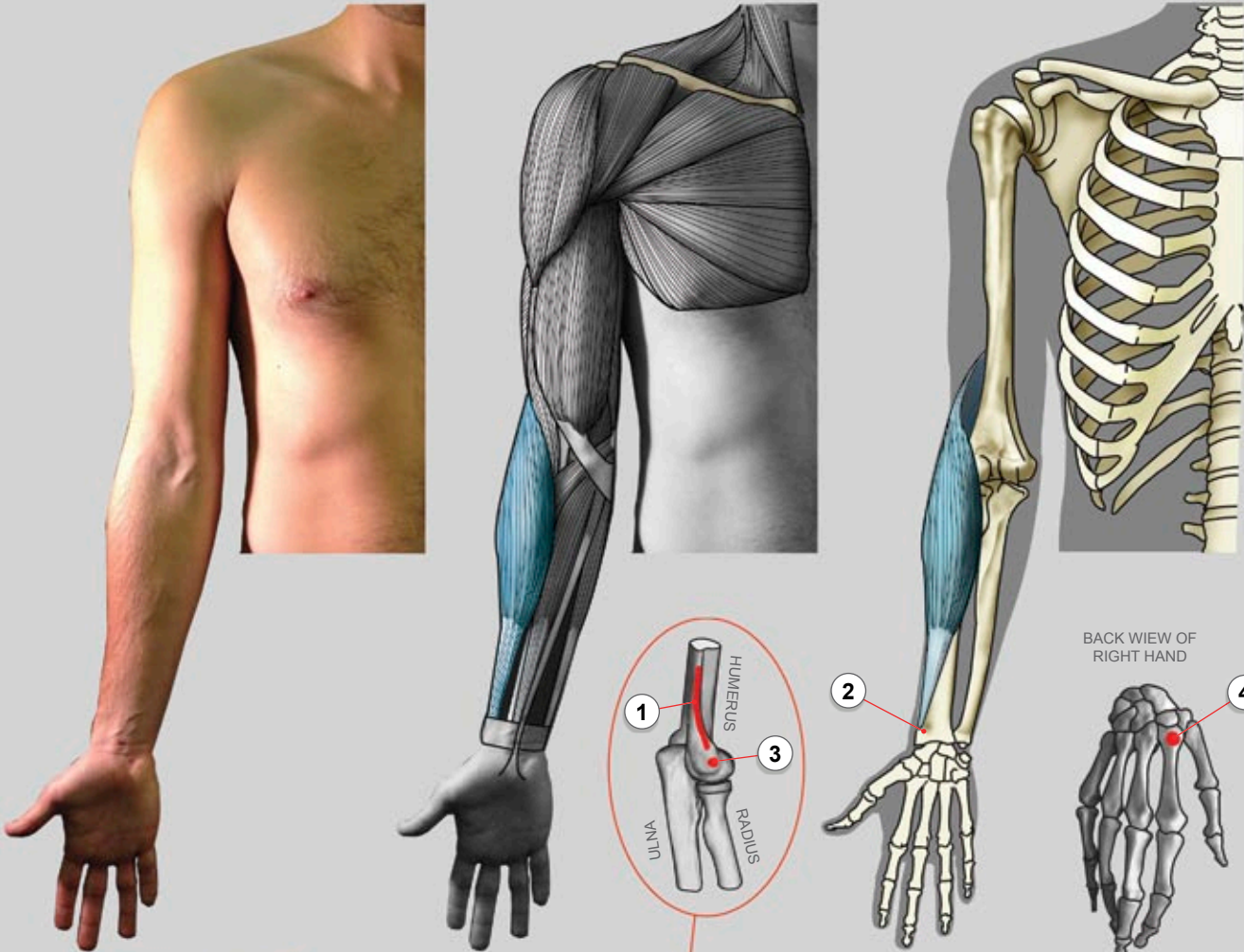
INSERTION:

4 MEDIAL HUMERUS

BRACHIALIS AND CORACOBRACHIALIS MUSCLES



BRACHIORADIALIS AND EXTENSOR CARPI RADIALIS LONGUS



BACK VIEW OF RIGHT HAND

BRACHIORADIALIS

ACTION:

FLEXION OF ELBOW

ORIGIN:

1 LATERAL SUPRACONDYLAR RIDGE OF THE HUMERUS

INSERTION:

2 DISTAL RADIUS (RADIAL STYLOID PROCESS)

EXTENSOR CARPI RADIALIS LONGUS

ACTION:

EXTENSOR AT THE WRIST JOINT, ABDUCTS THE HAND AT THE WRIST

ORIGIN:

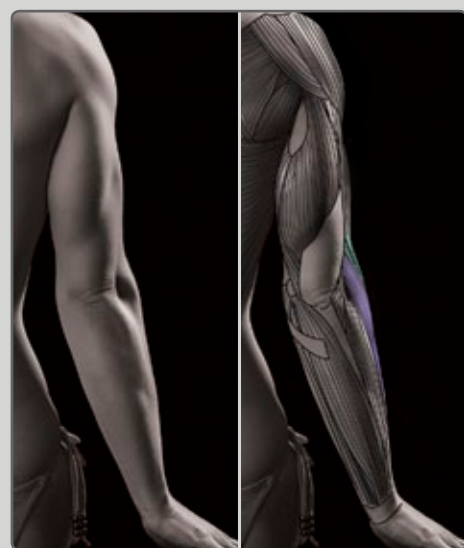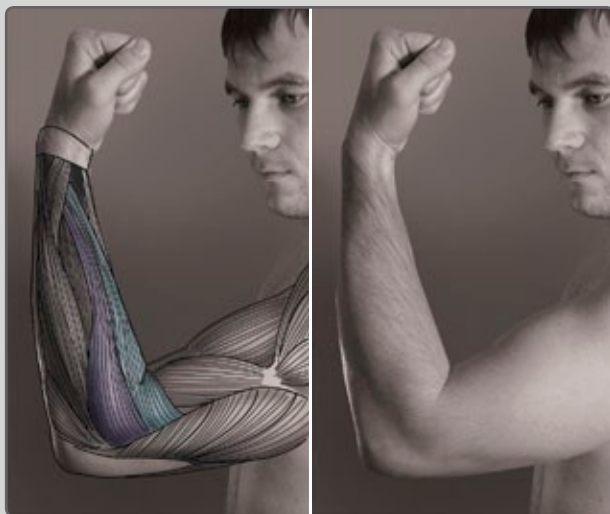
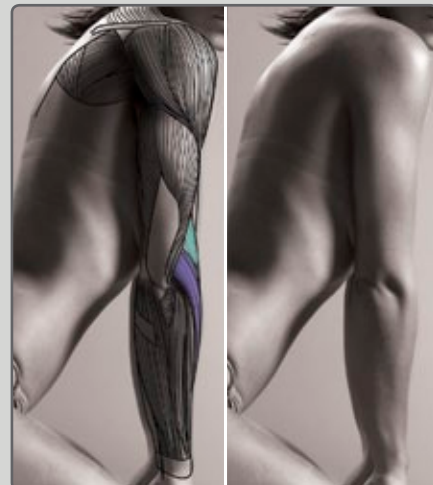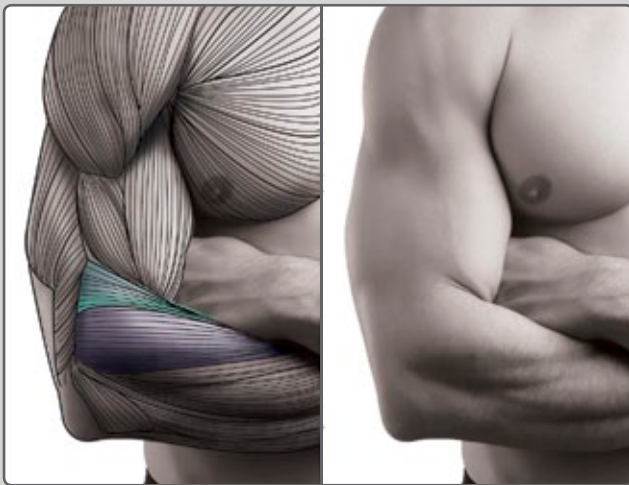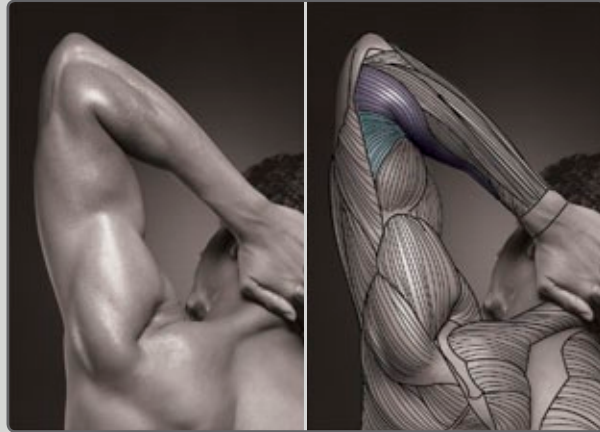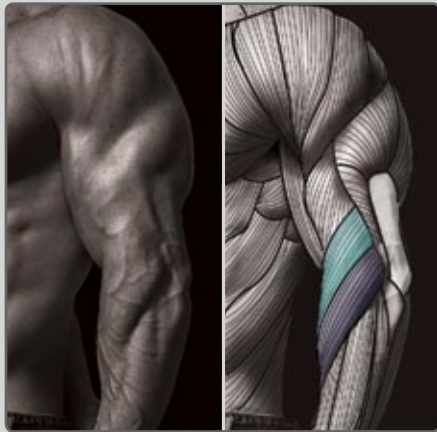3 LATERAL SUPRACONDYLAR RIDGE

INSERTION:

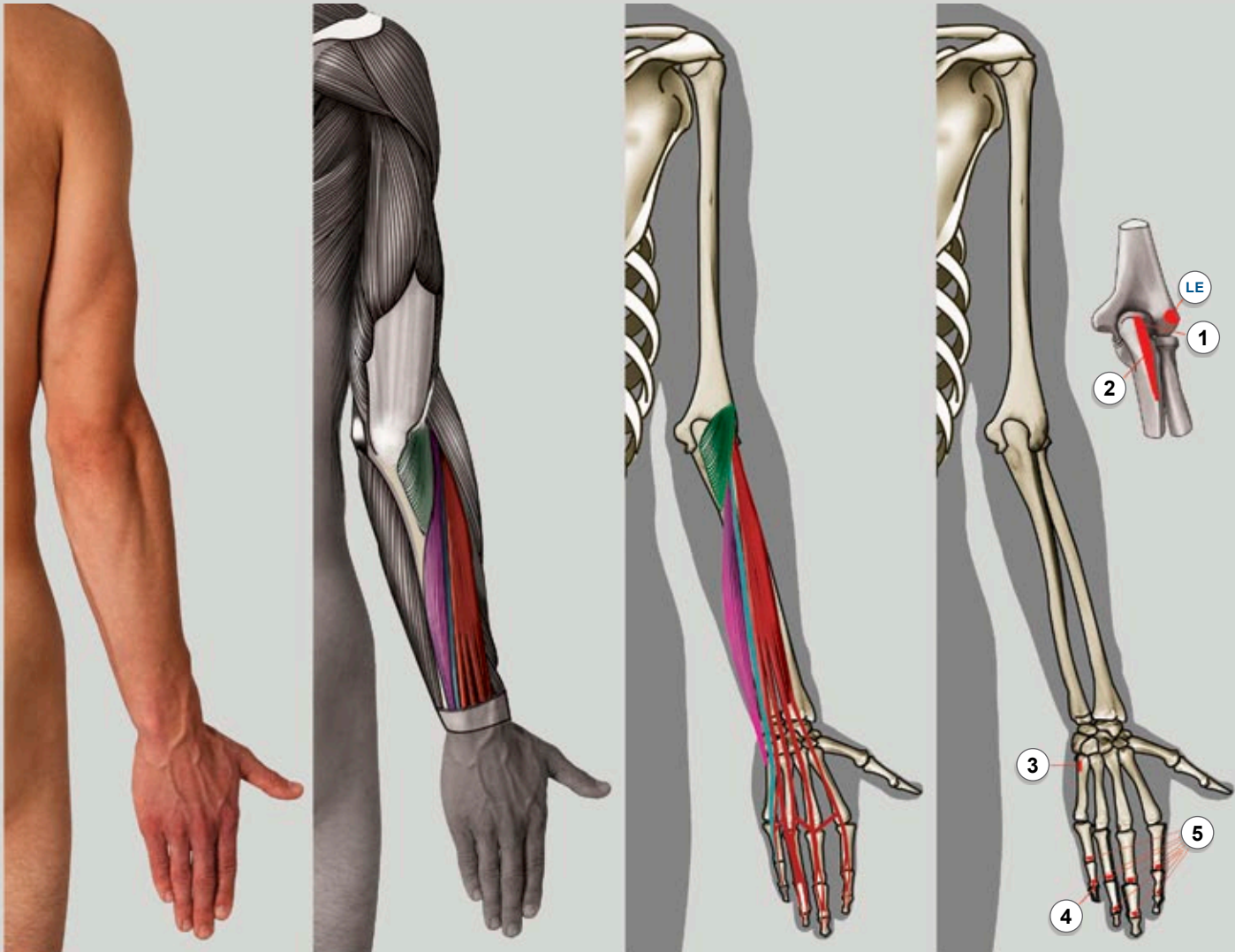
4 2nd METACARPAL



BRACHIORADIALIS AND EXTENSOR CARPI RADIALIS LONGUS



ANCONEUS, EXTENSOR CARPI ULNARIS, EXTENSOR DIGITI MINIMI AND EXTENSOR DIGITORUM MUSCLES



ANCONEUS

ACTION:

STABILIZES THE ELBOW

ORIGIN:

LE LATERAL EPICONDYLE OF THE HUMERUS

INSERTION:

- 1** LATERAL SURFACE OF THE OLECRANON PROCESS
- 2** SUPERIOR PART OF THE POSTERIOR ULNA DISTALLY

EXTENSOR DIGITI MINIMI

ACTION:

EXTENDS THE WRIST AND THE LITTLE FINGER AT ALL JOINTS

ORIGIN:

LE LATERAL EPICONDYLE OF THE HUMERUS

INSERTION:

- 4** AT THE EXTENSOR EXPANSION ON PROXIMAL PHALANX OF THE LITTLE FINGER

EXTENSOR CARPI ULNARIS

ACTION:

EXTENDS AND ADDUCTS THE WRIST

ORIGIN:

LE LATERAL EPICONDYLE OF THE HUMERUS, ULNA

INSERTION:

- 3** 5th METACARPAL

EXTENSOR DIGITORUM

ACTION:

EXTENDS HAND, WRIST AND FINGERS

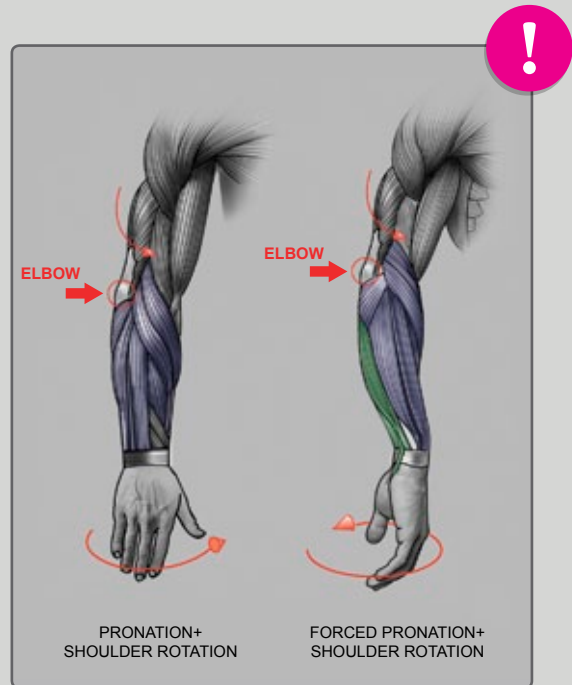
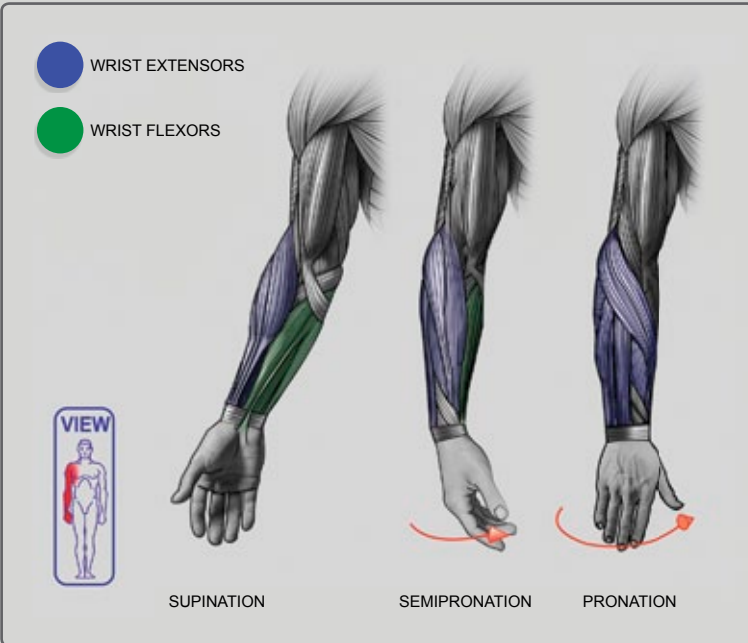
ORIGIN:

LE LATERAL EPICONDYLE OF THE HUMERUS

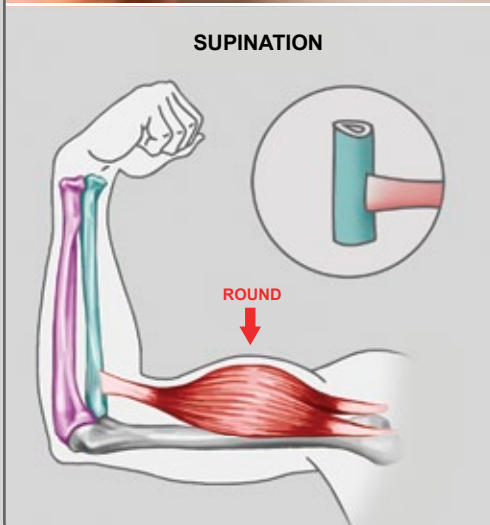
INSERTION:

- 5** EXTENSOR EXPANSION OF MIDDLE AND DISTAL PHALANGES OF THE 2nd, 3rd, 4th AND 5th FINGERS

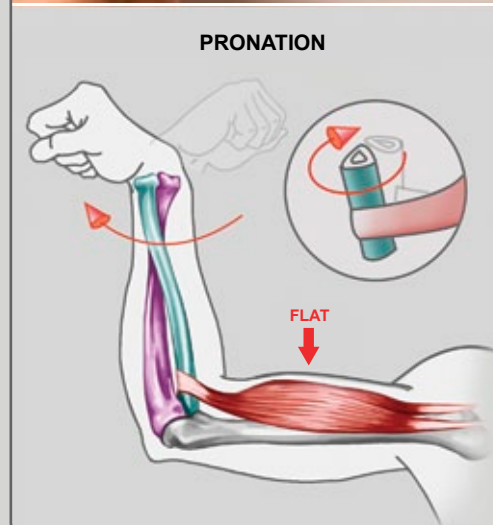
SUPINATION AND PRONATION



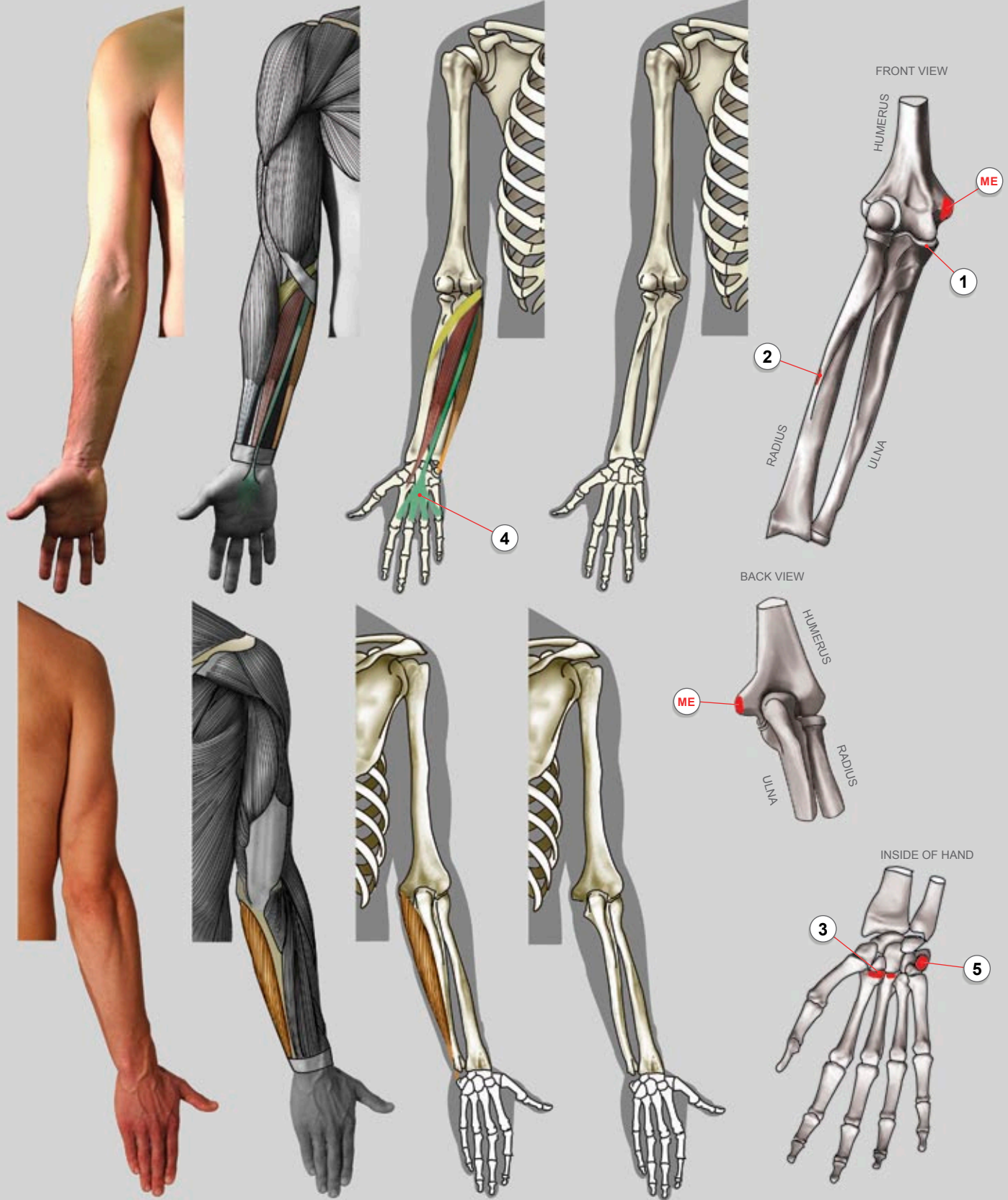
SUPINATION



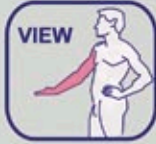PRONATION



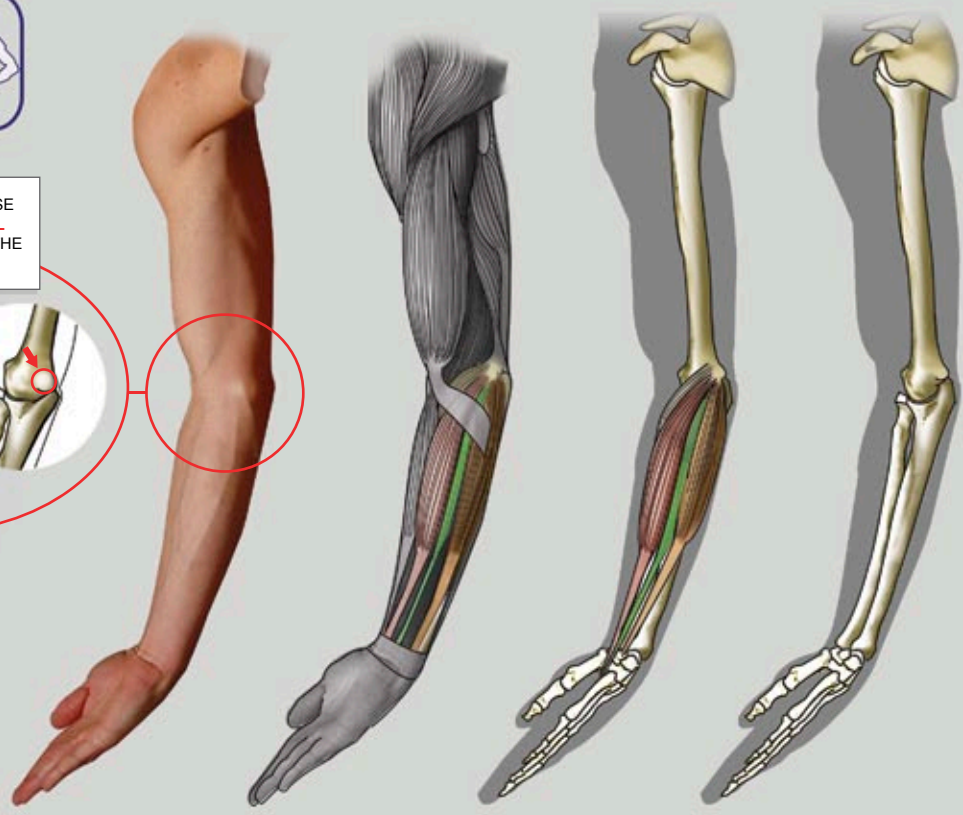
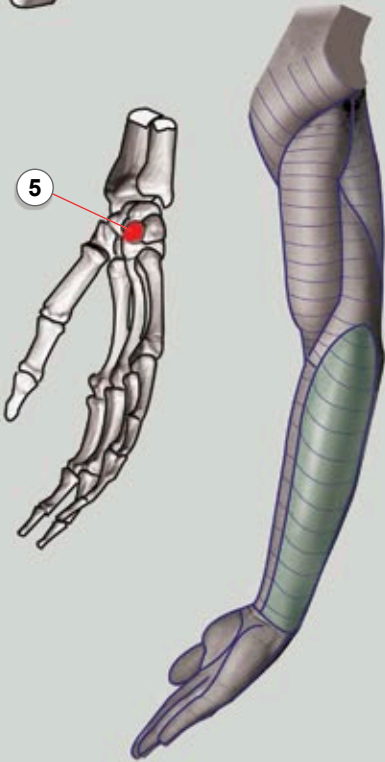
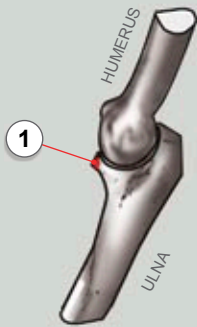
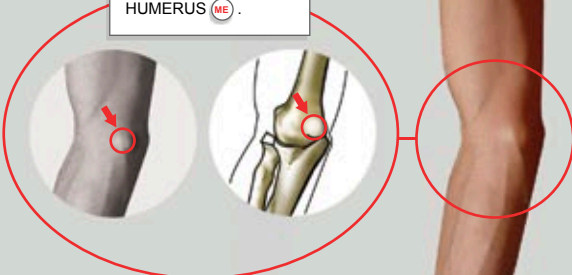
FLEXOR MUSCLES



FLEXOR MUSCLES (FROM INNER SIDE)



ALL FLEXORS ARISE FROM THE **MEDIAL EPICONDYLE OF THE HUMERUS** (ME).



PRONATOR TERES

ACTION:

PRONATION OF FOREARM, FLEXES ELBOW

ORIGIN:

ME MEDIAL EPICONDYLE OF HUMERUS (COMMON FLEXOR TENDON)

1 ULNAR HEAD: CORONOID PROCESS OF ULNA

INSERTION:

2 MIDDLE OF THE LATERAL SURFACE OF THE RADIUS

FLEXOR CARPI RADIALIS

ACTION:

FLEXION AND ABDUCTION AT WRIST

ORIGIN:

ME MEDIAL EPICONDYLE OF HUMERUS (COMMON FLEXOR TENDON)

INSERTION:

3 BASE OF SECOND AND THIRD METACARPAL BONES

PALMARIS LONGUS

ACTION:

WRIST FLEXOR

ORIGIN:

ME MEDIAL EPICONDYLE OF HUMERUS (COMMON FLEXOR TENDON)

INSERTION:

4 PALMAR APONEUROSIS

FLEXOR CARPI ULNARIS

ACTION:

FLEXION AND ABDUCTION AT WRIST

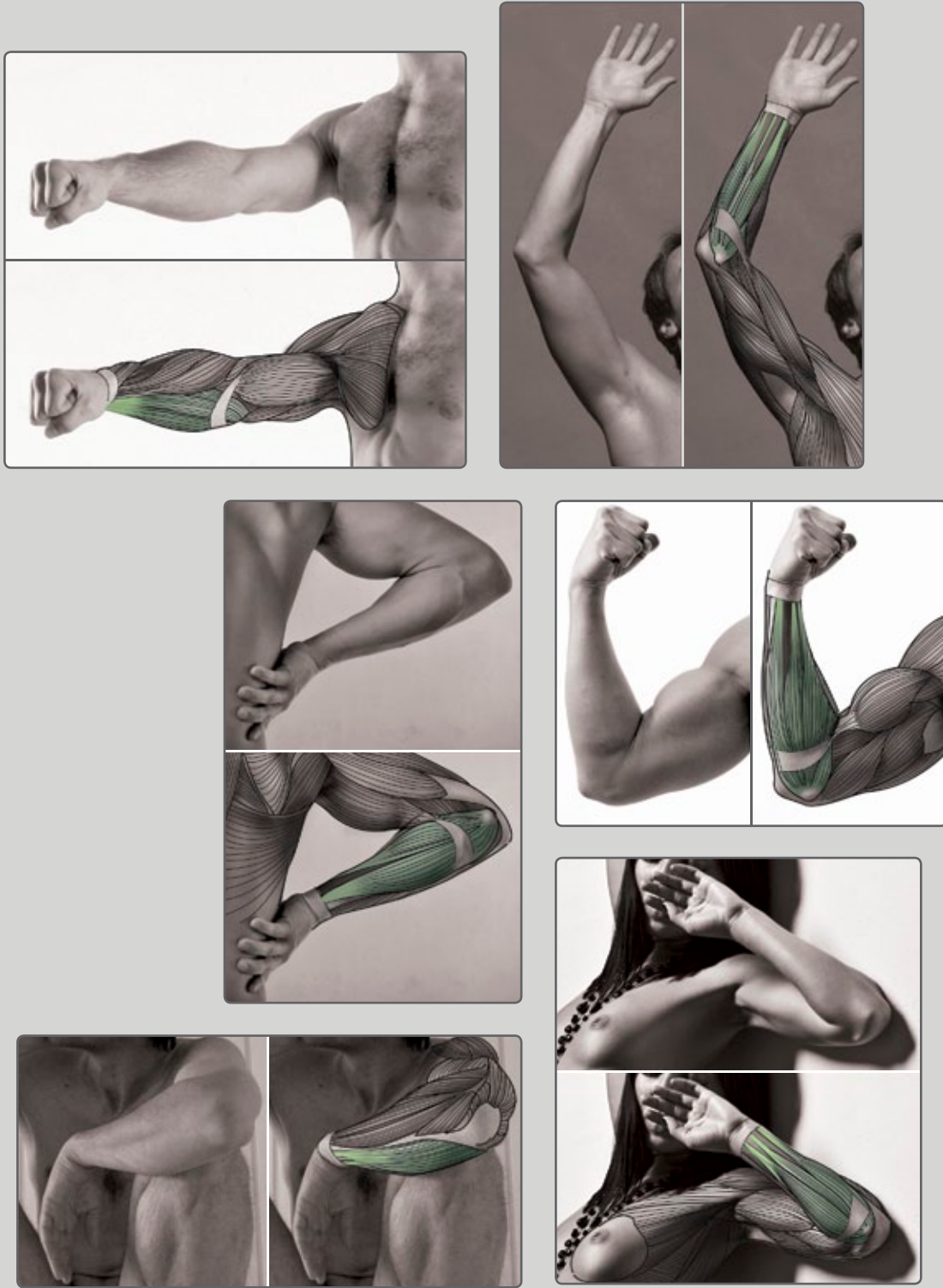
ORIGIN:

ME MEDIAL EPICONDYLE OF HUMERUS (COMMON FLEXOR TENDON)

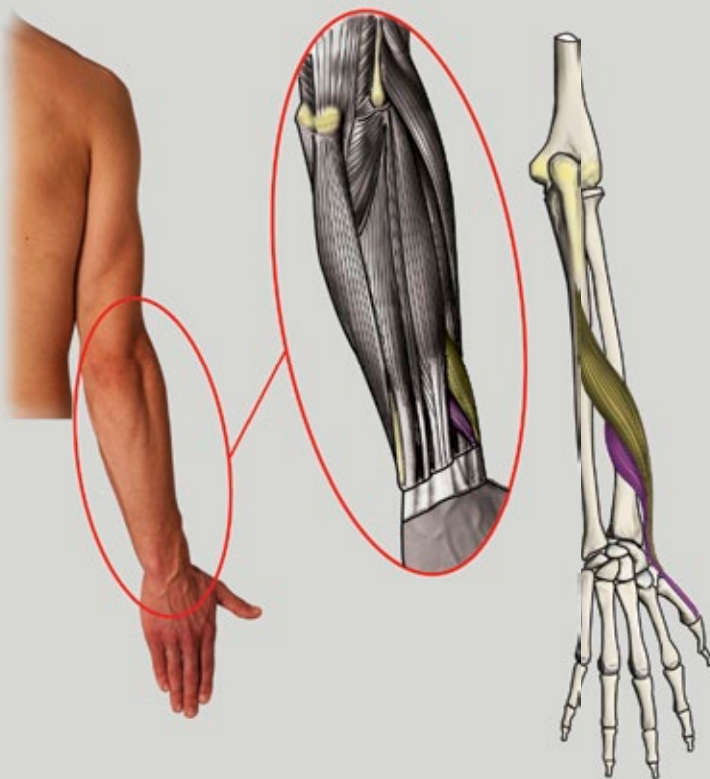
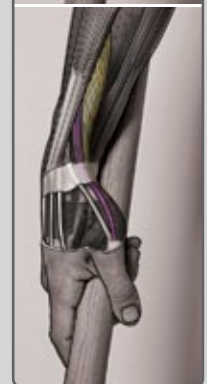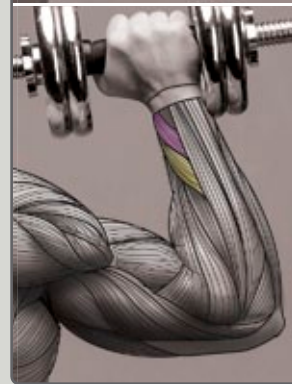
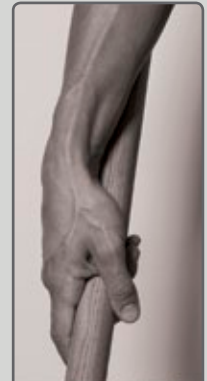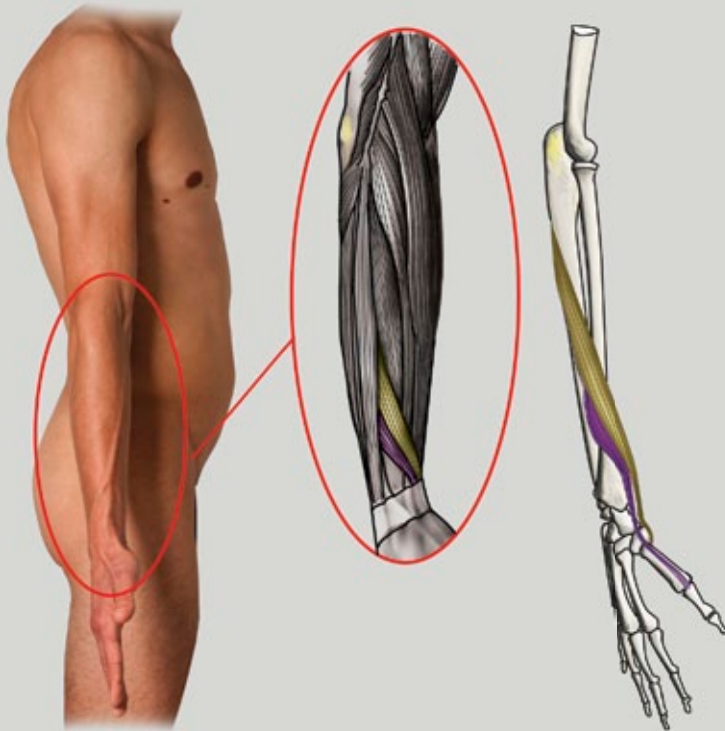
INSERTION:

5 PISIFORM

FLEXOR MUSCLES



ABDUCTOR POLLICIS LONGUS AND EXTENSOR POLLICIS BREVIS MUSCLES



ABDUCTOR POLLICIS LONGUS

ACTION:

ABDUCTION, EXTENSION OF THUMB

ORIGIN:

ULNA, RADIUS,
INTEROSSEOUS MEMBRANE

INSERTION:

FIRST METACARPAL

EXTENSOR POLLICIS BREVIS

ACTION:

EXTENSION OF THUMB AT
METACARPOPHALANGEAL JOINT

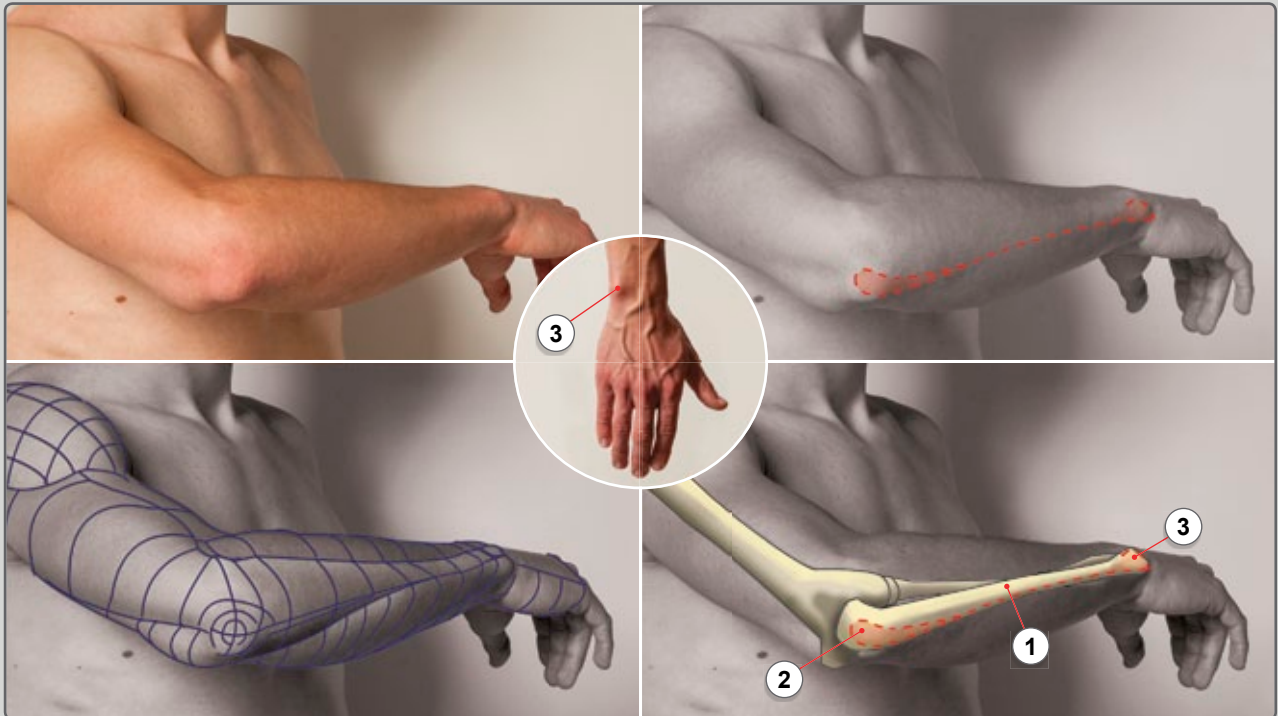
ORIGIN:

RADIUS AND THE INTEROSSEOUS MEMBRANE

INSERTION:

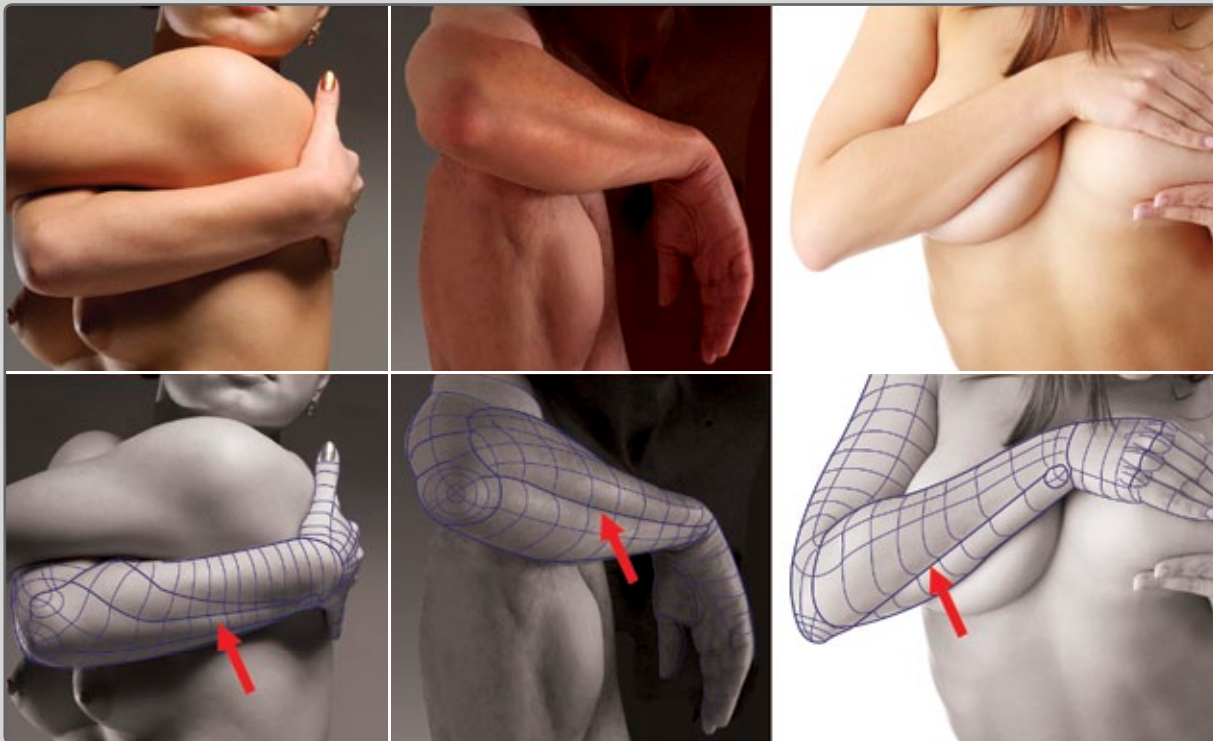
THUMB, PROXIMAL PHALANX

THE BODY OF THE ULNA

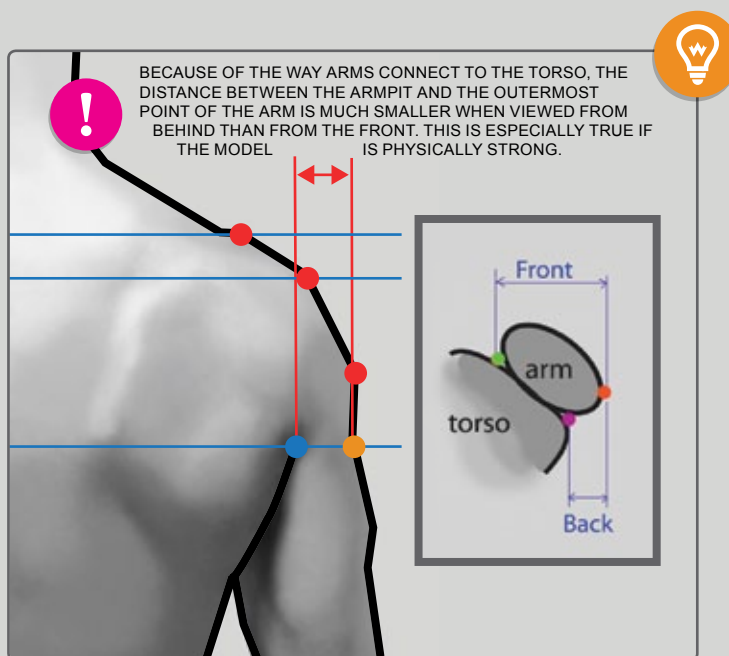
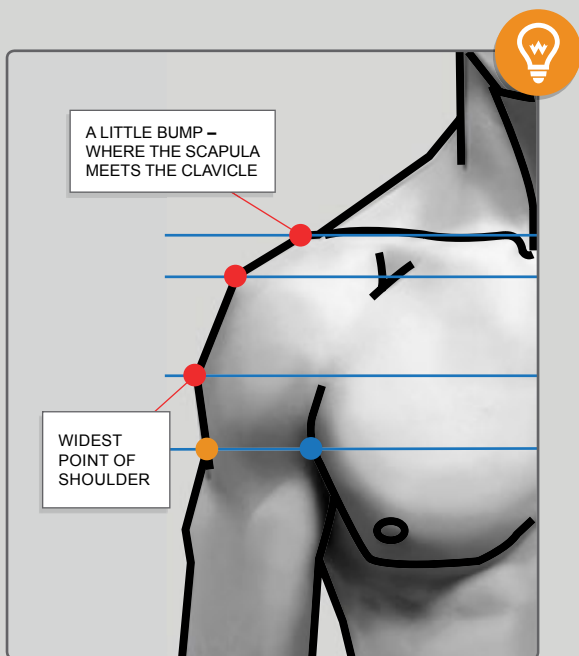
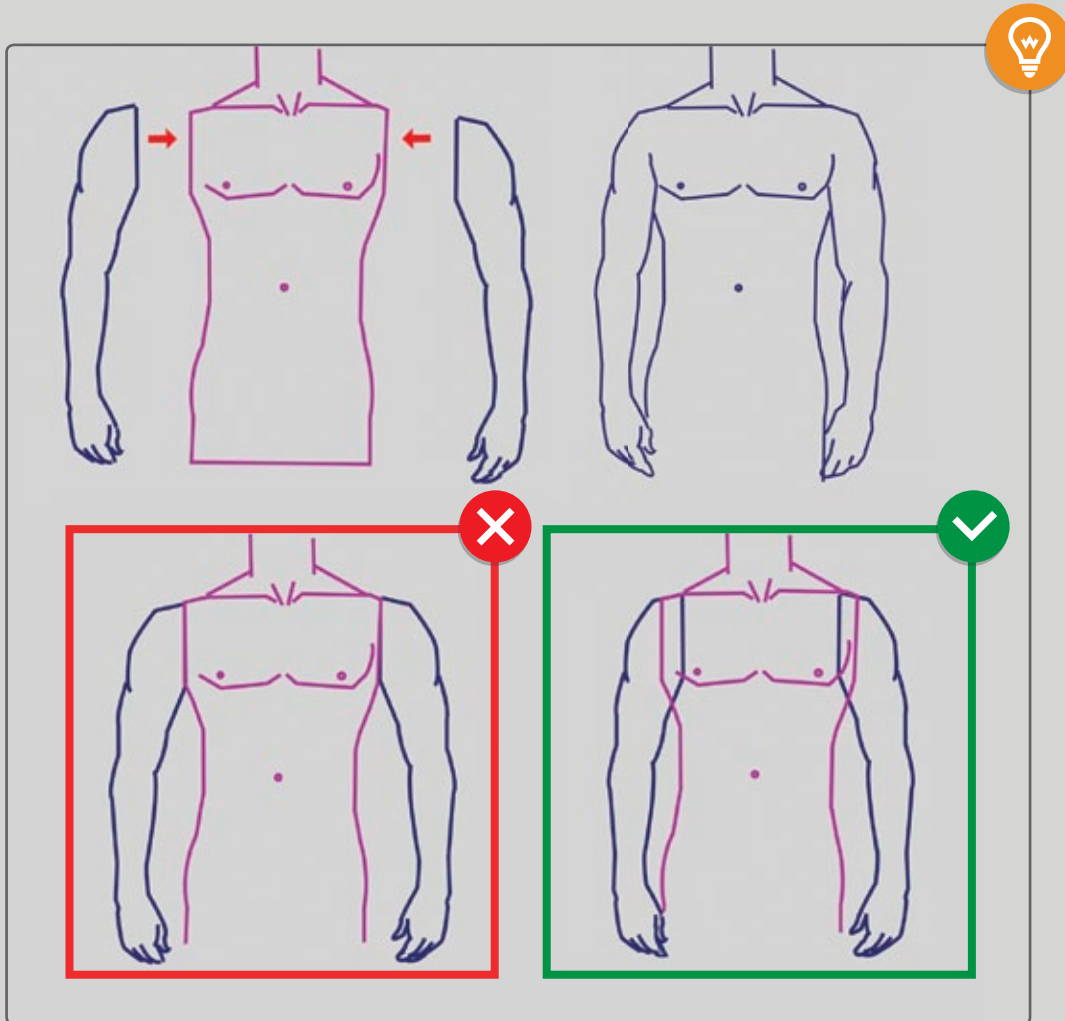


THE BODY OF **THE ULNA** ① IS AN IMPORTANT LANDMARK. WHEREVER YOU TURN THE HAND, THE ULNA ALWAYS EXTENDS FROM **THE ELBOW** ② TO LITTLE FINGER SIDE OF THE HAND, WHERE IT IS VISIBLE AS **A BUMP** ③ IT IS ALWAYS VISIBLE AS A RIDGE OR FURROW. BOTH ENDS OF THE BONE ARE NOT COVERED BY MUSCLES, ONLY BY THIN LAYER OF SKIN.

i



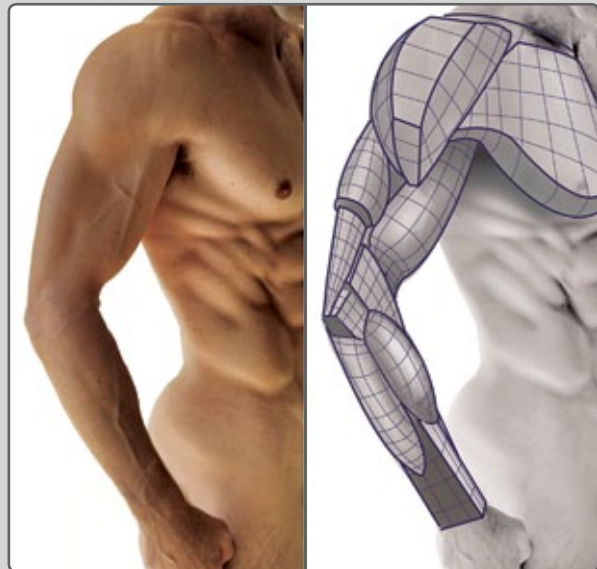
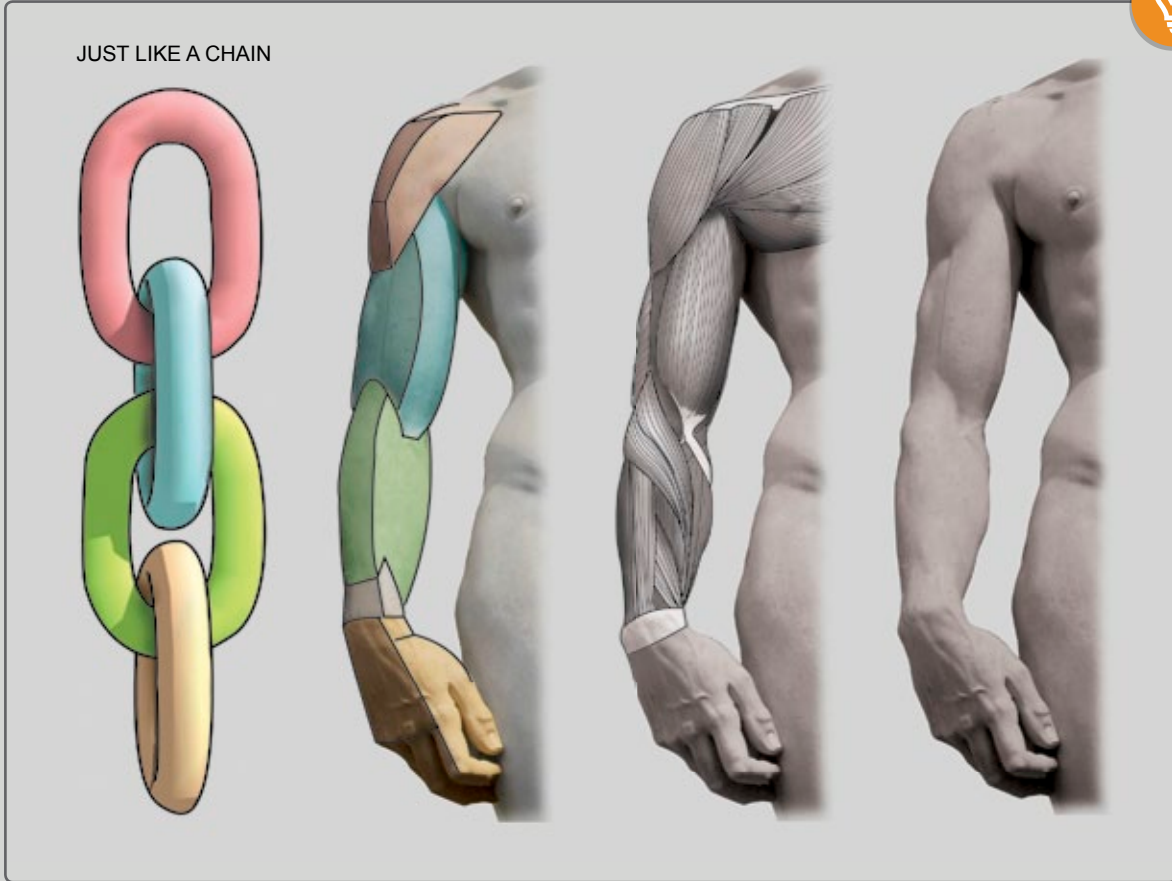
HOW ARMS CONNECT TO THE BODY



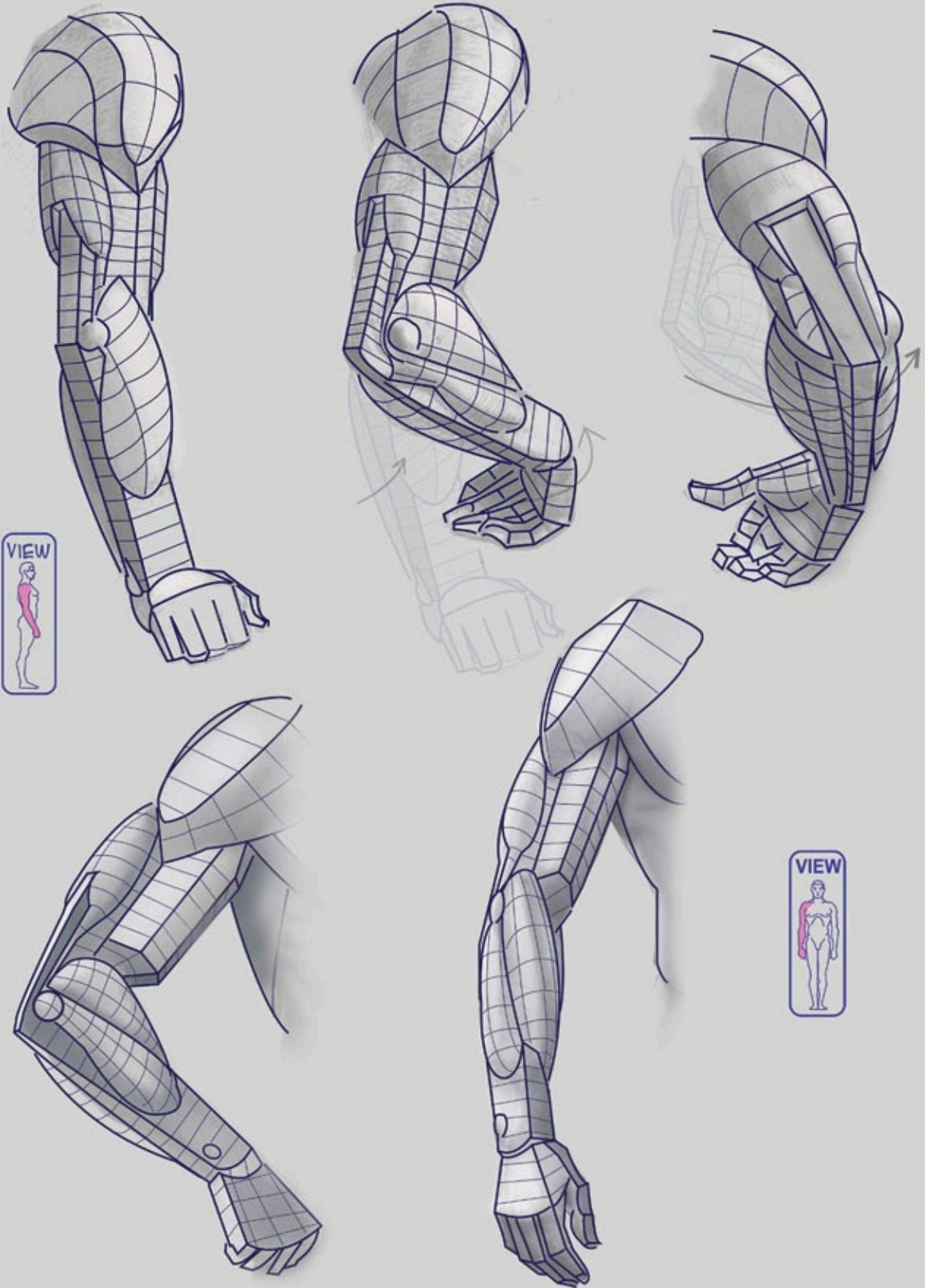
BLOCKING OUT A SEMIPRONATED ARM



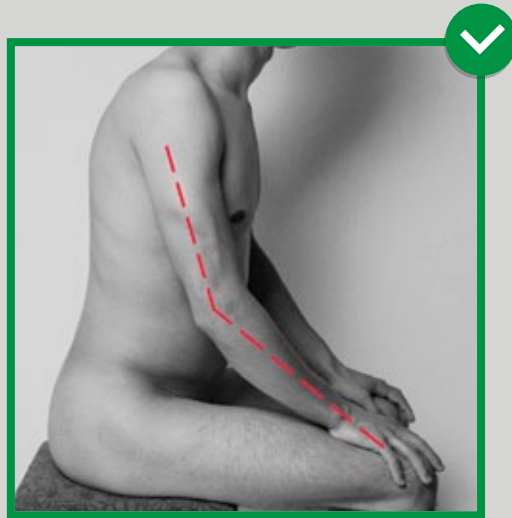
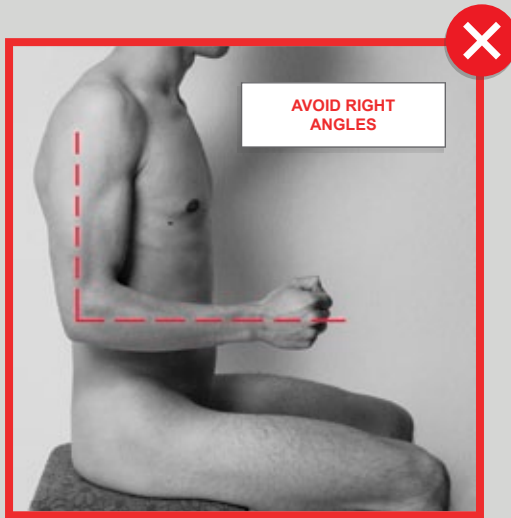
JUST LIKE A CHAIN



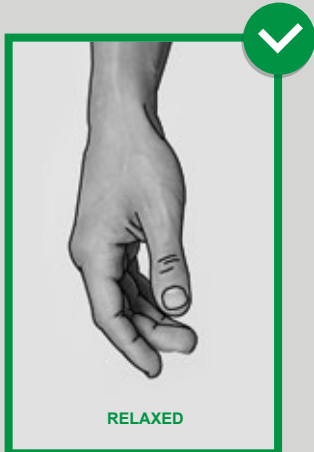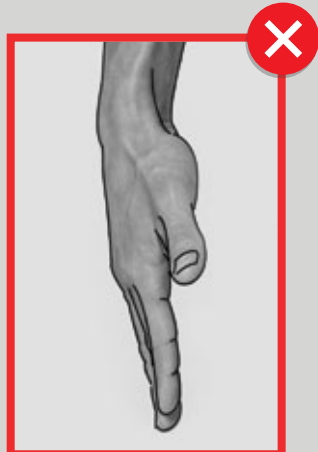
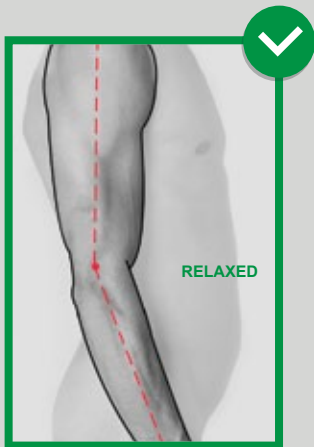
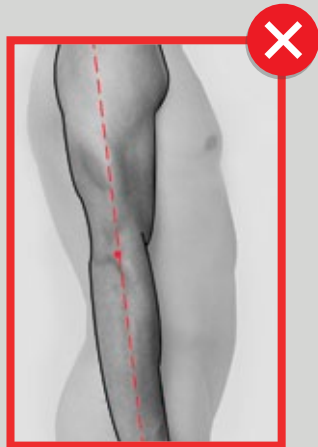
BLOCKING OUT AN ARM



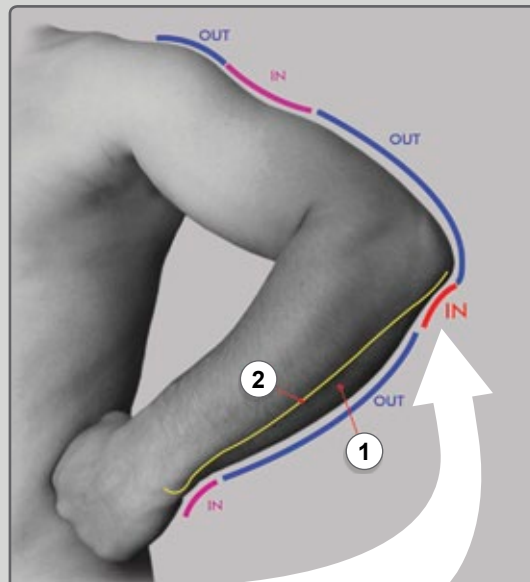
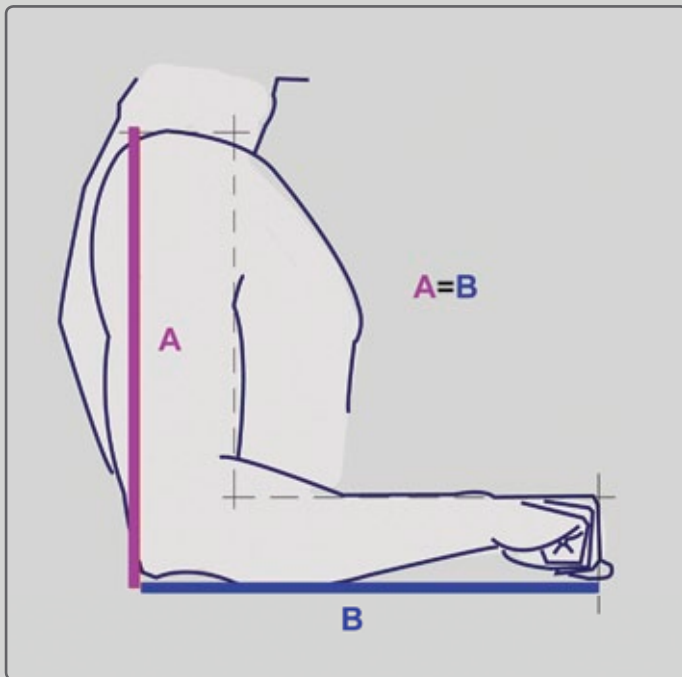
HOW DO YOU MAKE ARMS AND HANDS LOOK LESS STIFF?



DON'T MAKE ARMS OR HANDS STRAIGHT WITHOUT SPECIAL REASON.

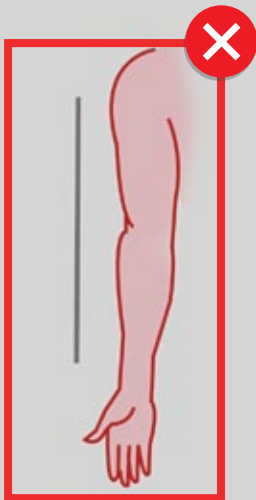


HANDY TIPS



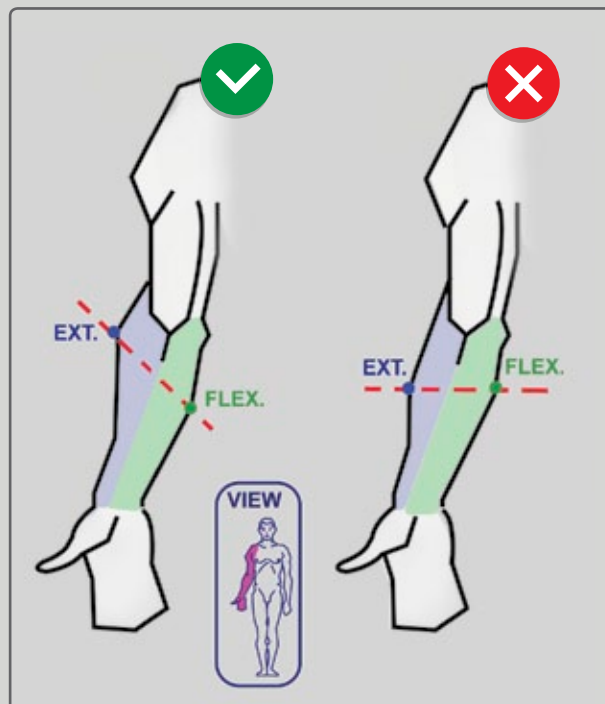
BODY SILHOUETTE APPEARS TO BEND **INWARD** RIGHT BELOW THE ELBOW DUE TO THE FLEXOR CARPI ULNARIS MUSCLE **1** POPPING **OUTWARD**.

ULNA BONE **2** REMAINS STRAIGHT.



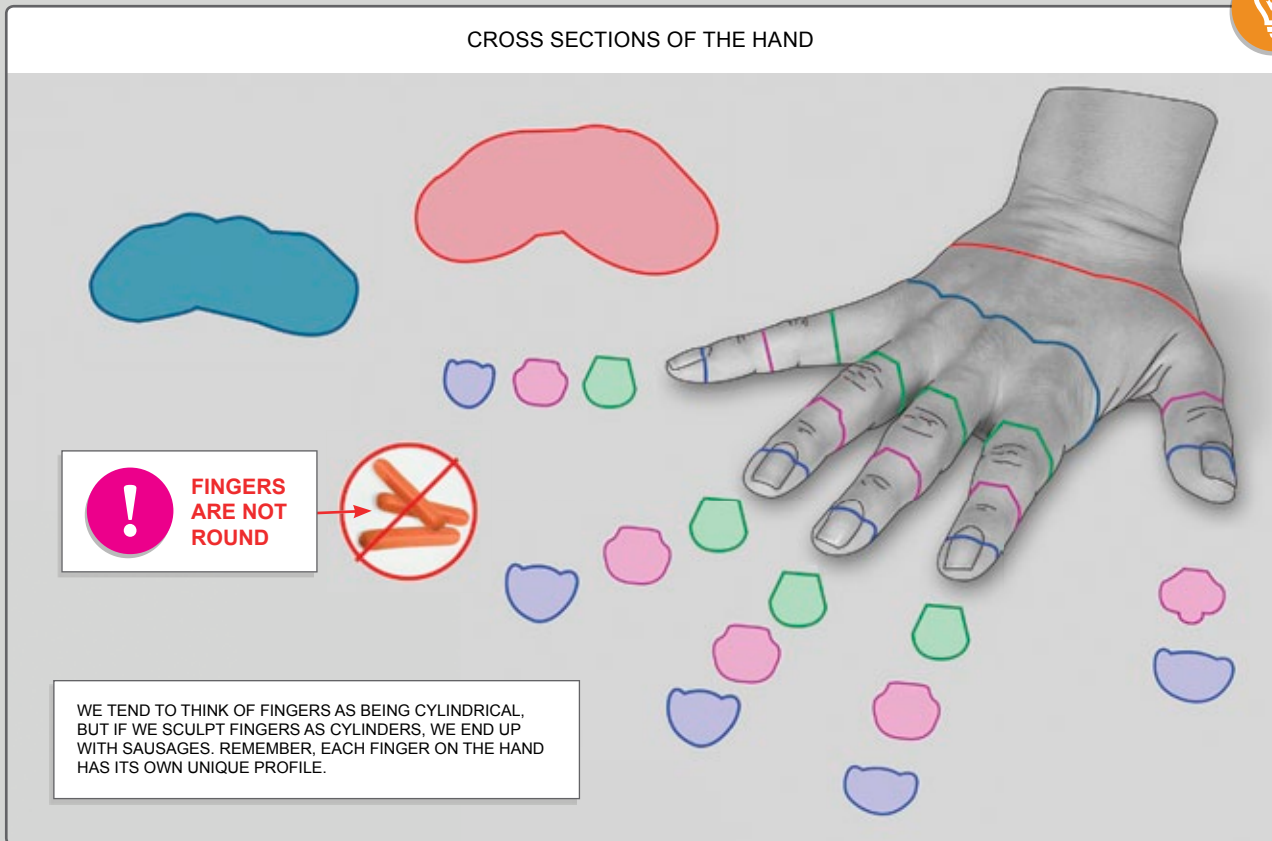
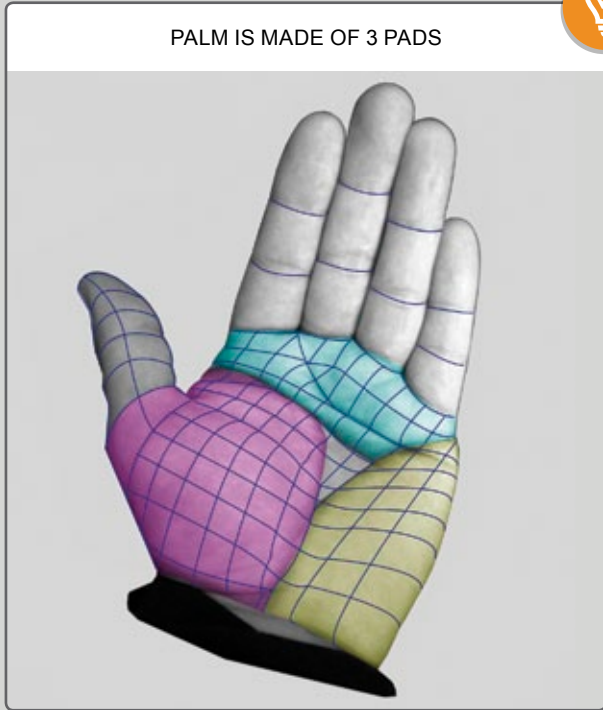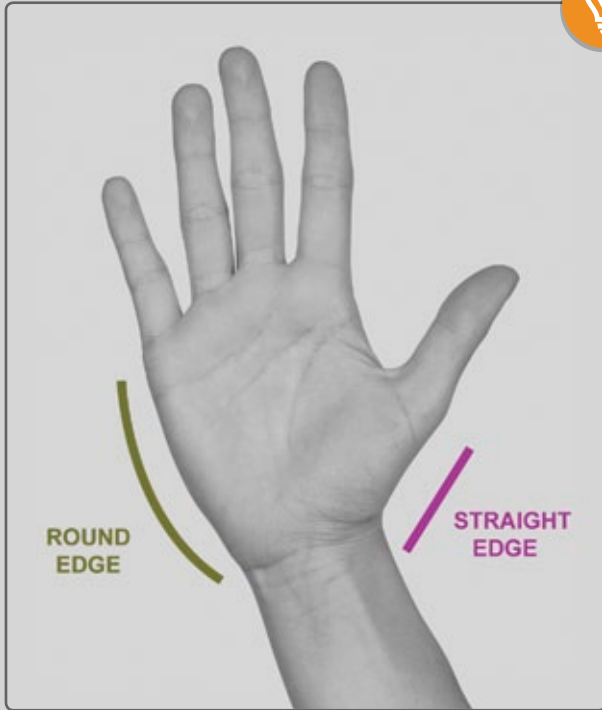
WHEN ARMS ARE HELD OUT AT THE SIDES WITH PALMS FACING FORWARD (SUPINATION), FOREARM AND HAND ARE ABOUT 5 TO 15 DEGREES AWAY FROM THE BODY. THIS IS CALLED "THE CARRYING ANGLE".

FEMALE ARMS HAVE A GREATER C.A.



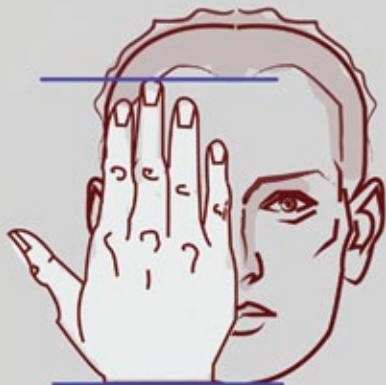THE HIGHEST POINT OF **THE EXTENSOR MUSCLES** IS LOCATED HIGHER THAN THE TOP POINT OF **THE FLEXOR MUSCLES**.

SHAPES OF THE HAND



IDEALIZED HAND PROPORTIONS

SIZE OF AN ADULT'S HAND

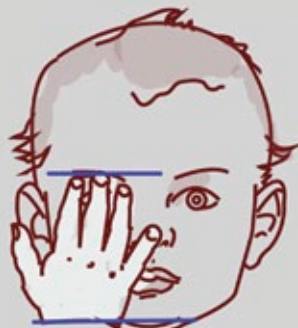

MAKE SURE YOU ARE MODELING THE HAND LARGE ENOUGH.

IDEALLY, HAND IS THE SAME SIZE AS FACE (FROM TIP OF CHIN TO HAIRLINE).



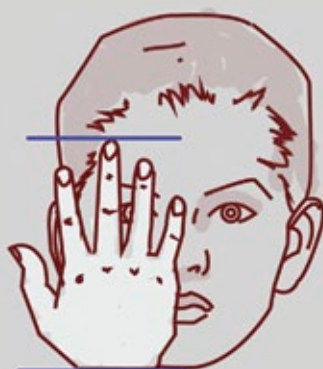BABY



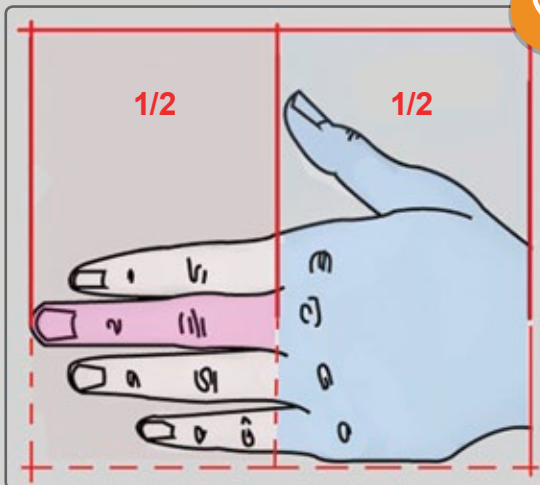
LENGTH OF HAND IS THE DISTANCE FROM CHIN TO EYEBROW LINE.



TEEN

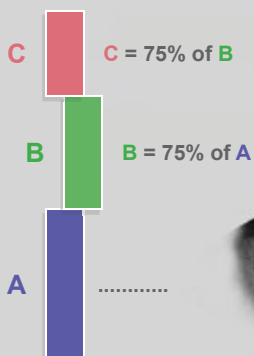


LENGTH OF HAND IS THE DISTANCE FROM CHIN TO THE MIDDLE OF FOREHEAD.

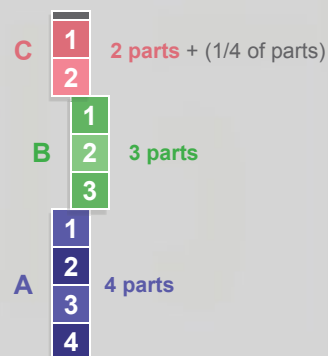


THERE ARE TWO METHODS YOU CAN USE TO CALCULATE FINGER LENGTH.

1st METHOD



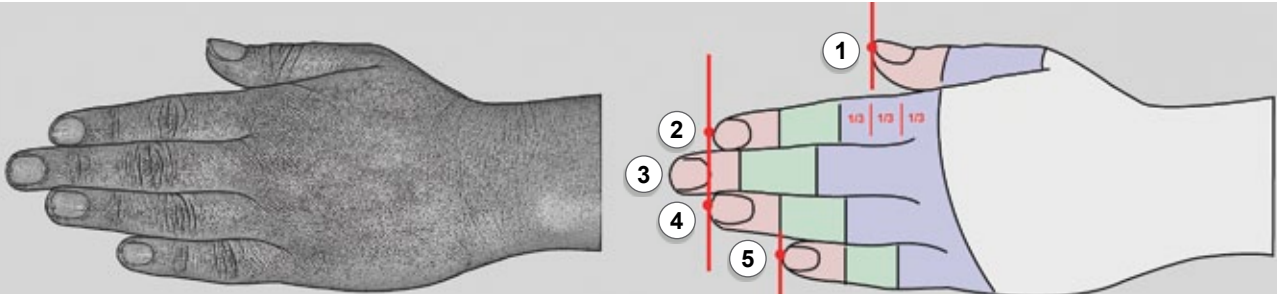
2nd METHOD (9+1/4 parts)



HAND

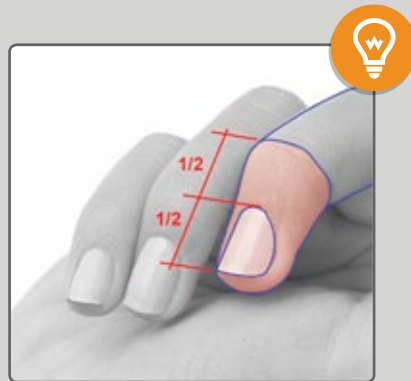
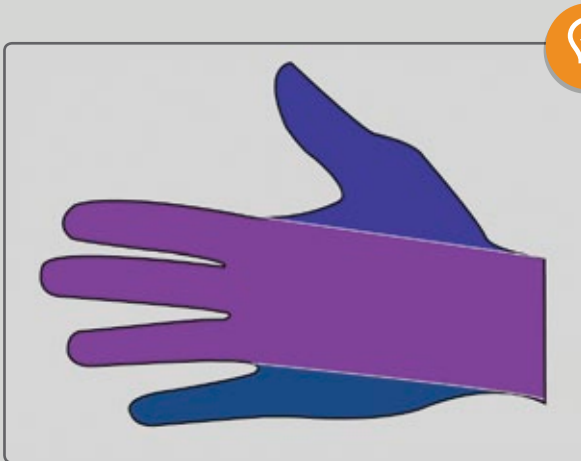


FINGER LENGTHS OF AN IDEALIZED HAND

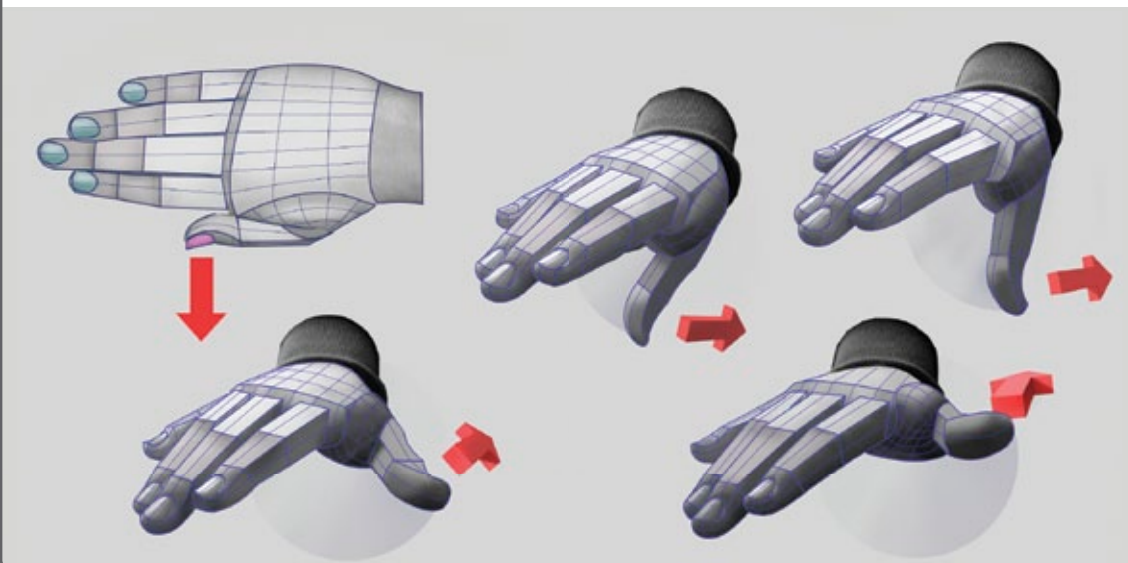


- ① THUMB DOES NOT POSSESS A MIDDLE (INTERMEDIATE) PHALANX!
- ② ③ ④ ⑤ FINGERS CONSIST OF 3 PHALANGES: PROXIMAL, MIDDLE AND DISTAL.

② = ④

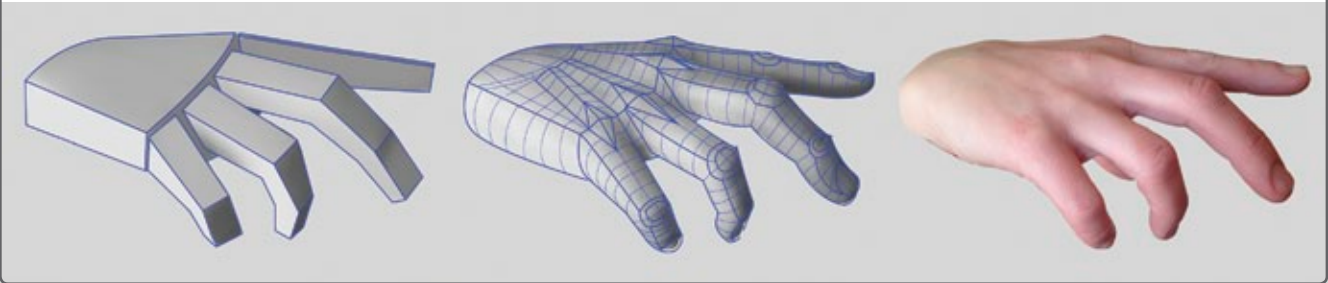


THUMB NAIL FACES A DIFFERENT DIRECTION THAN OTHER NAILS.

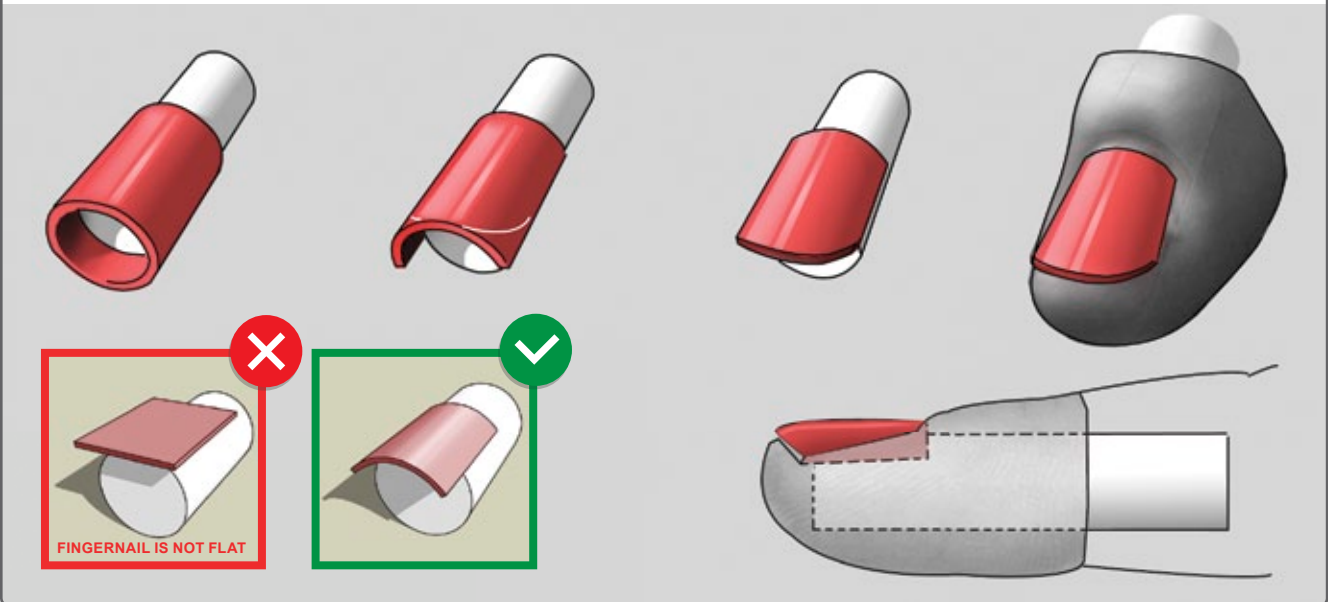


SHAPING HAND AND FINGERS

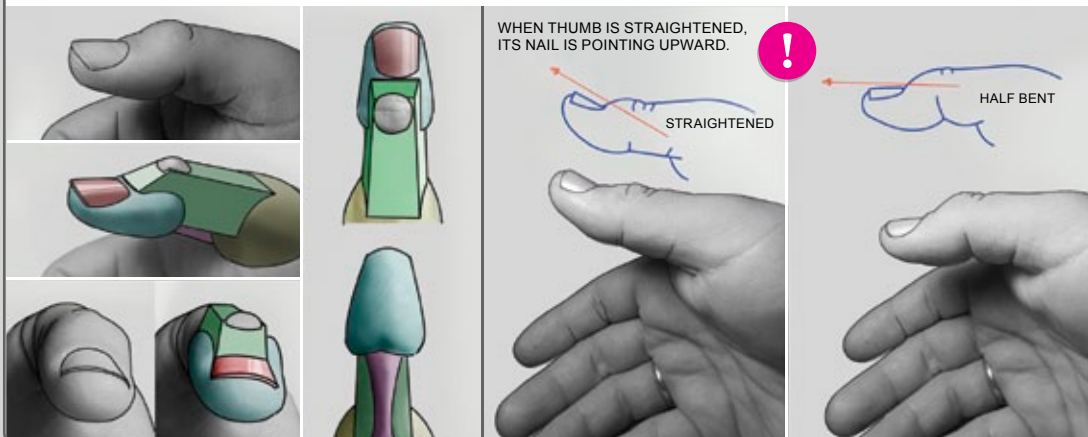
IT IS MUCH EASIER TO BEGIN MODELING FINGERS FROM SIMPLE SQUARE FORMS.



FINGERNAIL



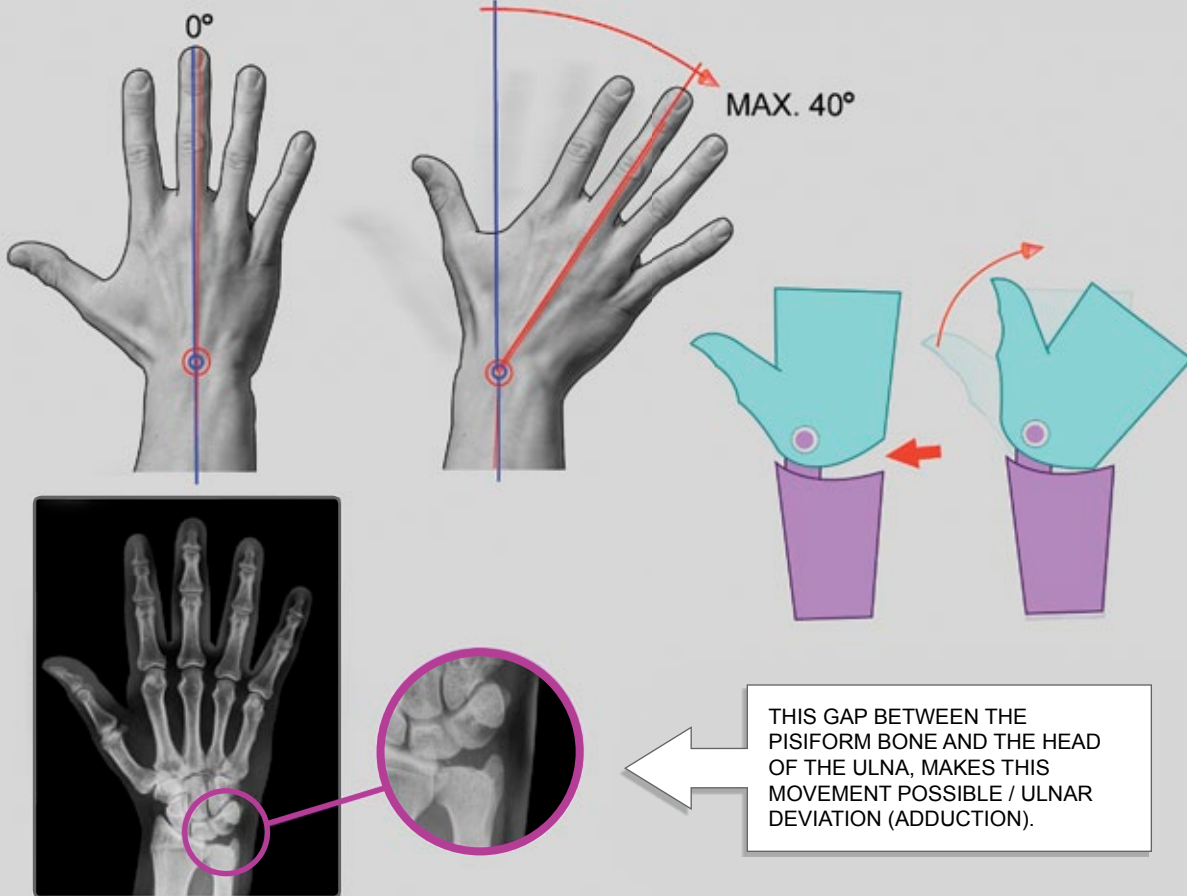
THUMB IS SHAPED DIFFERENTLY THAN OTHER FINGERS.



HAND MOVEMENTS



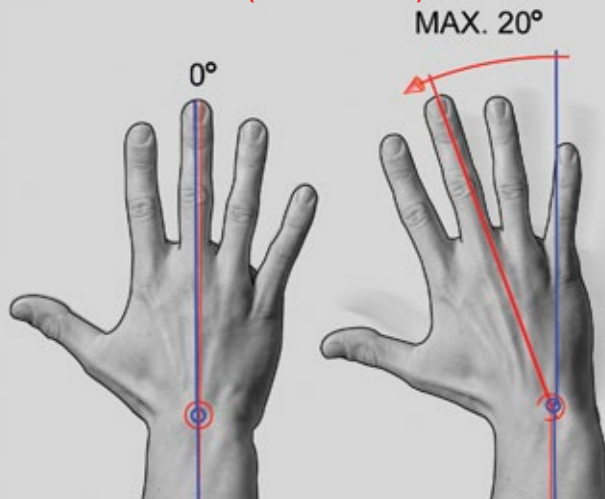
ULNAR DEVIATION (ADDUCTION)



THIS GAP BETWEEN THE PISIFORM BONE AND THE HEAD OF THE ULNA, MAKES THIS MOVEMENT POSSIBLE / ULNAR DEVIATION (ADDUCTION).

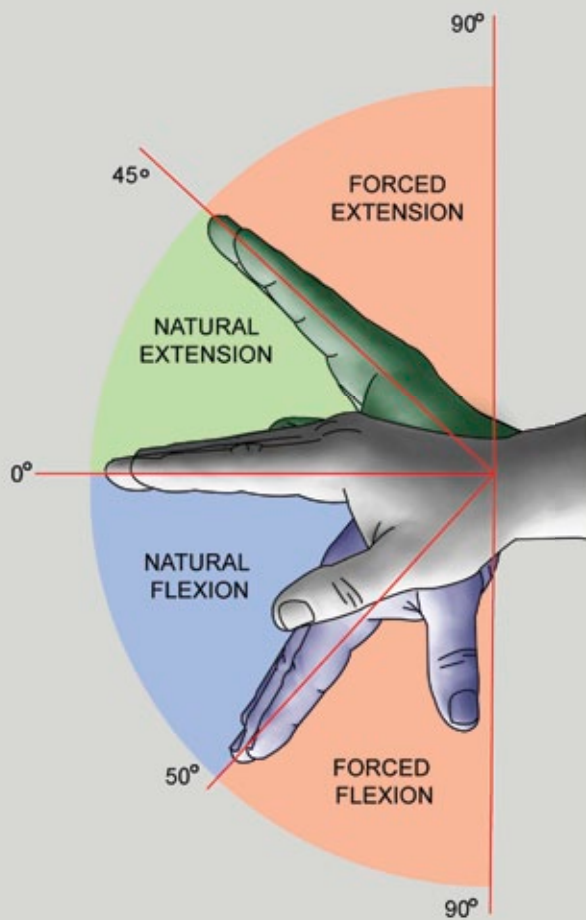
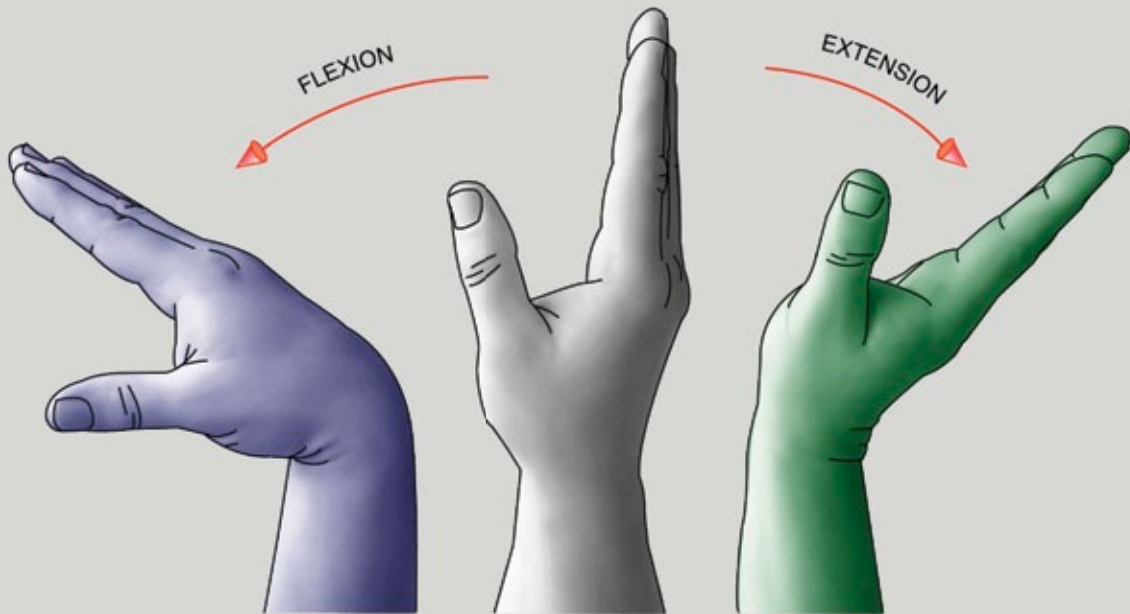


RADIAL DEVIATION (ABDUCTION)



IT'S AN UNNATURAL MOTION: THERE AREN'T ANY MUSCLES DESIGNED SPECIFICALLY TO DO THIS MOVEMENT, SO THE EFFORT COMES FROM THE FLEXOR AND EXTENSOR TENDONS. **WOULD BE BETTER TO AVOID SCULPTING THIS HAND POSITION!**

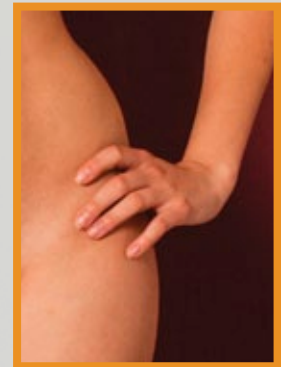WRIST POSITIONS



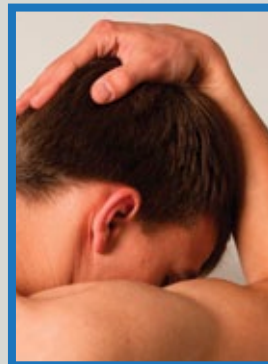EXTENSION



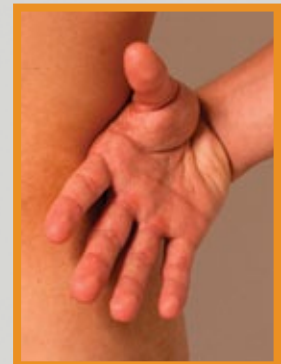FORCED EXTENSION




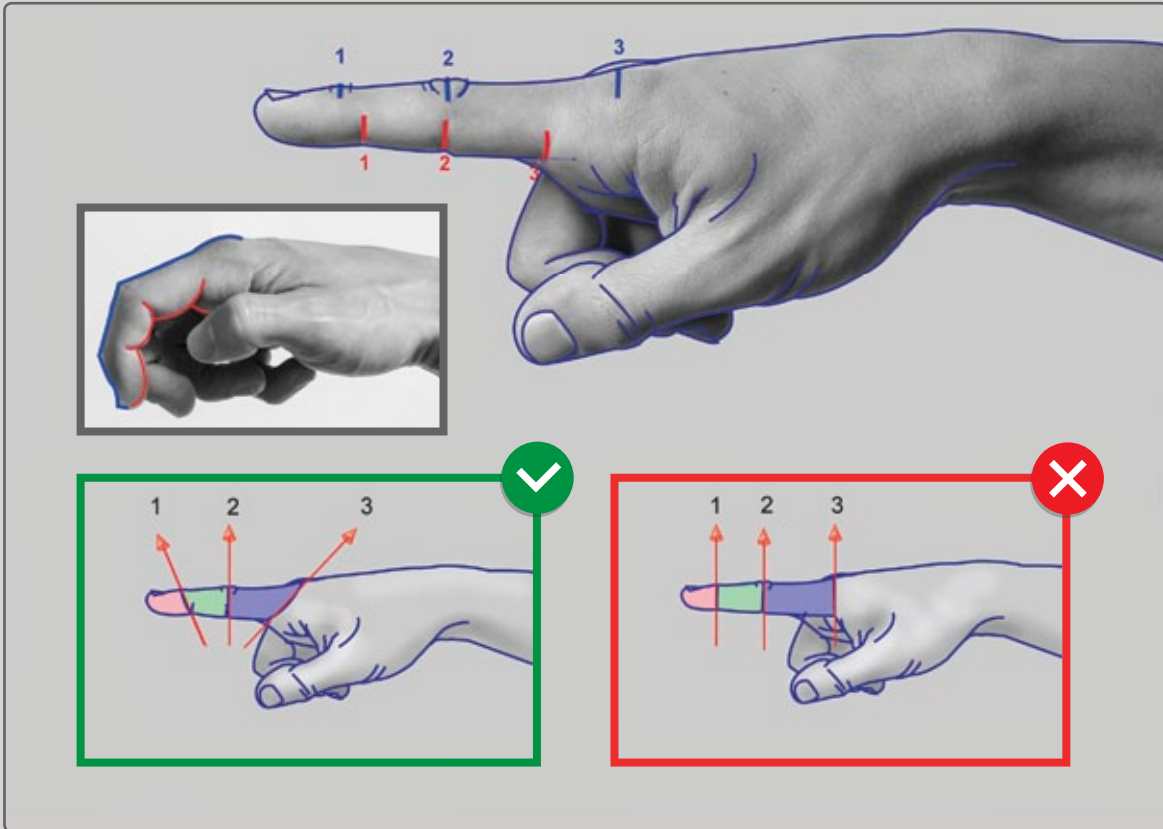
FLEXION



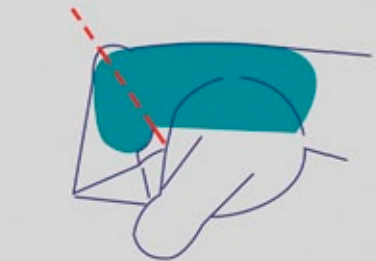
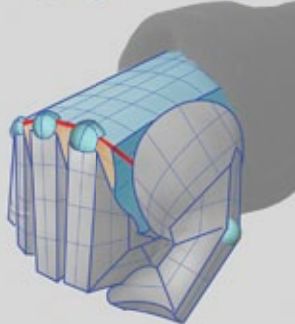
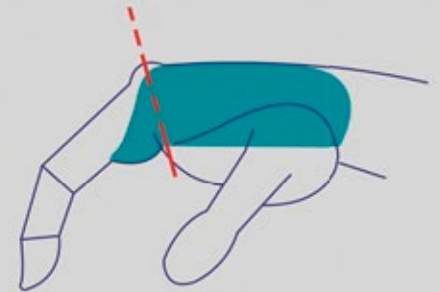
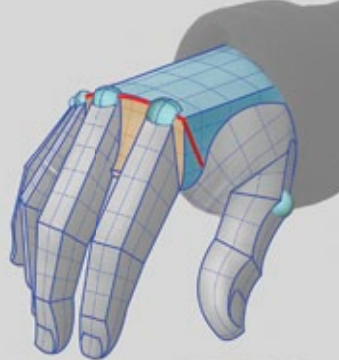
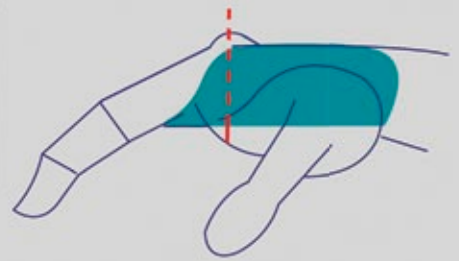
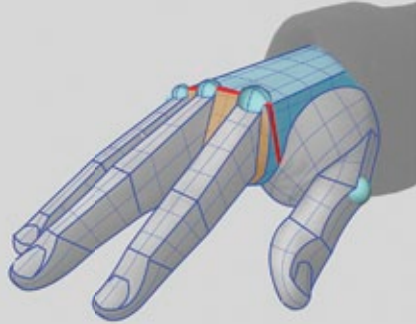
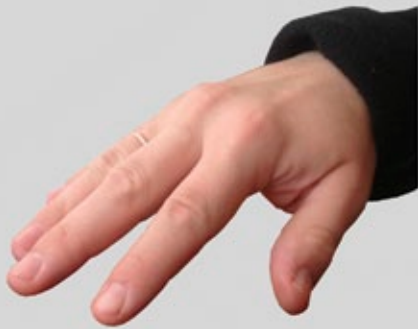FORCED FLEXION



CREASES AND GAPS OF FINGERS

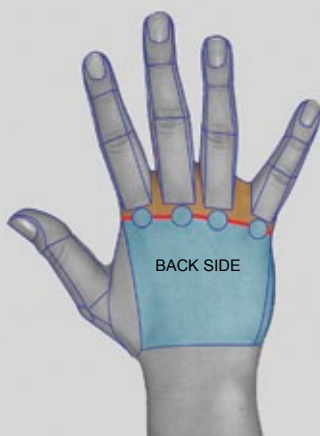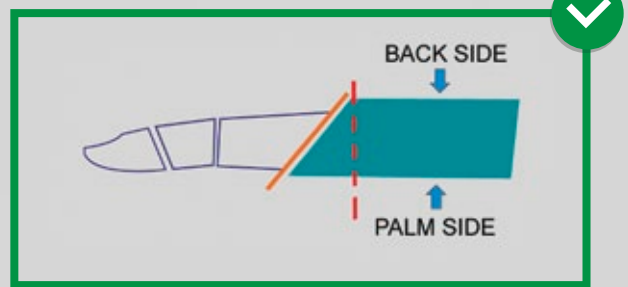


BENDING AND CONNECTION LINE OF FINGERS

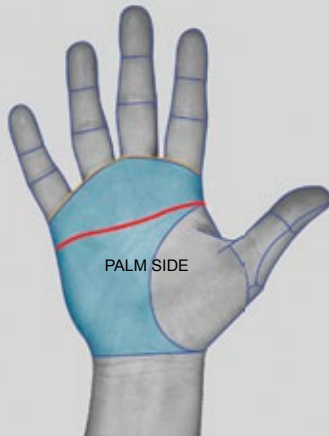


FINGERS ARE SHORTER FROM PALM SIDE OF THE HAND.

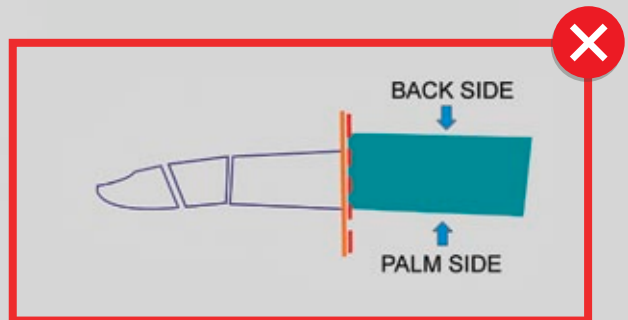
CREASE LINE ON THE PALM DOES NOT MATCH UP WITH **CONNECTION LINE** WHERE FINGERS JOIN **THE BODY OF THE HAND**.



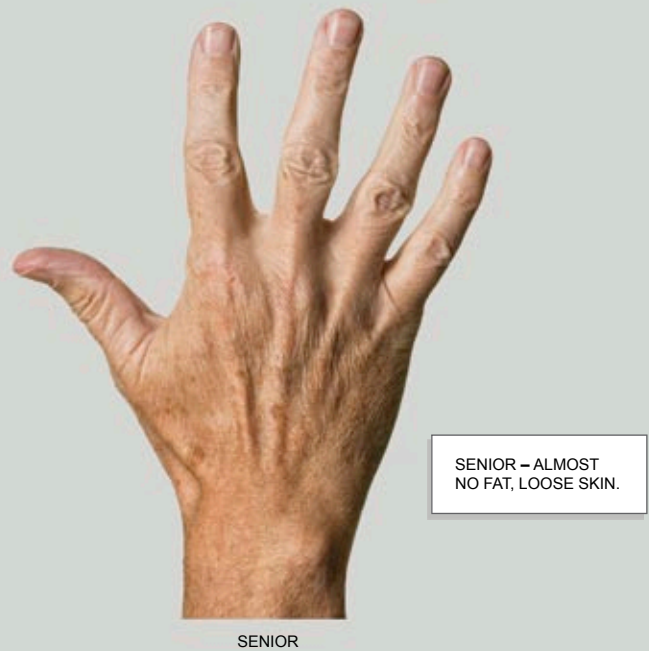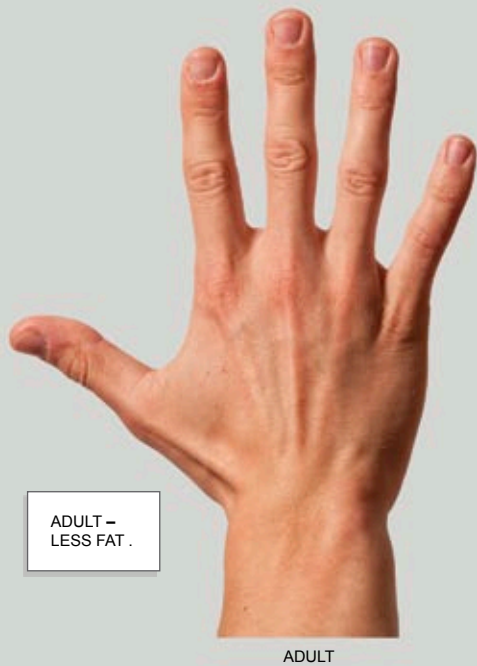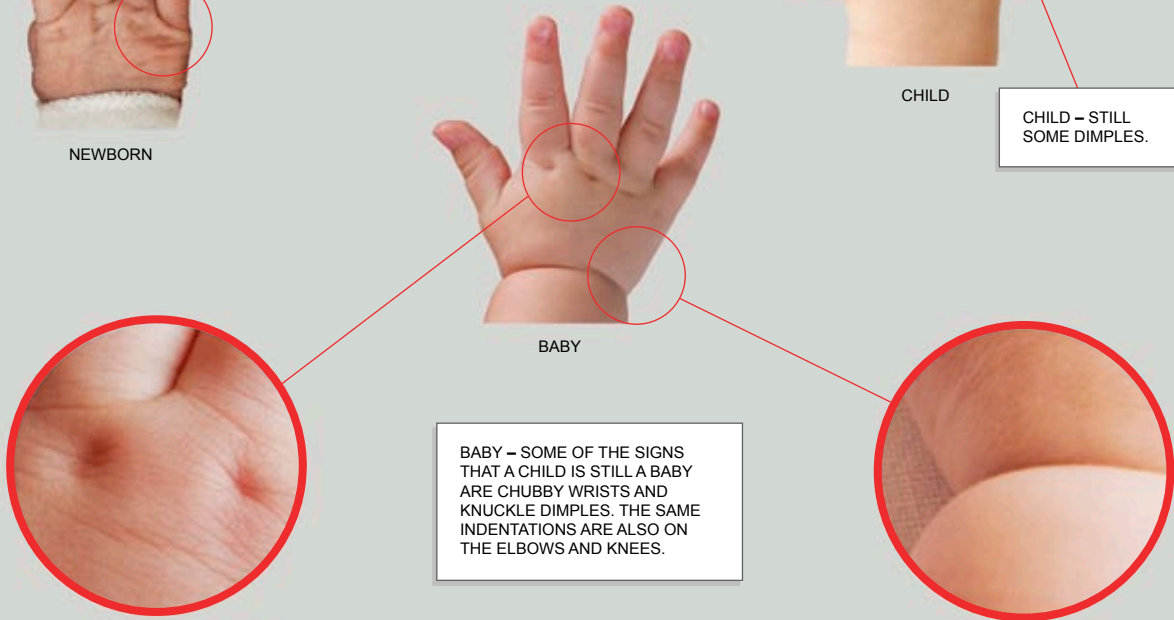
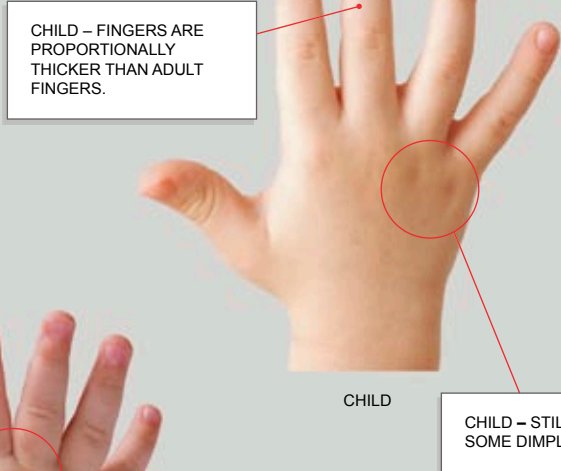
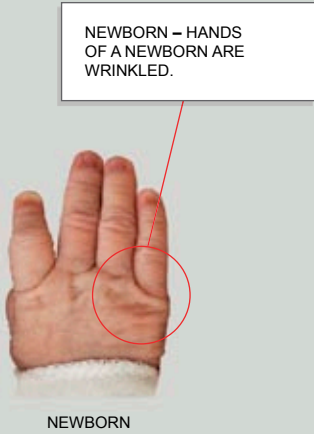BACK SIDE



PALM SIDE

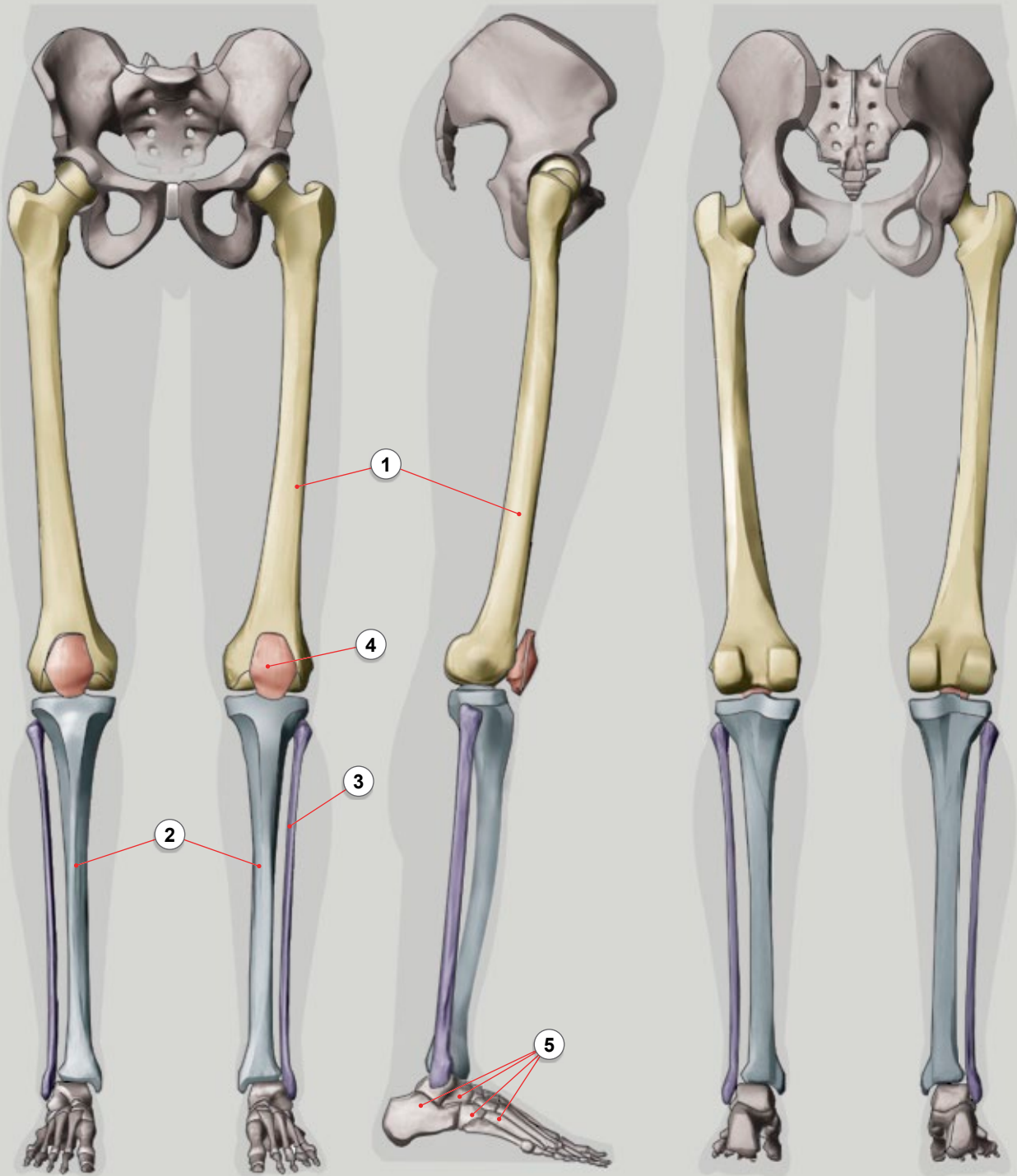


HOW HANDS AGE



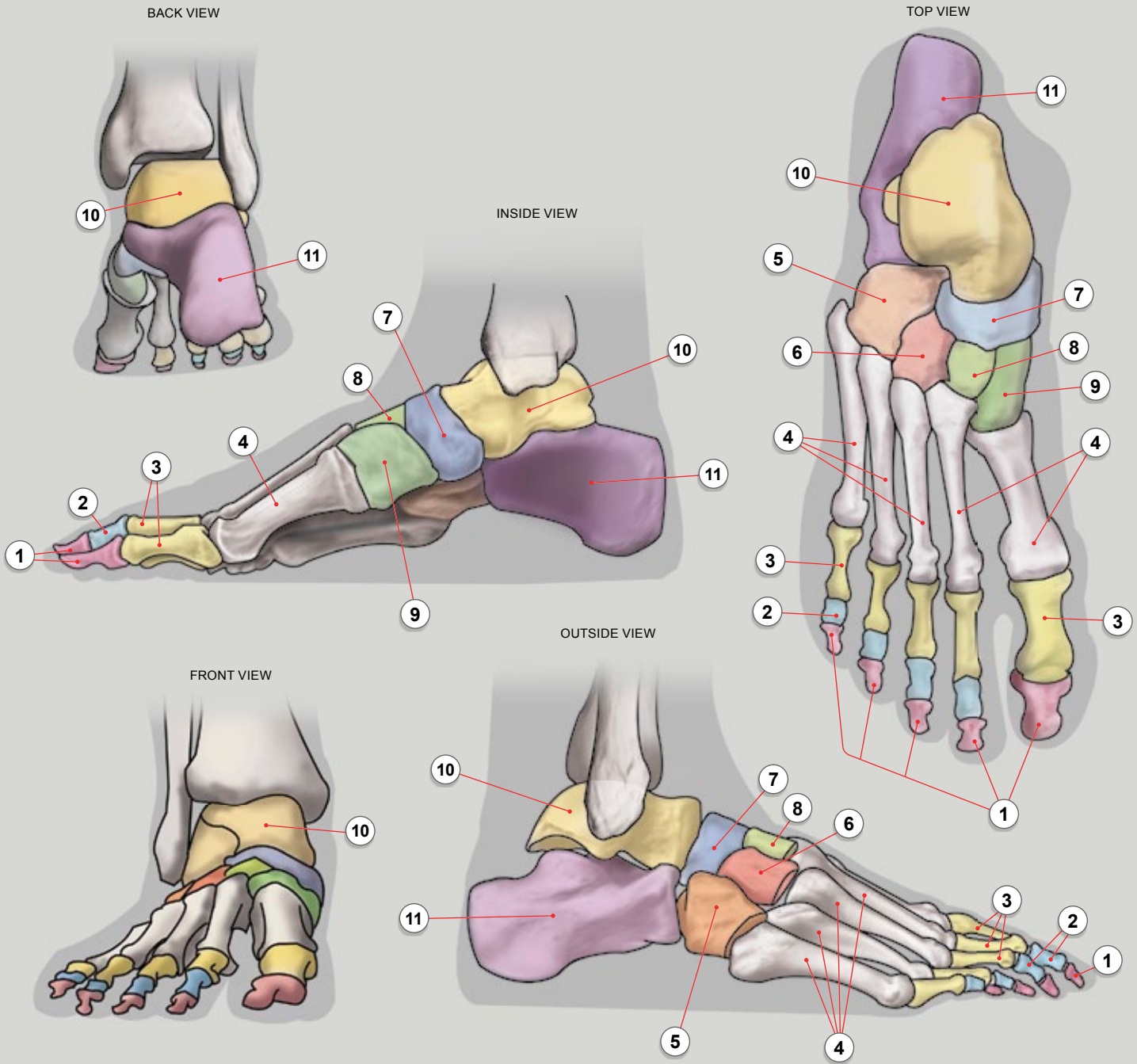


BONES OF LOWER LIMB



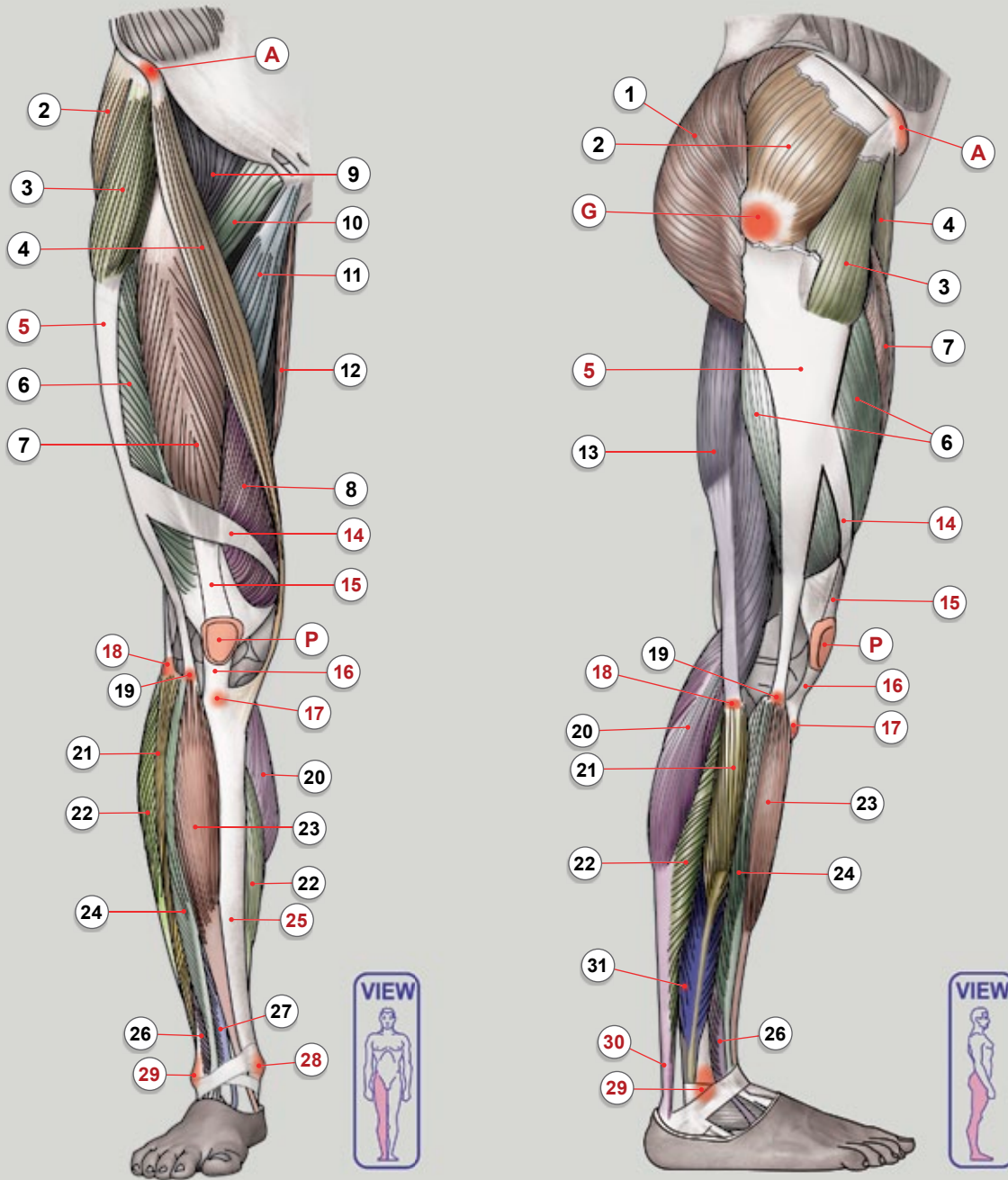
- 1 FEMUR
- 2 TIBIA
- 3 FIBULA
- 4 KNEE CAP (patella)
- 5 BONES OF THE FOOT

BONES OF THE FOOT



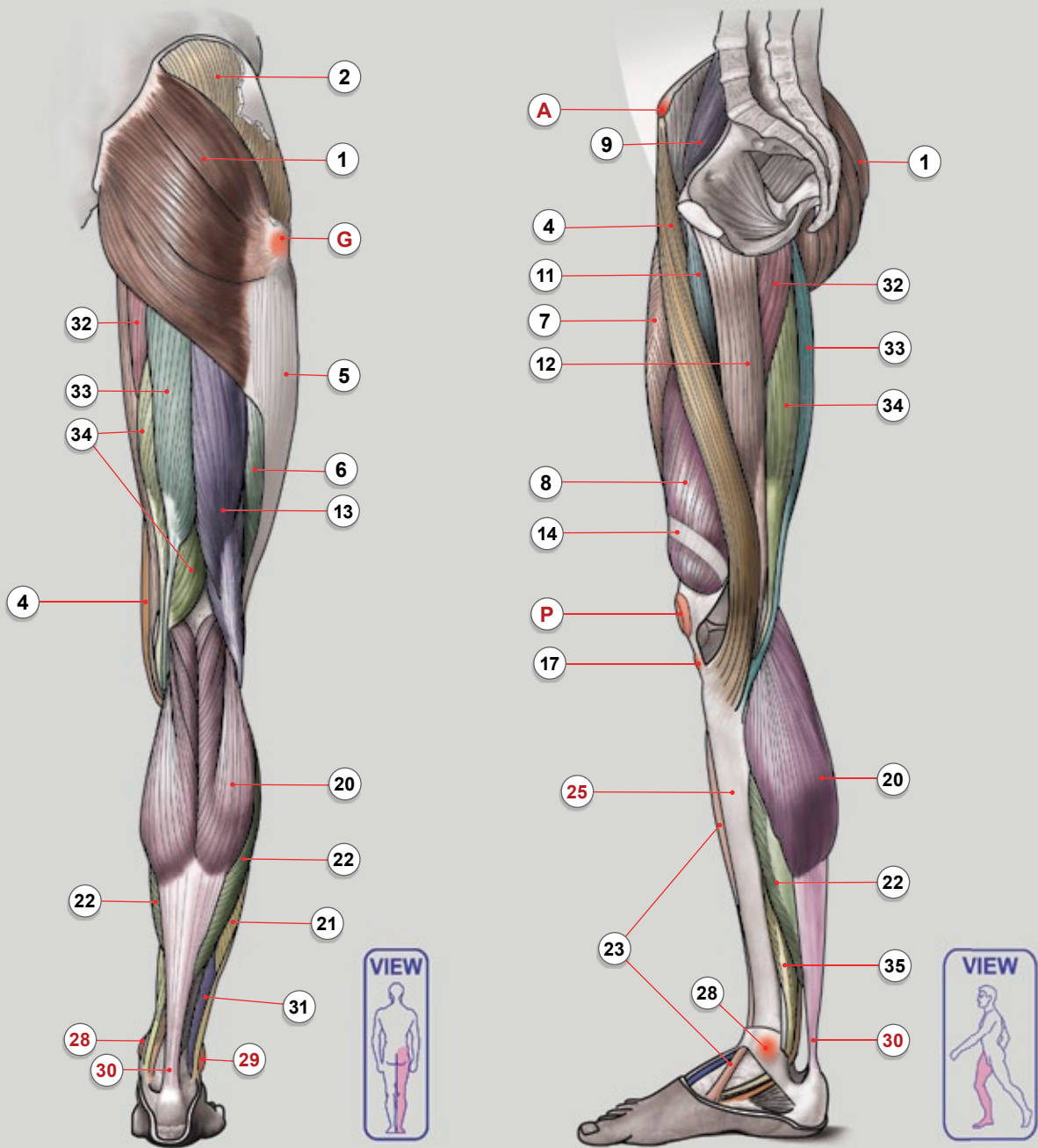
- | | | | | | |
|---|--------------------|---|------------------------|----|-----------------------|
| 1 | DISTAL PHALANGES | 5 | CUBOID | 9 | MEDIAL CUNEIFORM |
| 2 | MIDDLE PHALANGES | 6 | LATERAL CUNEIFORM | 10 | TALUS |
| 3 | PROXIMAL PHALANGES | 7 | NAVICULAR | 11 | HEEL BONE (calcaneus) |
| 4 | METATARSAL BONES | 8 | INTERMEDIATE CUNEIFORM | | |

MUSCLES OF LOWER LIMB



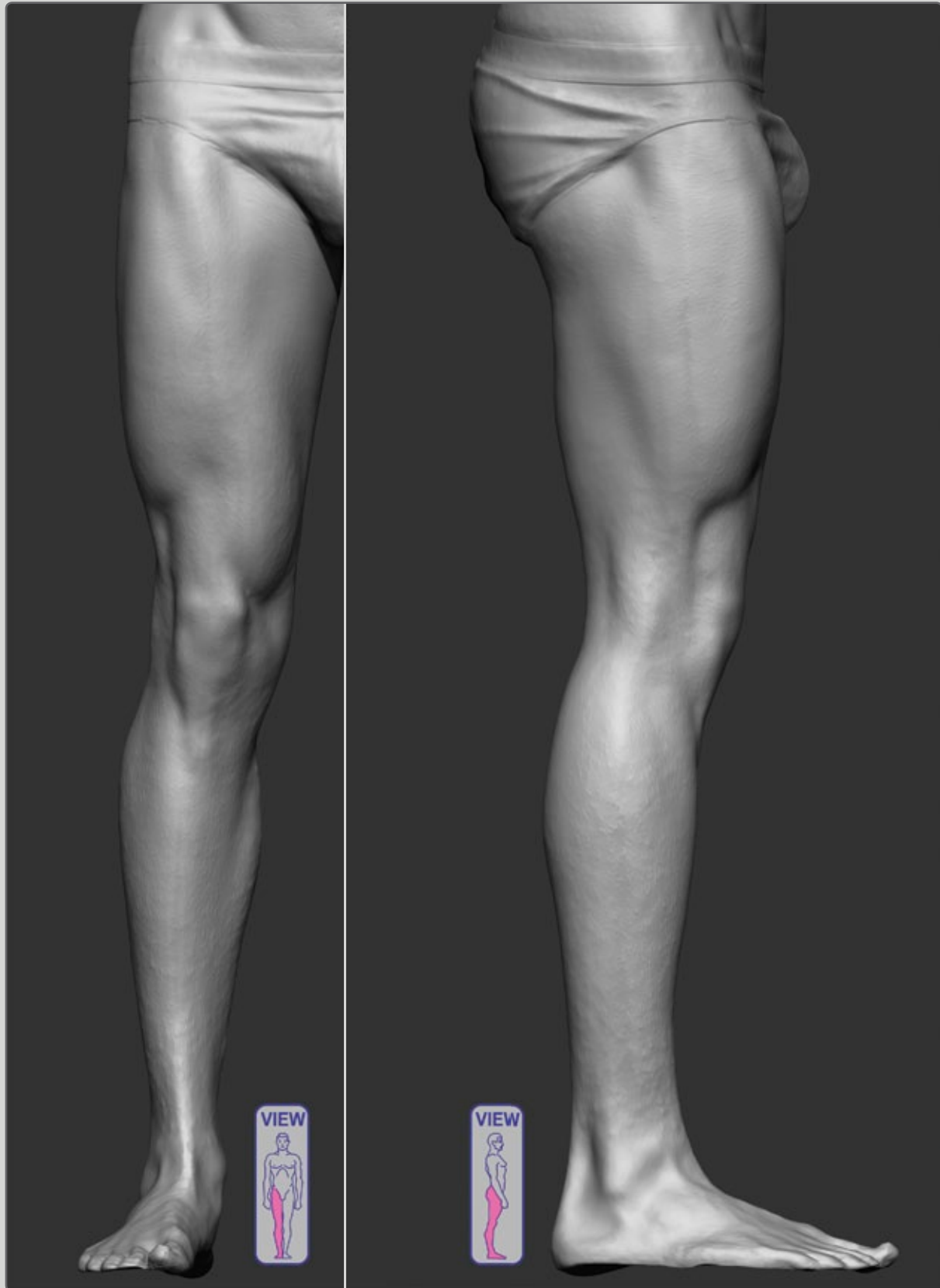A A.S.I.S.	5 ILIOTIBIAL BAND	12 GRACILIS
G GREATER TROCHANTER	6 VASTUS LATERALIS	13 BICEPS FEMORIS
P KNEE CAP (PATELLA)	7 RECTUS FEMORIS	14 RICHER'S BAND
1 GLUTEUS MAXIMUS	8 VASTUS MEDIALIS	15 QUADRICEPS TENDON
2 GLUTEUS MEDIUS	9 ILIOPSOAS	16 PATELLAR LIGAMENT
3 TENSOR FASCIAE LATAE	10 PECTINEUS	17 TIBIAL TUBEROSITY
4 SARTORIUS	11 ADDUCTOR LONGUS	18 HEAD OF FIBULA

MUSCLES OF LOWER LIMB

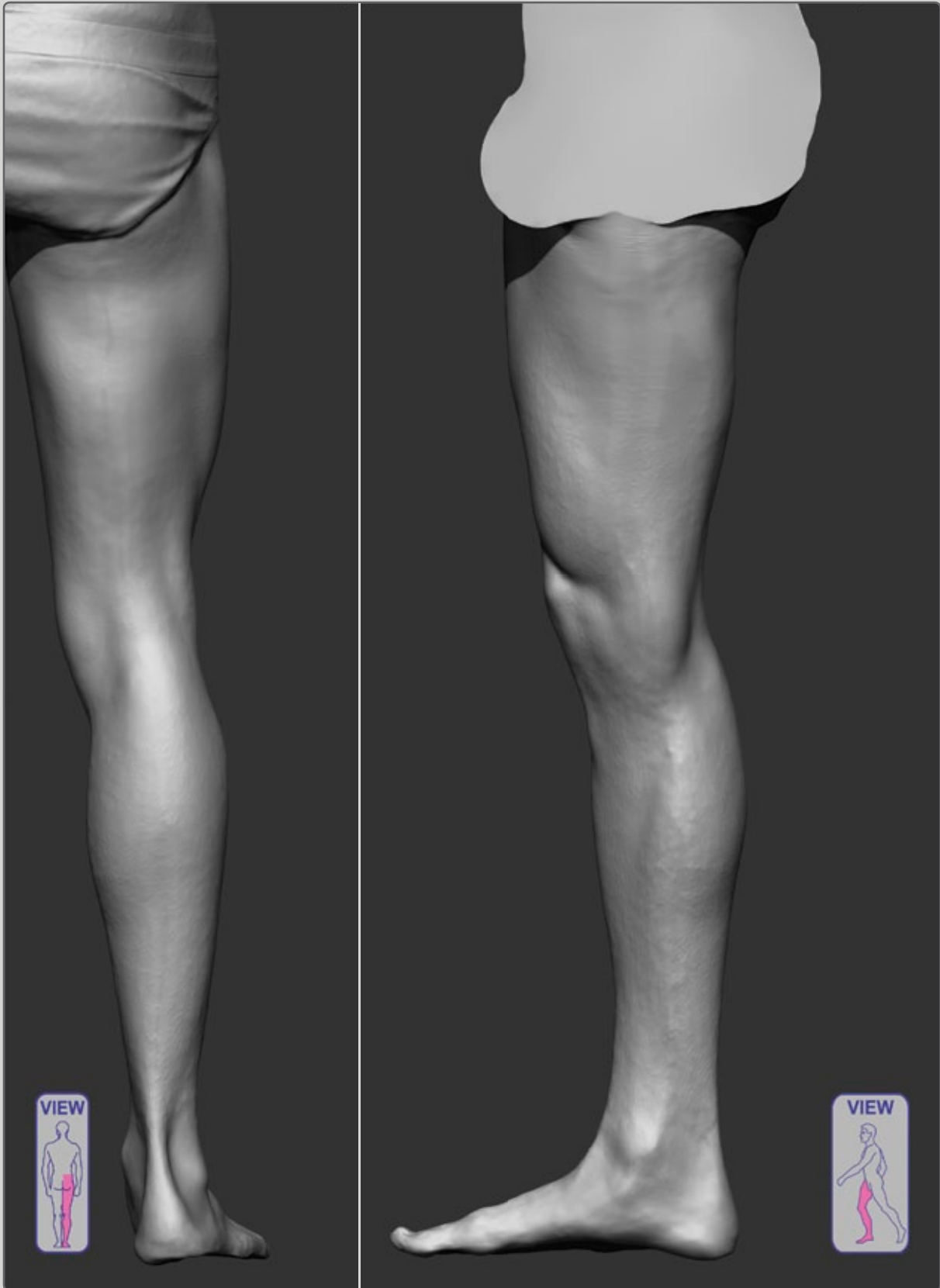


- | | | |
|-------------------------------------|--|-----------------------------------|
| 19 LATERAL TIBIAL CONDYLE | 25 MEDIAL SURFACE OF TIBIA | 31 PERONEUS BREVIS |
| 20 GASTROCNEMIUS | 26 PERONEUS TERTIUS | 32 ADDUCTOR MAGNUS |
| 21 PERONEUS LONGUS | 27 EXTENSOR HALLUCIS LONGUS | 33 SEMITENDINOSUS |
| 22 SOLEUS | 28 MEDIAL ANKLE (M. MALLEOLUS) | 34 SEMIMEMBRANOSUS |
| 23 TIBIALIS ANTERIOR | 29 LATERAL ANKLE (L. MALLEOLUS) | 35 FLEXOR DIGITORUM LONGUS |
| 24 EXTENSOR DIGITORUM LONGUS | 30 ACHILLES TENDON | |

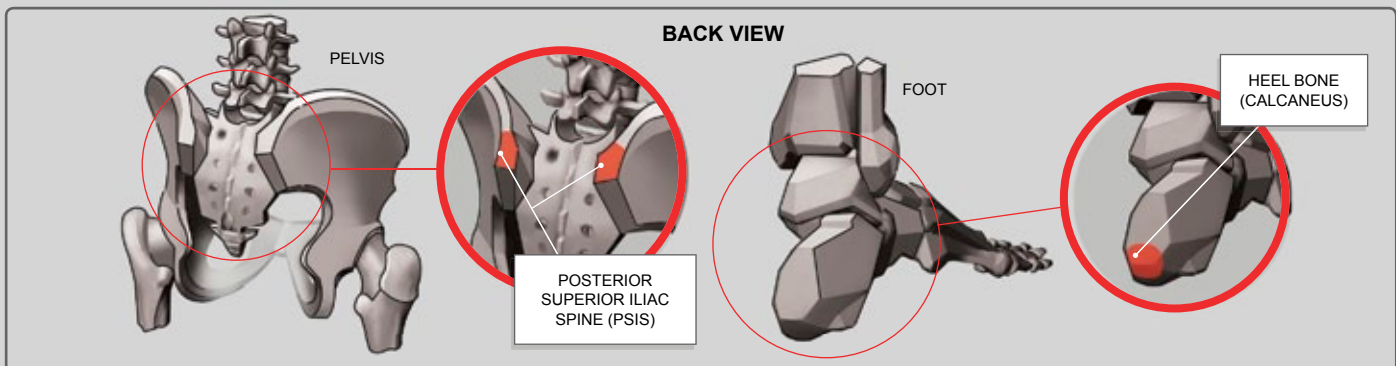
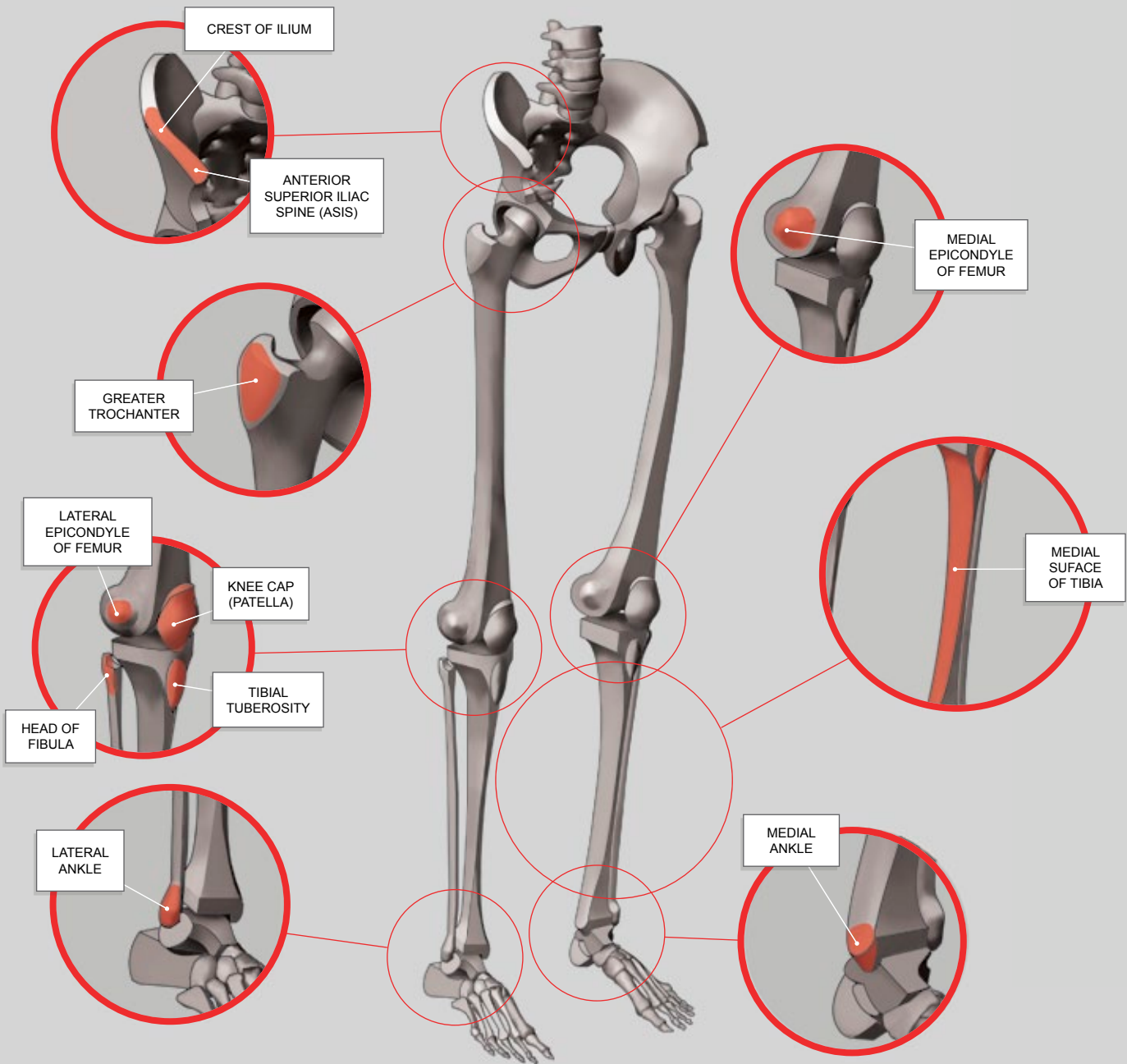
3D SCAN OF RIGHT LEG



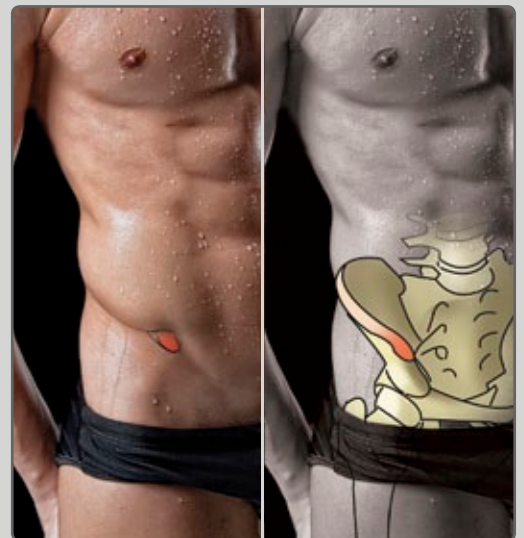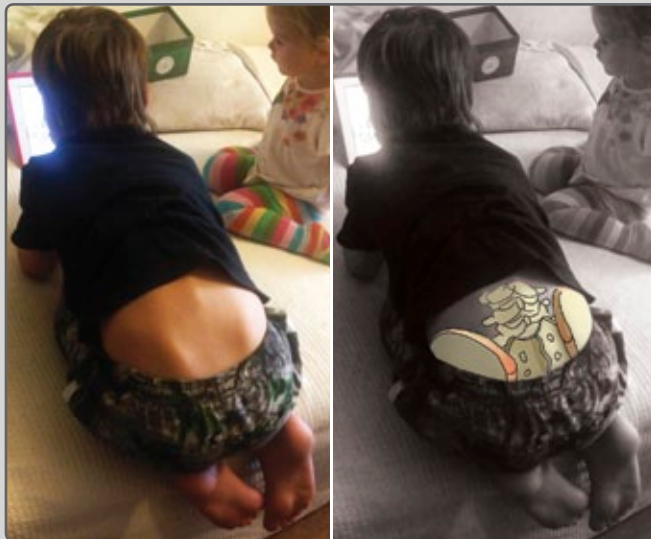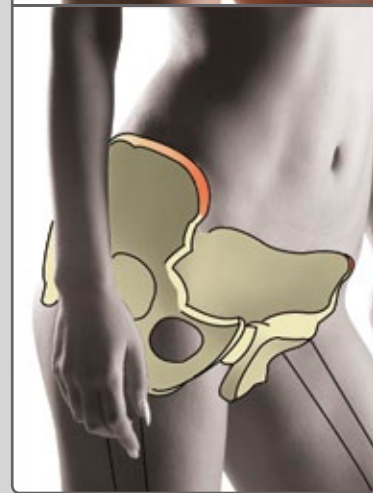
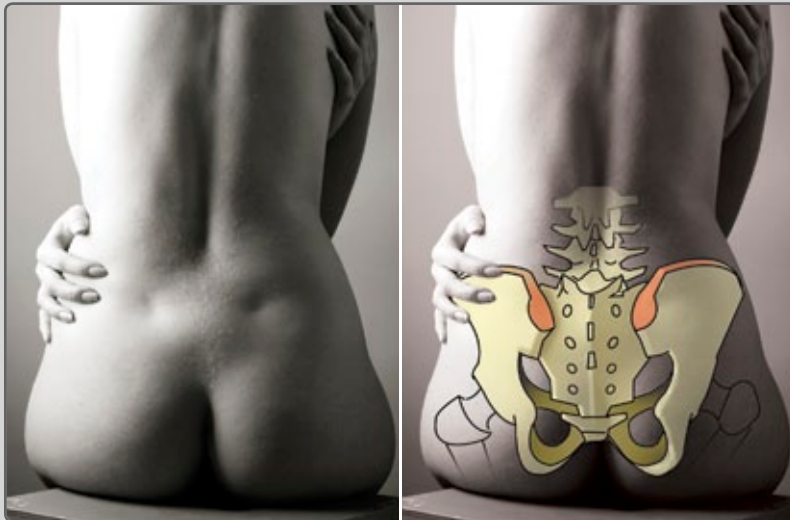
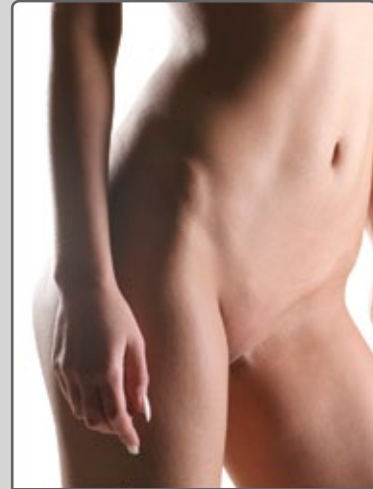
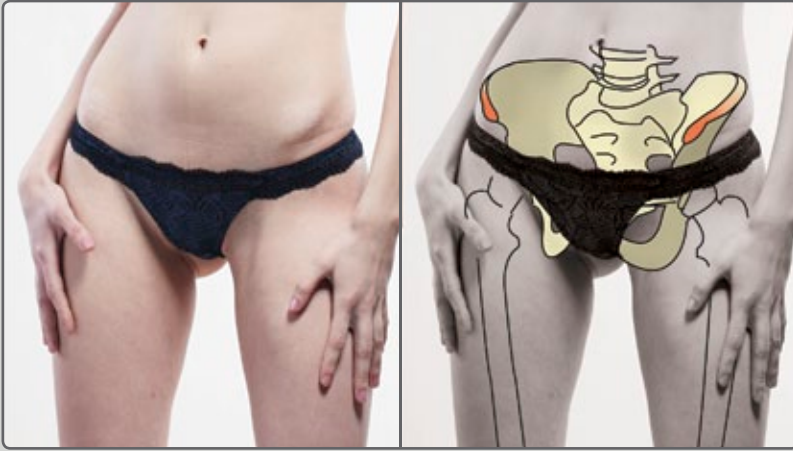3D SCAN OF RIGHT LEG



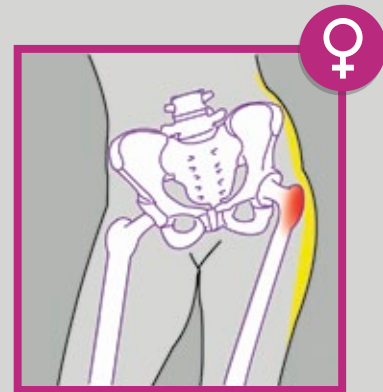
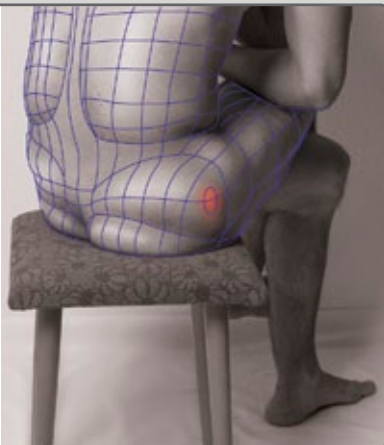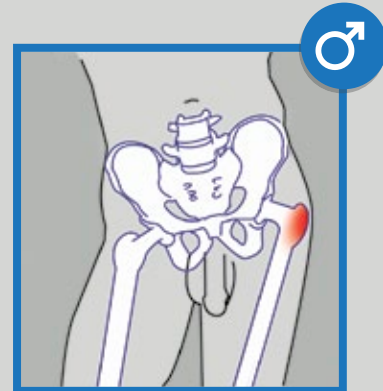
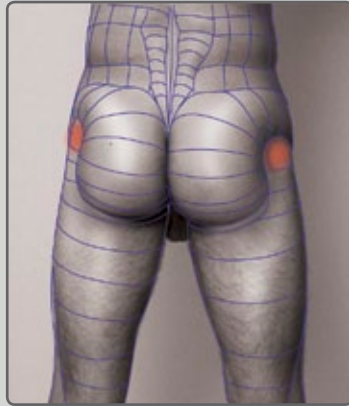
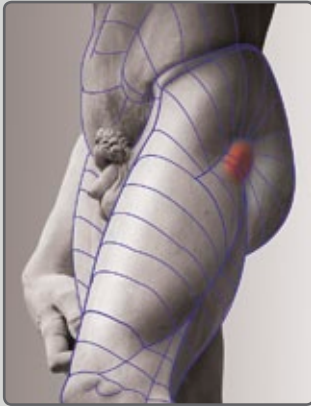
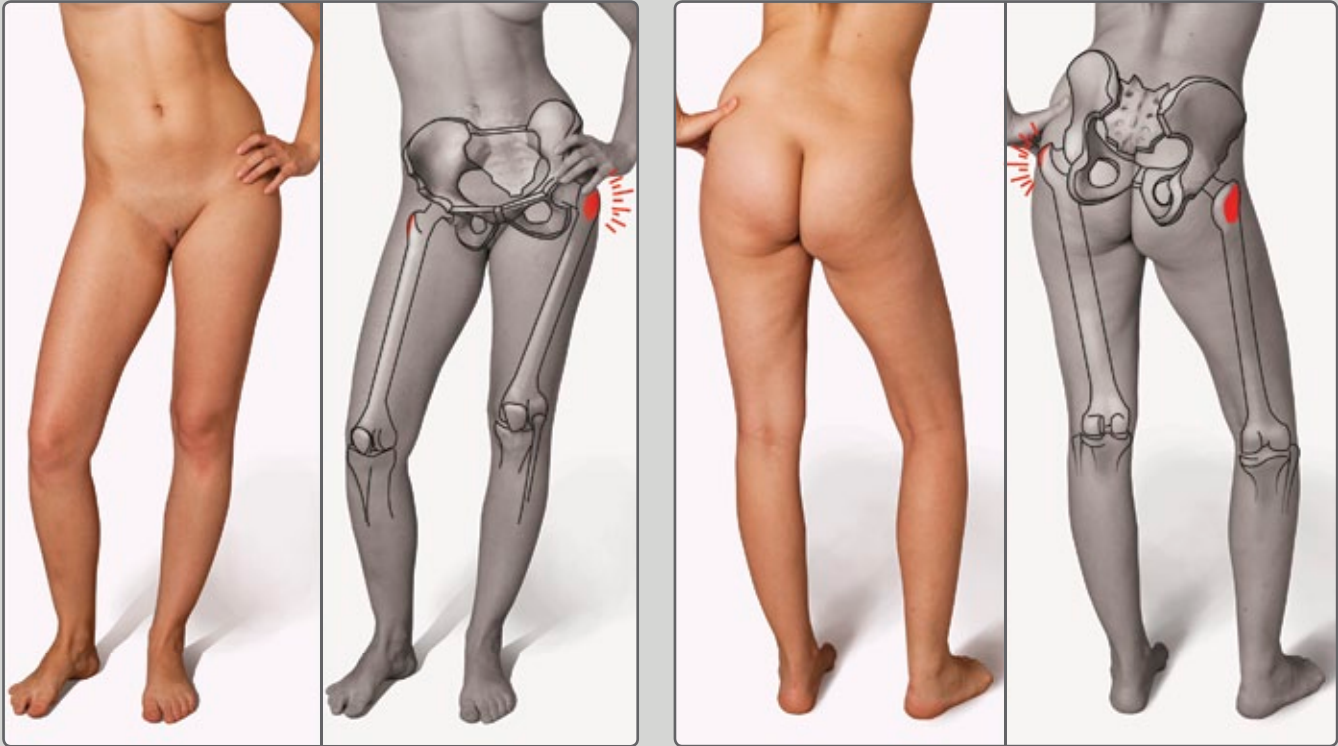
BONY LANDMARKS OF LOWER LIMB



BONY LANDMARKS OF PELVIS

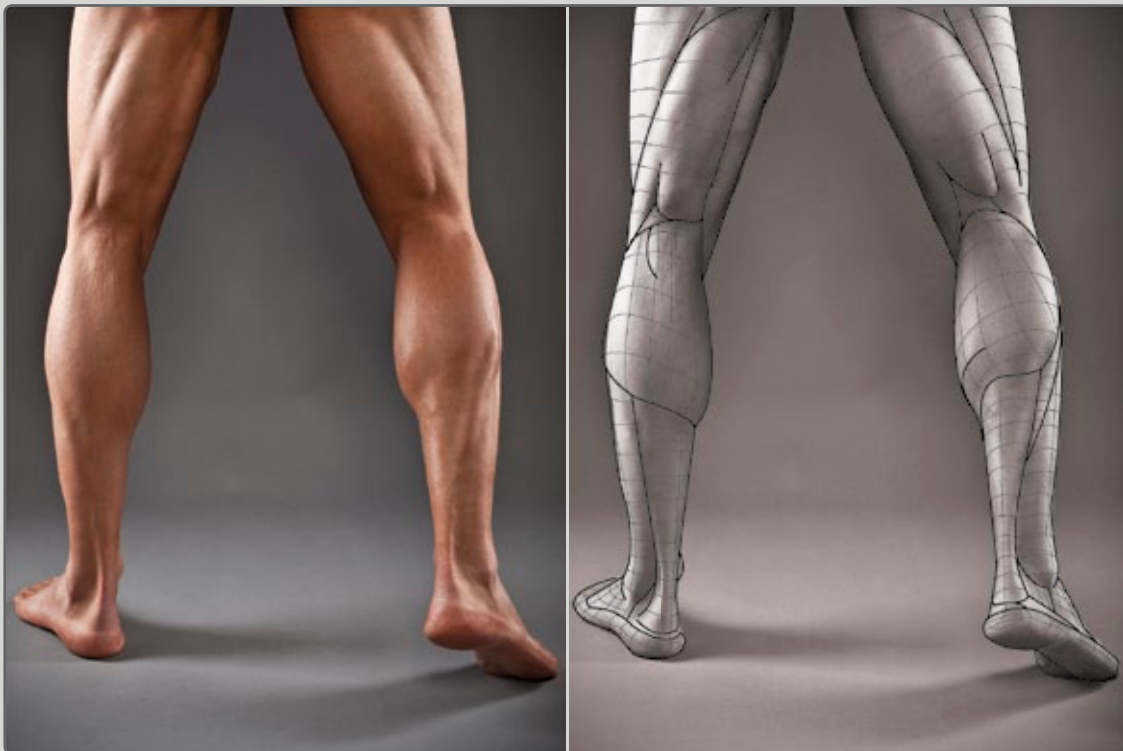
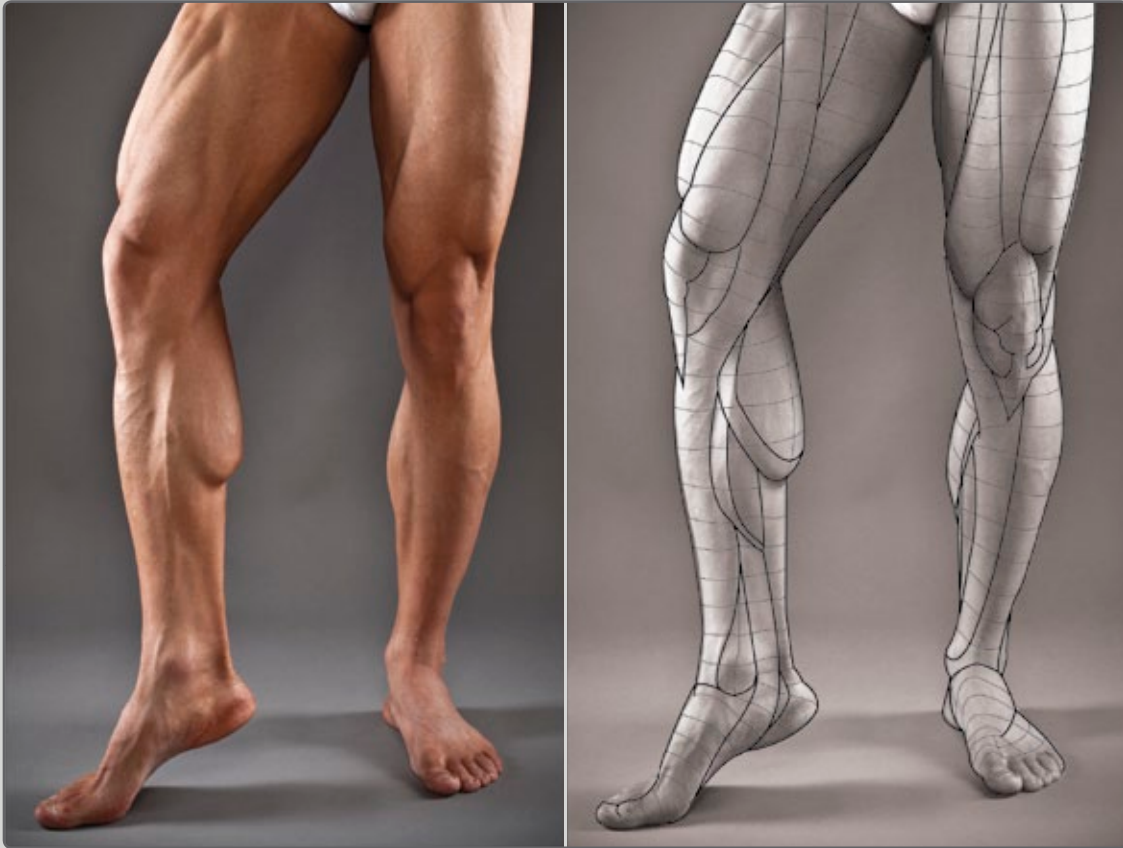
BONY LANDMARKS OF LOWER LIMB
GREATER TROCHANTER



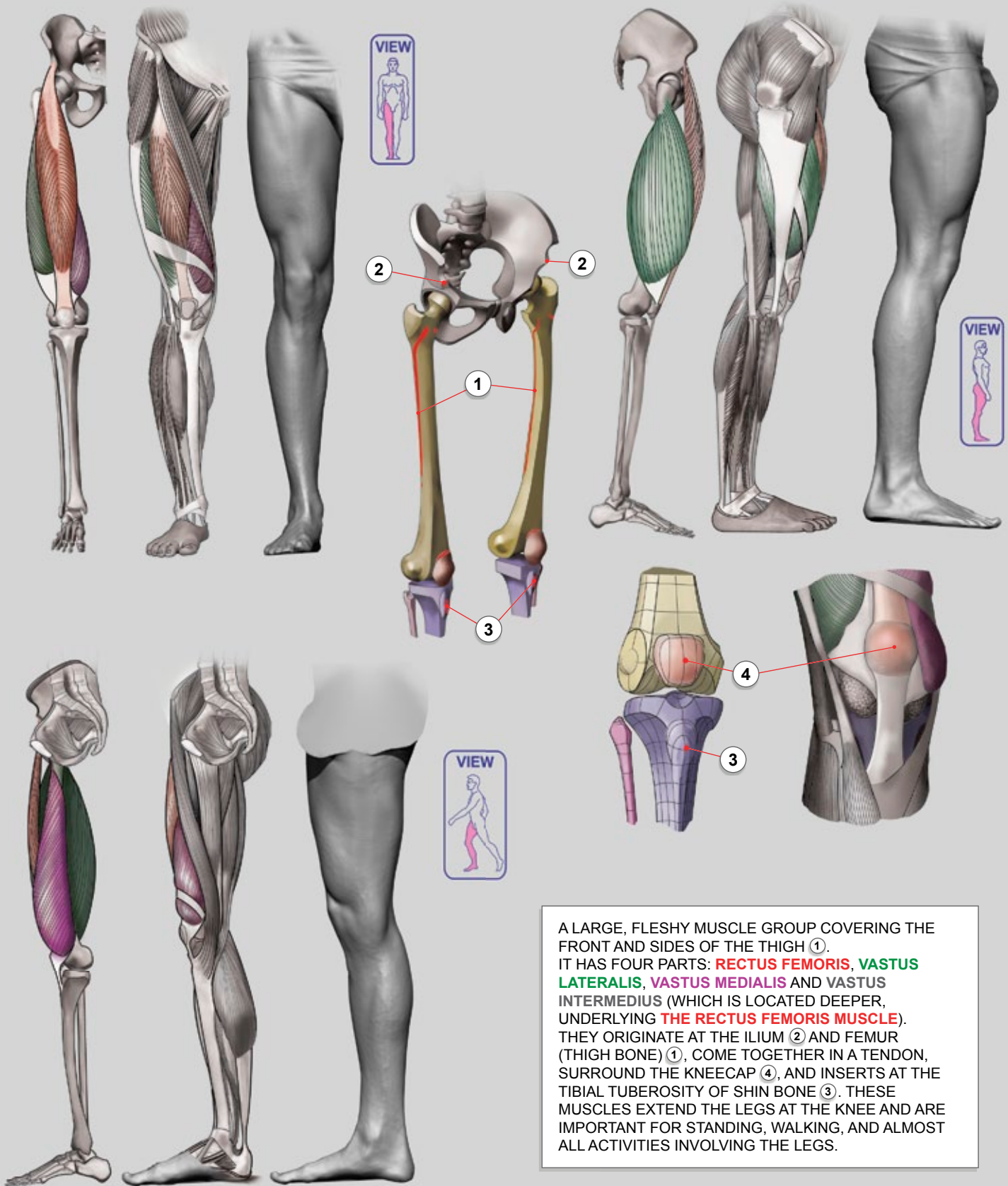
IN FEMALE HIP, **SUBCUTANEOUS FAT** COVERS **GT** AT THE TOP OF FEMUR AND THEREFORE MAKES IT LESS PROMINENT.

MALE LEG SHAPES



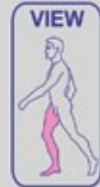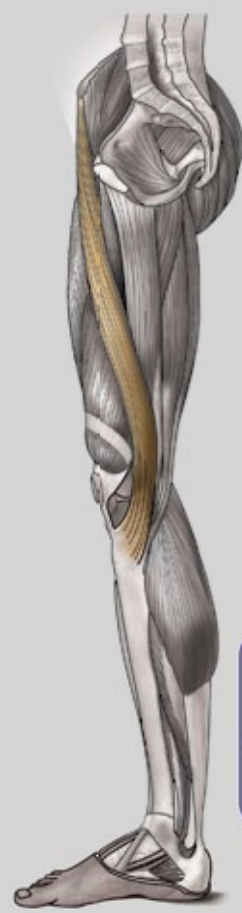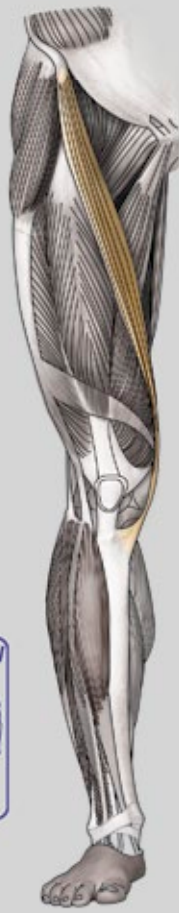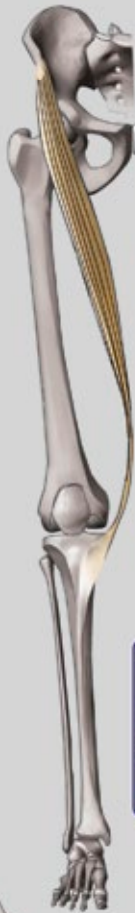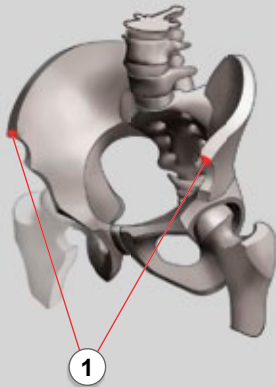

QUADS

(QUADRICEPS FEMORIS MUSCLE)



A LARGE, FLESHY MUSCLE GROUP COVERING THE FRONT AND SIDES OF THE THIGH ①. IT HAS FOUR PARTS: **RECTUS FEMORIS**, **VASTUS LATERALIS**, **VASTUS MEDIALIS** AND VASTUS INTERMEDIUS (WHICH IS LOCATED DEEPER, UNDERLYING **THE RECTUS FEMORIS MUSCLE**). THEY ORIGINATE AT THE ILIUM ② AND FEMUR (THIGH BONE) ①, COME TOGETHER IN A TENDON, SURROUND THE KNEECAP ④, AND INSERTS AT THE TIBIAL TUBEROSITY OF SHIN BONE ③. THESE MUSCLES EXTEND THE LEGS AT THE KNEE AND ARE IMPORTANT FOR STANDING, WALKING, AND ALMOST ALL ACTIVITIES INVOLVING THE LEGS.

SARTORIUS MUSCLE

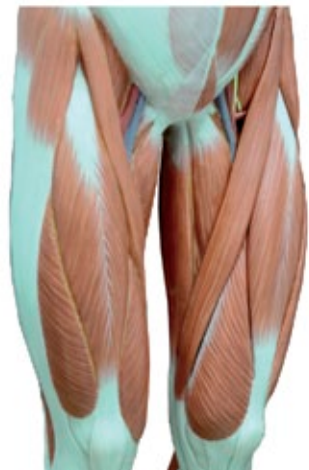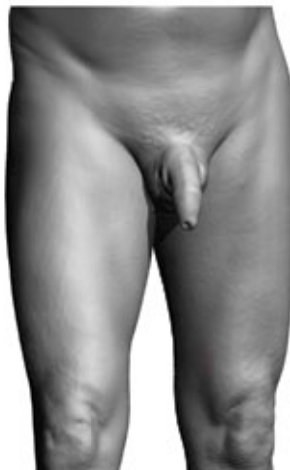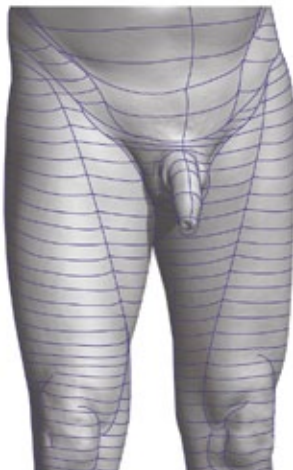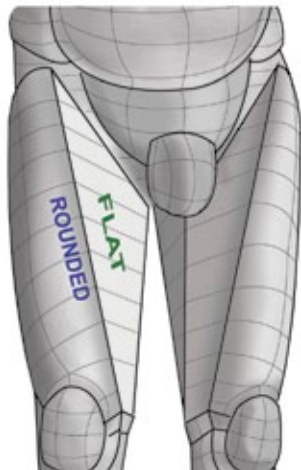


ACTION: FLEXION, ABDUCTION AND LATERAL ROTATION OF THE HIP, FLEXION OF THE KNEE

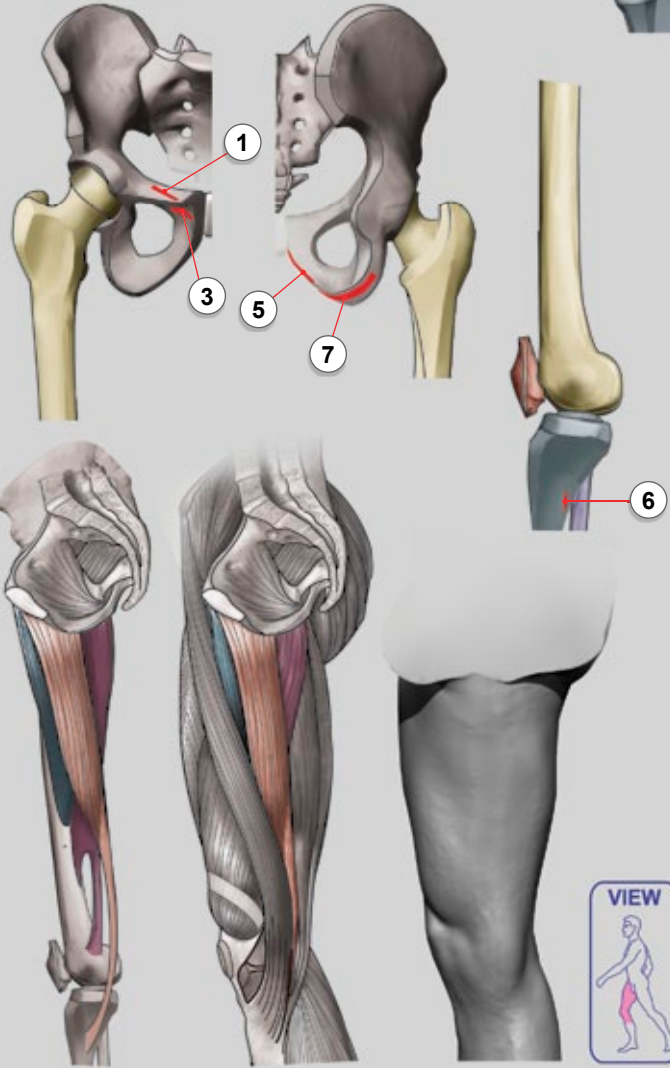
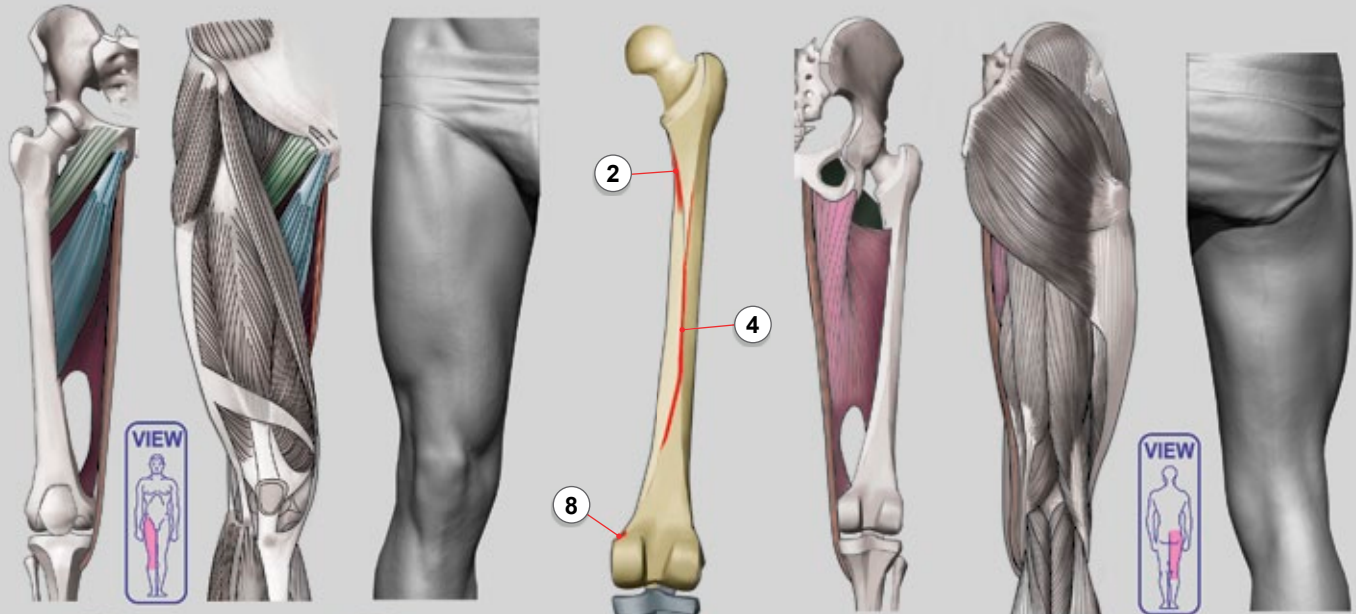
ORIGIN: ① INFERIOR TO THE ANTERIOR SUPERIOR ILIAC SPINE

INSERTION: ② ANTEROMEDIAL SURFACE OF THE UPPER TIBIA

SARTORIUS MUSCLE DIVIDES THIGH INTO TWO PLANES



PECTINEUS, ADDUCTOR LONGUS, GRACILIS, AND ADDUCTOR MAGNUS (ADDUCTOR MUSCLES OF THE HIP)



PECTINEUS

- ACTION:** THIGH FLEXION, ADDUCTION
- ORIGIN:** 1 PECTINEAL LINE OF THE PUBIC BONE
- INSERTION:** 2 PECTINEAL LINE OF THE FEMUR

ADDUCTOR LONGUS

- ACTION:** ADDUCTION OF HIP, FLEXION OF HIP JOINT
- ORIGIN:** 3 PUBIC BODY JUST BELOW THE PUBIC CREST
- INSERTION:** 4 MIDDLE THIRD OF LINEA ASPERA

GRACILIS

- ACTION:** FLEXES, MEDIALLY ROTATES, AND ADDUCTS THE HIP, FLEXES THE KNEE
- ORIGIN:** 5 ISCHIO-PUBIC RAMUS
- INSERTION:** 6 PES ANSERINUS

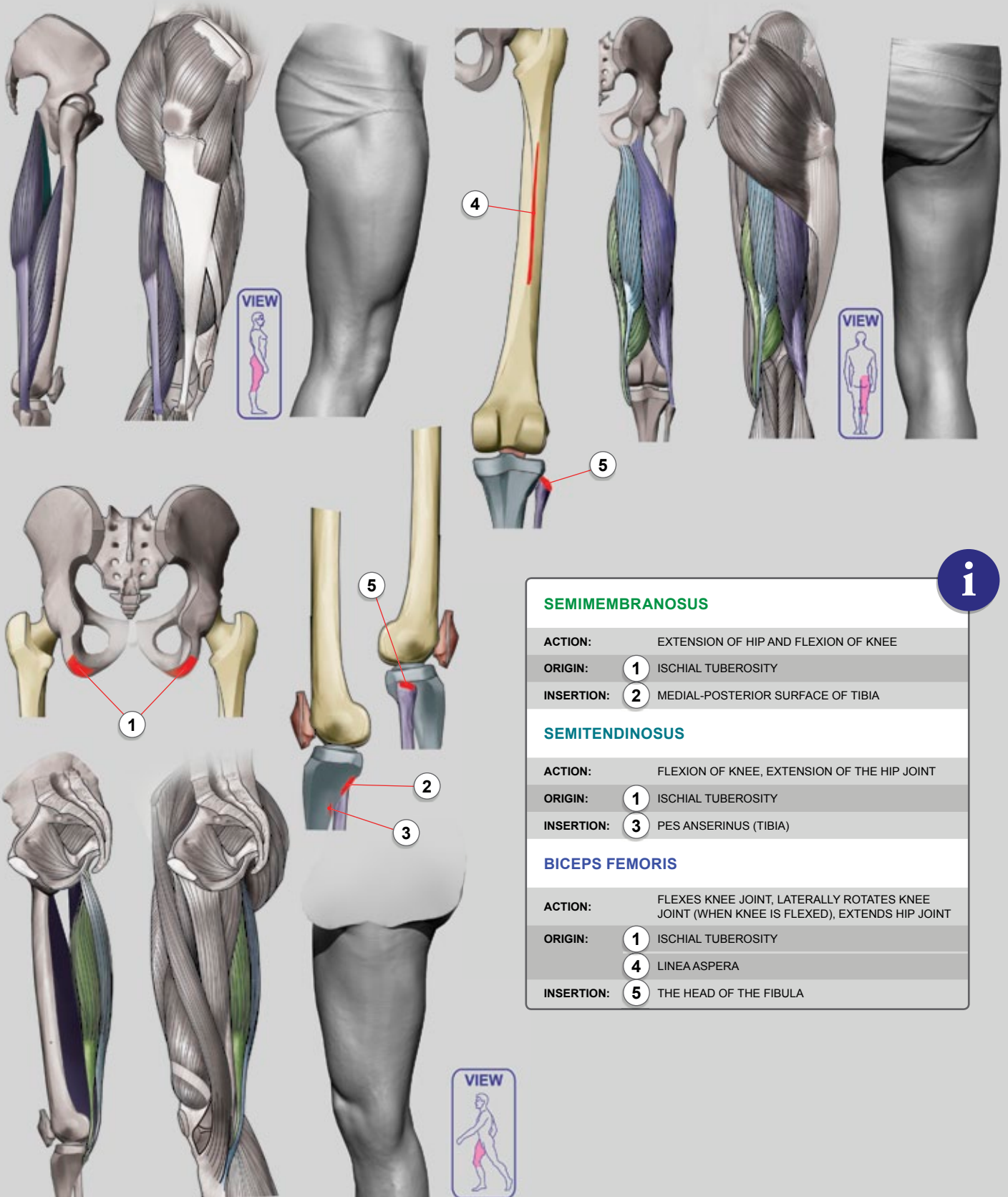
ADDUCTOR MAGNUS

- ACTION:** ADDUCTION, FLEXION AND EXTENSION OF HIP
- ORIGIN:** 7 PUBIS, TUBEROSITY OF THE ISCHIUM
- INSERTION:** 4 LINEA ASPERA
8 ADDUCTOR TUBERCLE OF FEMUR

HAMSTRINGS

(FLEXORS OF THE THIGH)

SEMITENDINOSUS, SEMIMEMBRANOSUS AND BICEPS FEMORIS MUSCLES



SEMIMEMBRANOSUS

ACTION: EXTENSION OF HIP AND FLEXION OF KNEE

ORIGIN: ① ISCHIAL TUBEROSITY

INSERTION: ② MEDIAL-POSTERIOR SURFACE OF TIBIA

SEMITENDINOSUS

ACTION: FLEXION OF KNEE, EXTENSION OF THE HIP JOINT

ORIGIN: ① ISCHIAL TUBEROSITY

INSERTION: ③ PES ANSERINUS (TIBIA)

BICEPS FEMORIS

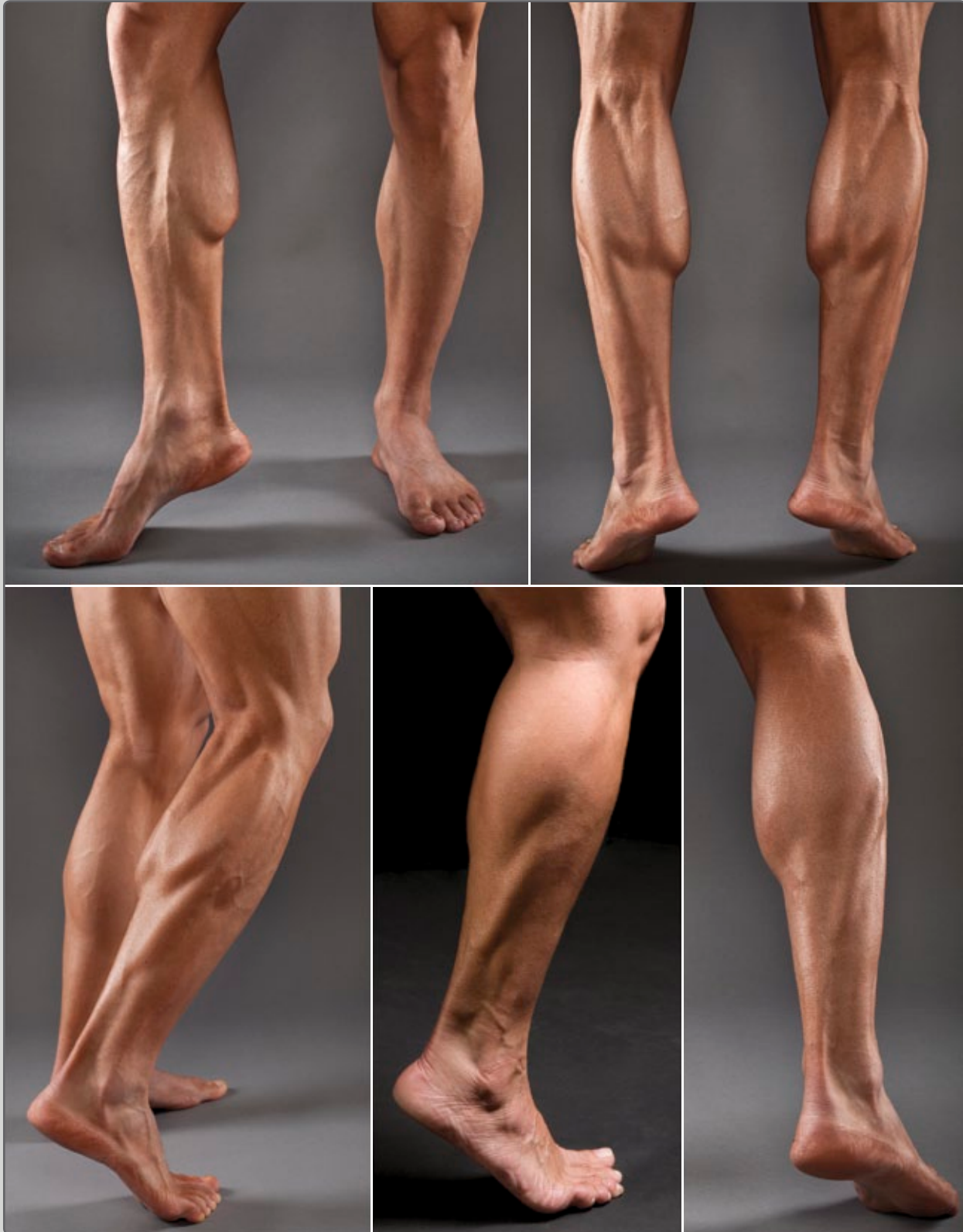ACTION: FLEXES KNEE JOINT, LATERALLY ROTATES KNEE JOINT (WHEN KNEE IS FLEXED), EXTENDS HIP JOINT

ORIGIN: ① ISCHIAL TUBEROSITY

④ LINEA ASPERA

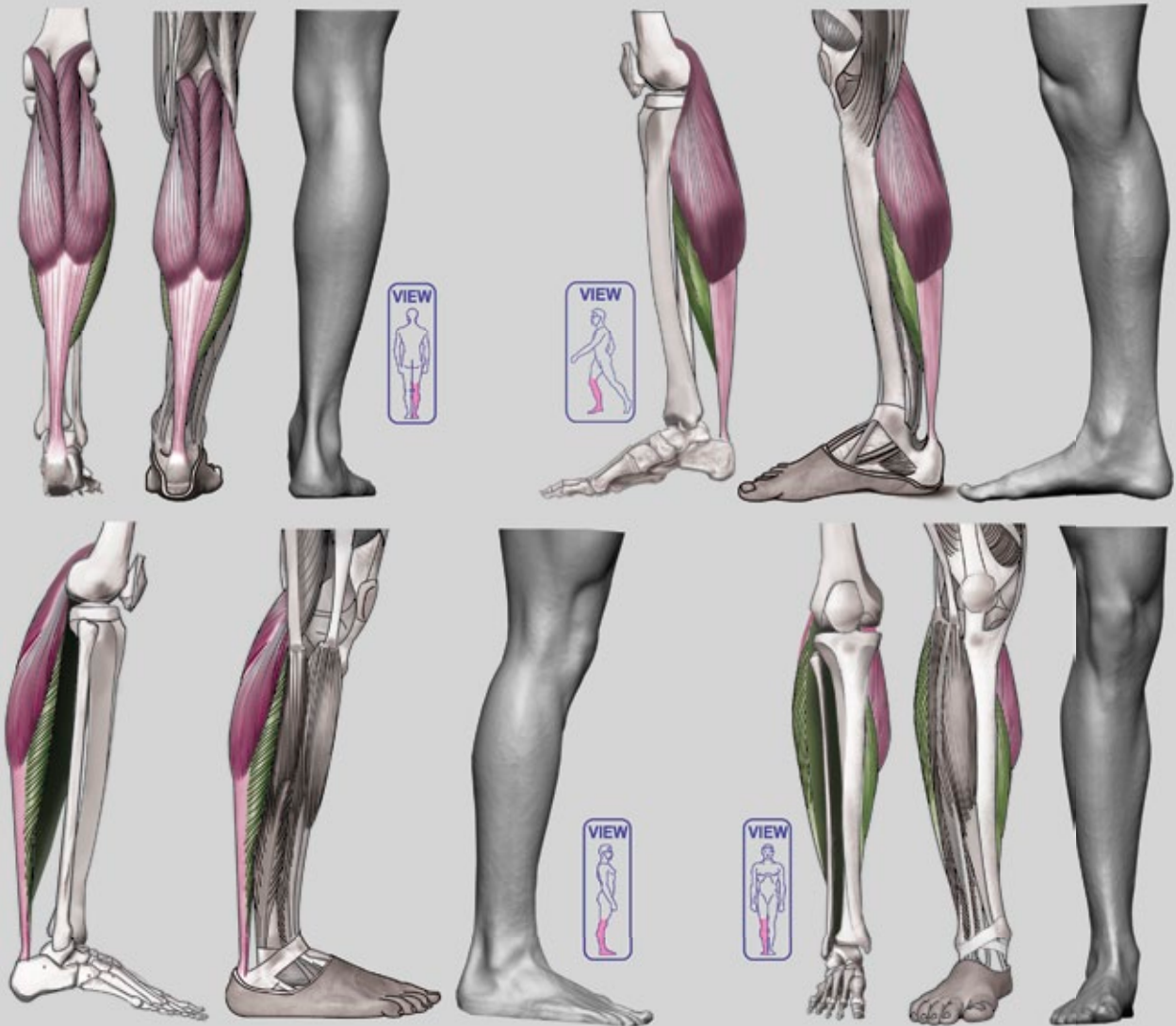
INSERTION: ⑤ THE HEAD OF THE FIBULA

CALVES



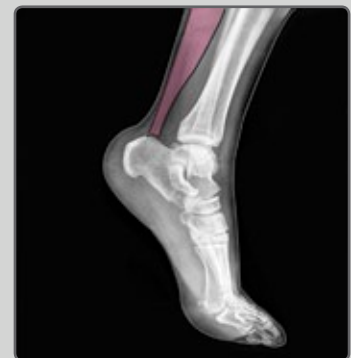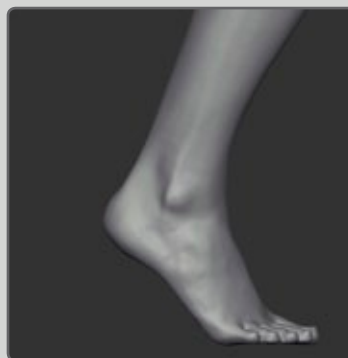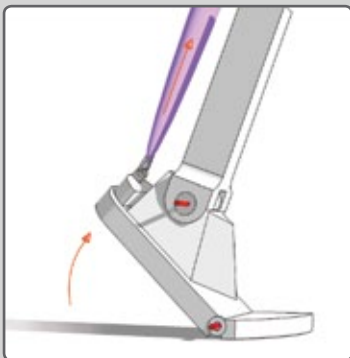THE CALF

(GASTROCNEMIUS AND SOLEUS MUSCLES)

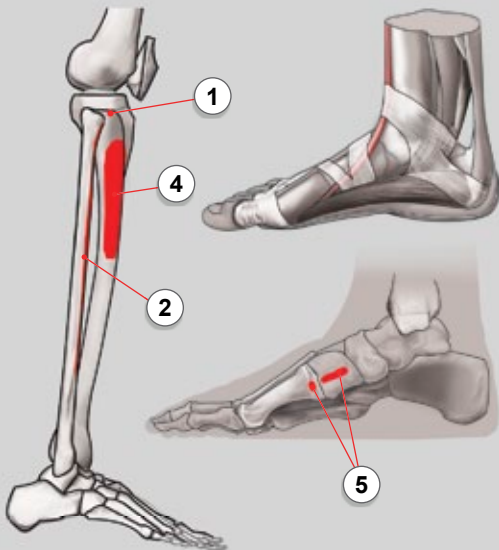
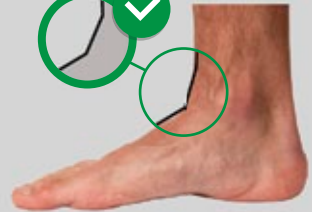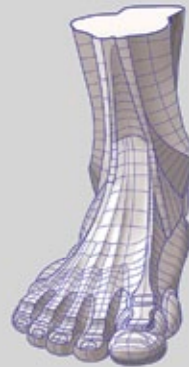
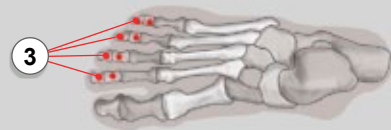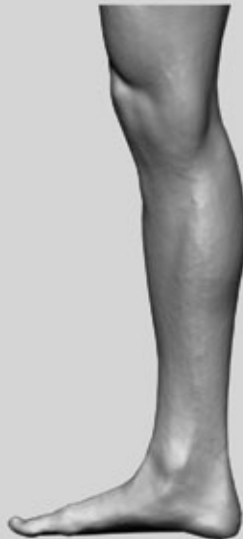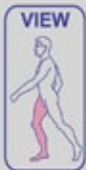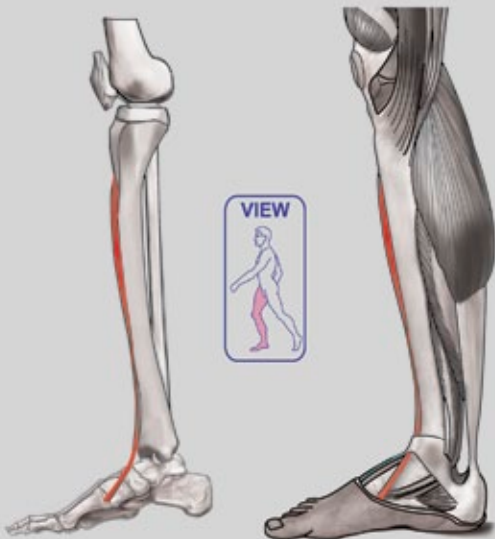
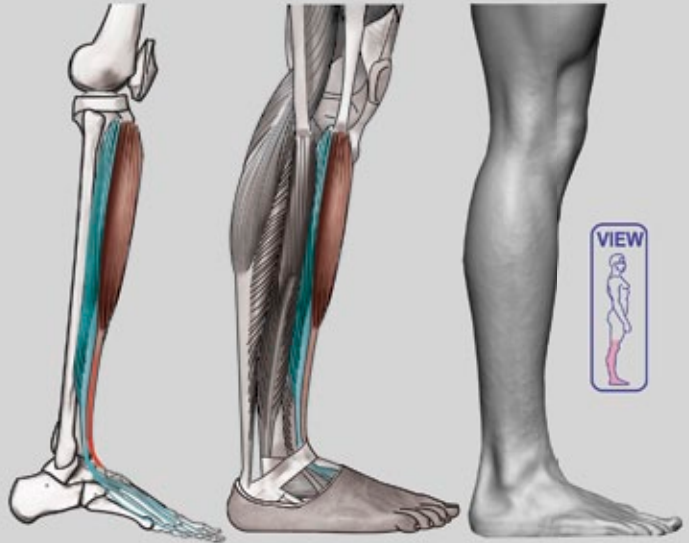
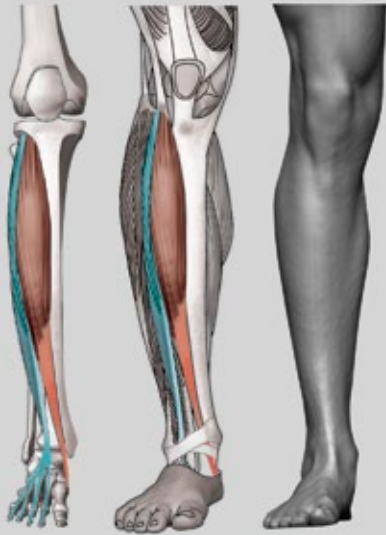


i

GASTROCNEMIUS MUSCLE IS THE LARGER CALF MUSCLE, FORMING A BULGE VISIBLE BENEATH THE SKIN. **THE GASTROCNEMIUS** HAS TWO PARTS OR "HEADS", WHICH TOGETHER CREATE ITS DIAMOND SHAPE. **THE SOLEUS** IS A SMALLER, FLAT MUSCLE THAT LIES UNDERNEATH THE **GASTROCNEMIUS** MUSCLE. CONNECTIVE TISSUE AT THE BOTTOM OF THE CALF MUSCLE MERGES WITH THE ACHILLES TENDON. THE ACHILLES TENDON INSERTS INTO THE HEEL BONE (CALCANEUS).



EXTENSOR DIGITORUM LONGUS AND TIBIALIS ANTERIOR MUSCLES



EXTENSOR DIGITORUM LONGUS

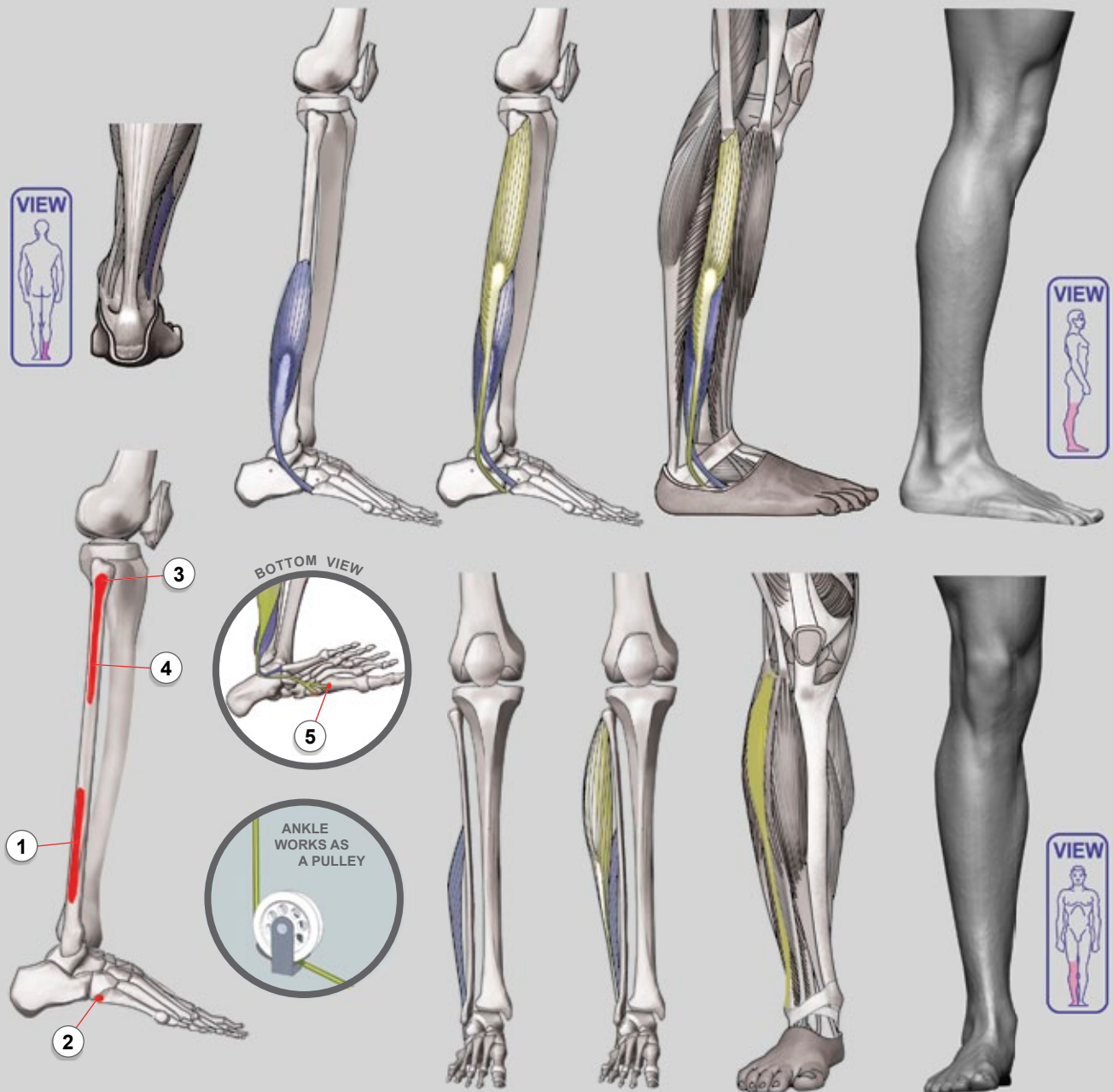
- ACTION:** EXTENSION OF TOES AND DORSIFLEXION OF ANKLE
- ORIGIN:** ① ANTERIOR LATERAL CONDYLE OF TIBIA
② ANTERIOR SHAFT OF FIBULA
- INSERTION:** ③ DORSAL SURFACE: MIDDLE AND DISTAL PHALANGES OF DIGITS 2, 3, 4, 5

TIBIALIS ANTERIOR

- ACTION:** DORSIFLEXION AND INVERSION OF THE FOOT
- ORIGIN:** ④ BODY OF TIBIA
- INSERTION:** ⑤ MEDIAL CUNEIFORM AND FIRST METATARSAL



PERONEUS BREVIS AND PERONEUS LONGUS MUSCLES



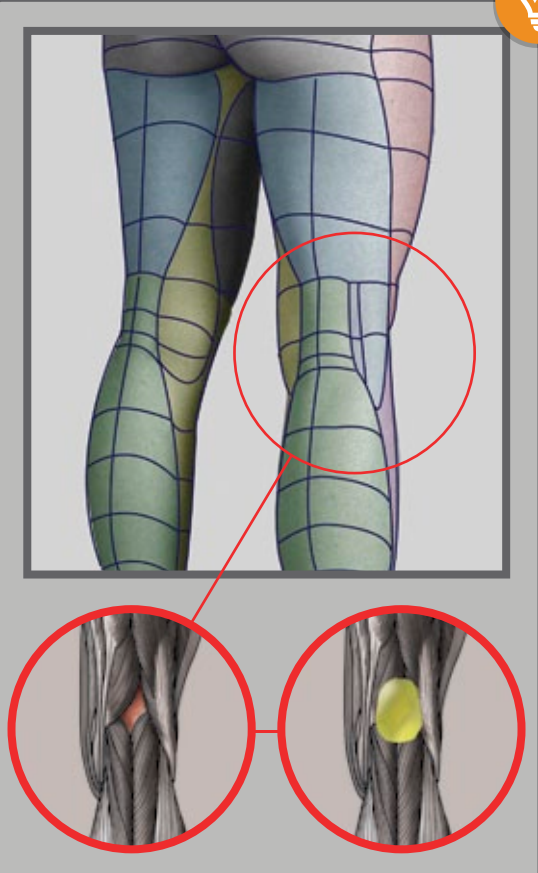
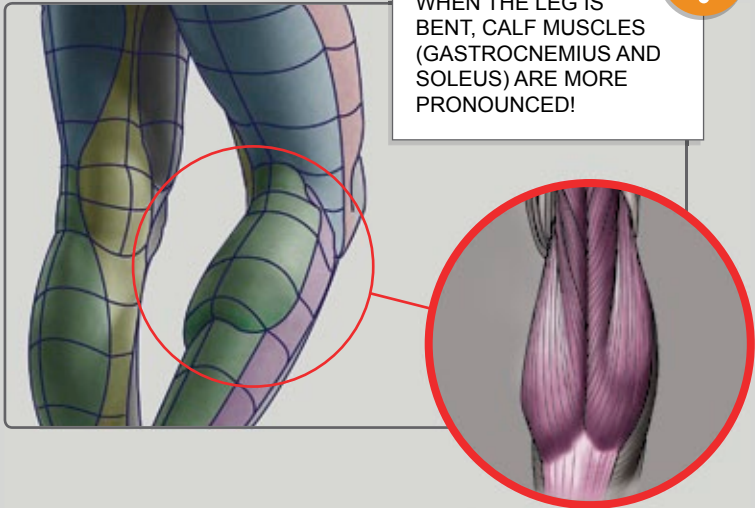
PERONEUS BREVIS		PERONEUS LONGUS	
ACTIONS:	EVERTS AND PLANTAR FLEXES THE FOOT	ACTIONS:	EVERTS AND PLANTAR FLEXES THE FOOT, MAINTAINS THE ARCH OF THE FOOT
ORIGIN:	① LOWER 2/3 OF THE LATERAL FIBULA	ORIGIN:	③ HEAD OF FIBULA
INSERTION:	② ENLARGED BASE OF THE 5TH METATARSAL	ORIGIN:	④ UPPER 2/3 OF THE SHAFT OF FIBULA
		INSERTION:	⑤ UNDER THE FOOT INTO THE BASE OF THE 1st. METATARSAL BONE, AND MEDIAL CUNEIFORM



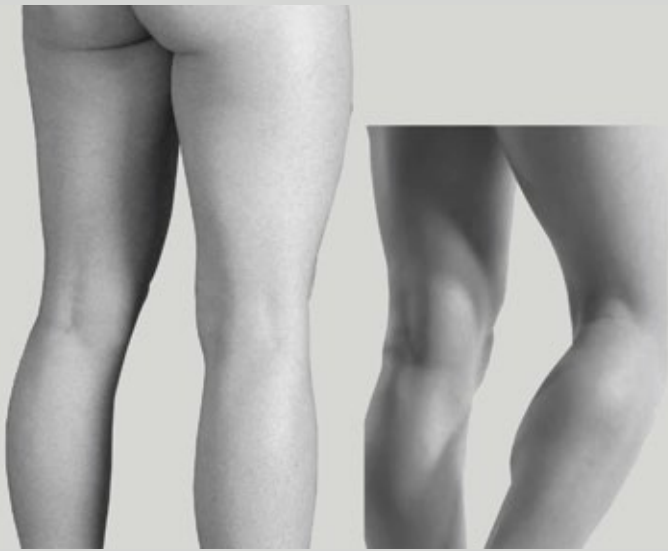TIPS FOR BACKSIDE OF LEGS



WHEN THE LEG IS BENT, CALF MUSCLES (GASTROCNEMIUS AND SOLEUS) ARE MORE PRONOUNCED!



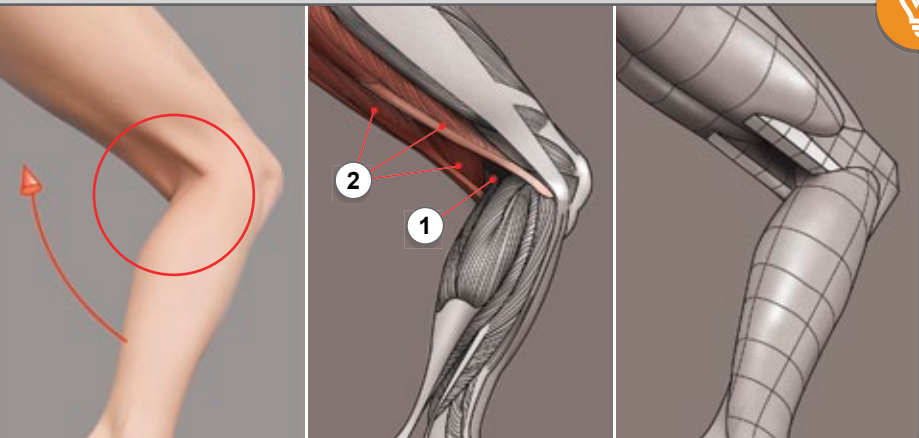
HERE, IN THE MUSCLE VIEW, THE BACK OF THE KNEE IS A SHALLOW DEPRESSION. BUT IN REAL LIFE, WHEN THE LEG IS STRAIGHT, THIS AREA POPS OUTWARD. THIS IS BECAUSE OF A FAT PAD LOCATED RIGHT ON TOP OF THE POPLITEAL FOSSA.



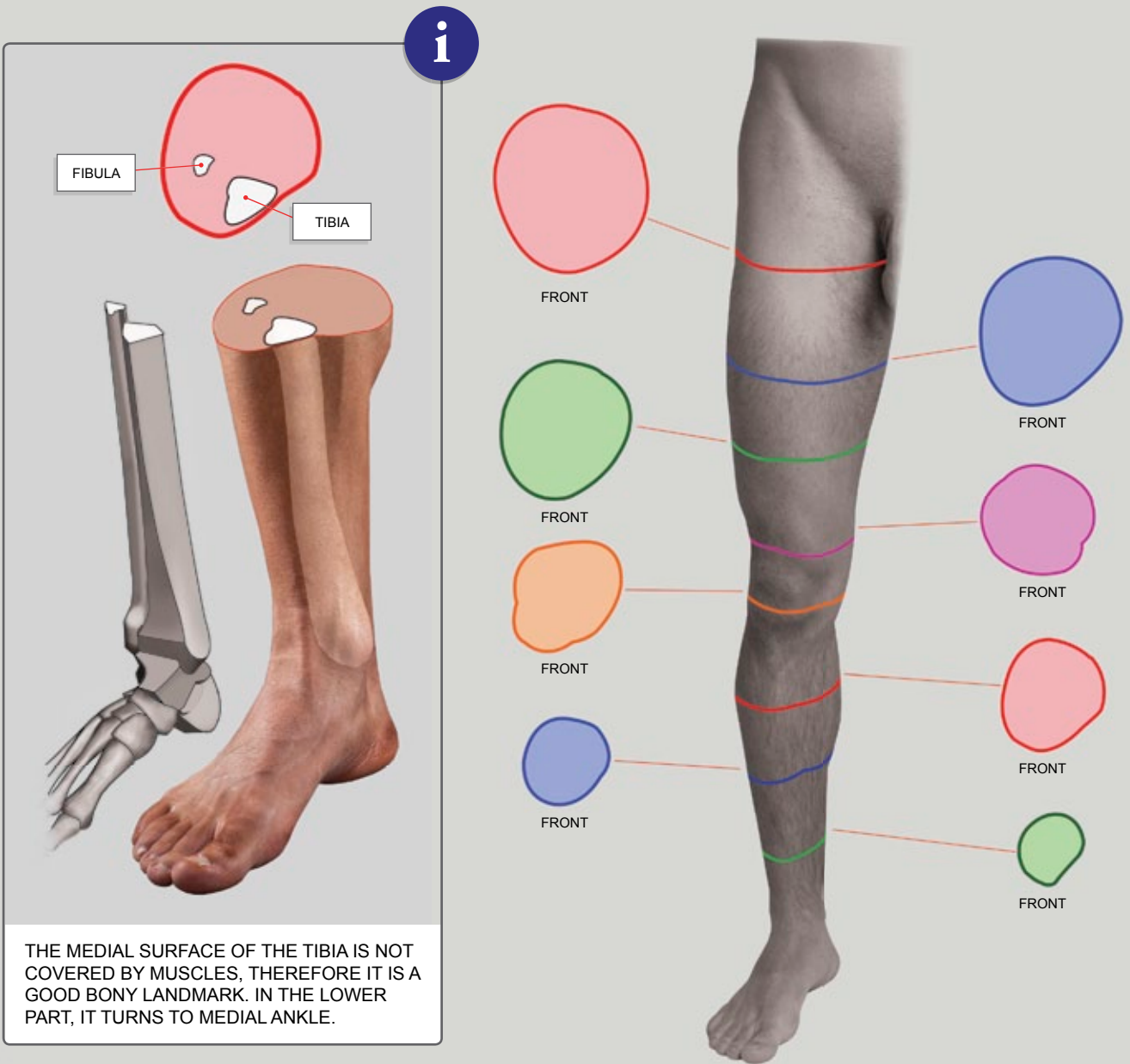
AS THE LEG IS BENT FURTHER, THE DEPRESSION, CALLED THE POPLITEAL FOSSA (THE KNEE PIT), BECOMES DEEPER.

1 FOSSA (THE KNEE PIT) BECOMES PROMINENT

2 HAMSTRING MUSCLES

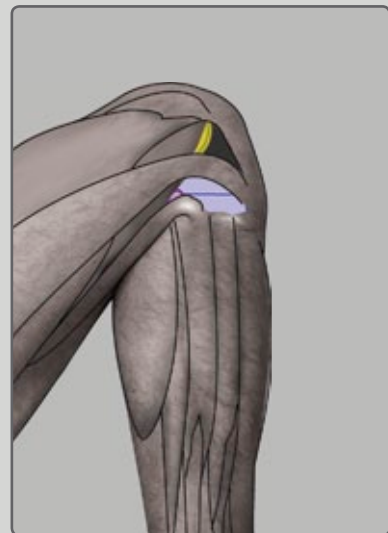
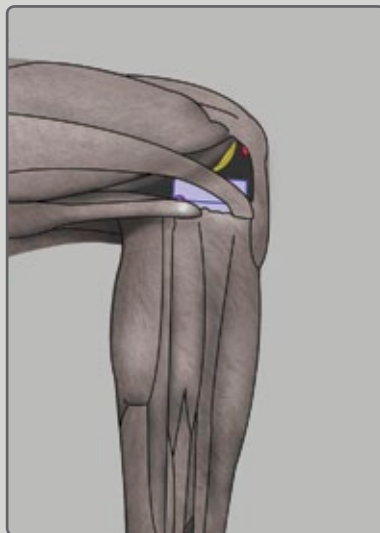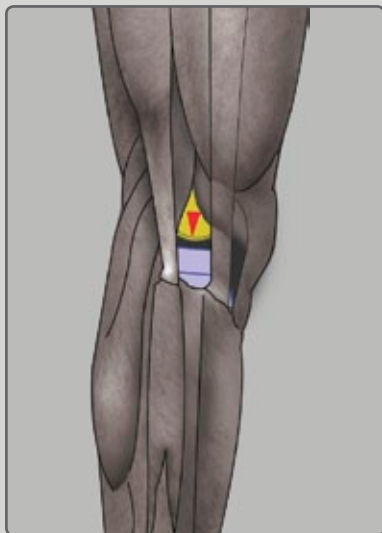
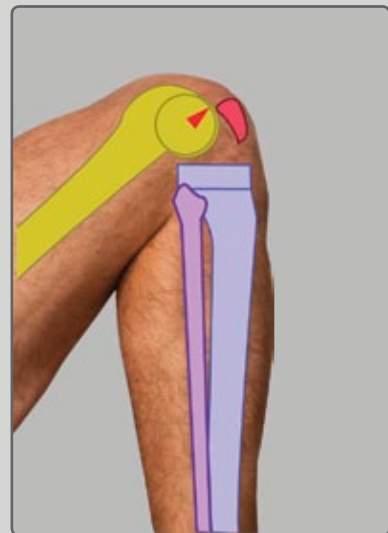
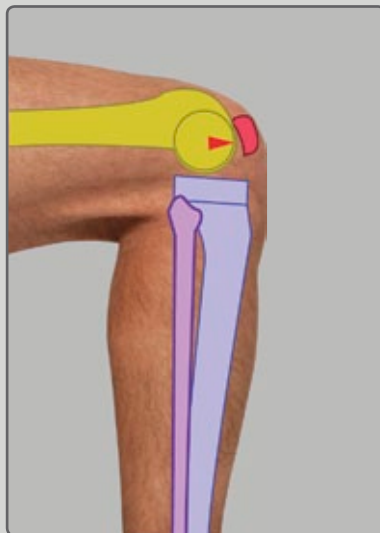
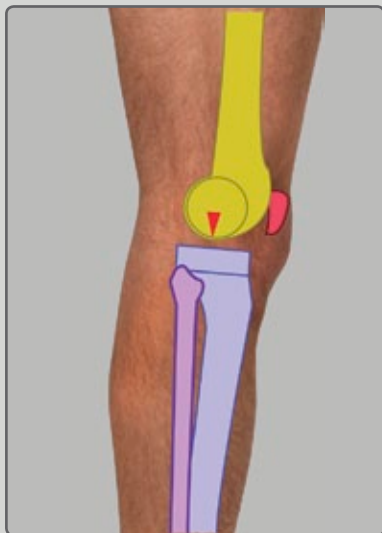

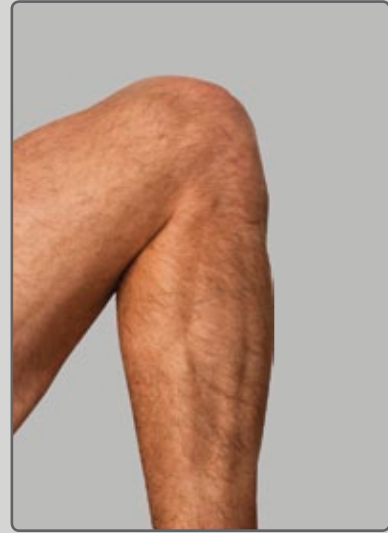
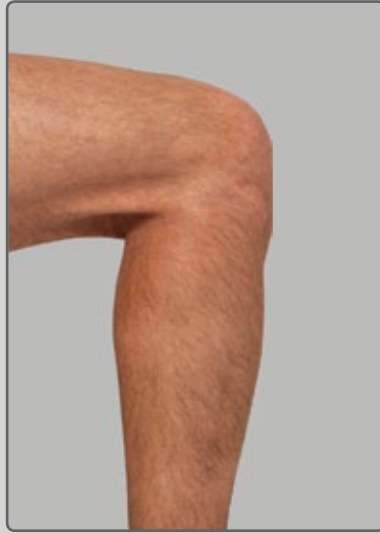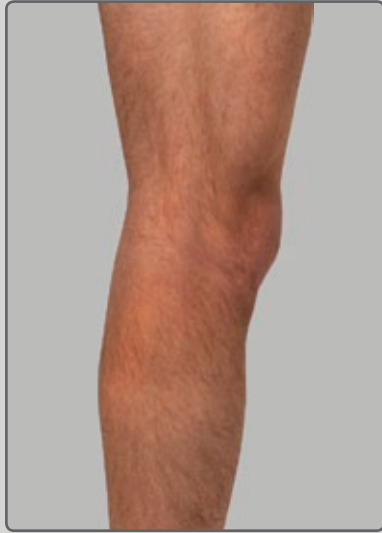CROSS SECTION OF THE LOWER LIMB

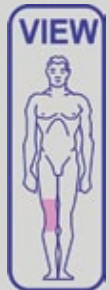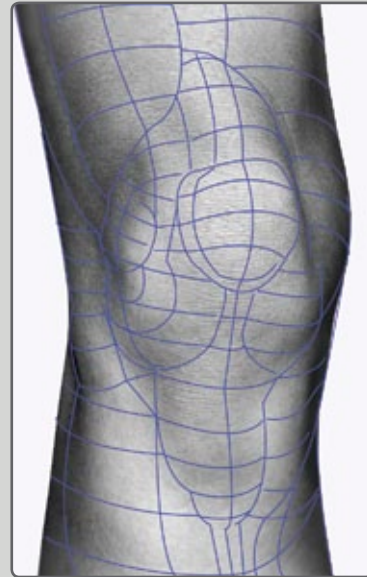
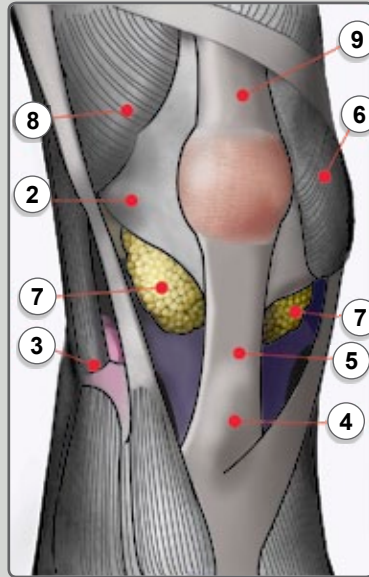
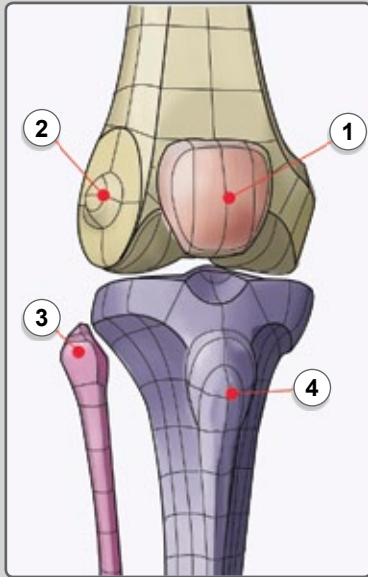


THE MEDIAL SURFACE OF THE TIBIA IS NOT COVERED BY MUSCLES, THEREFORE IT IS A GOOD BONY LANDMARK. IN THE LOWER PART, IT TURNS TO MEDIAL ANKLE.

KNEE MECHANICS

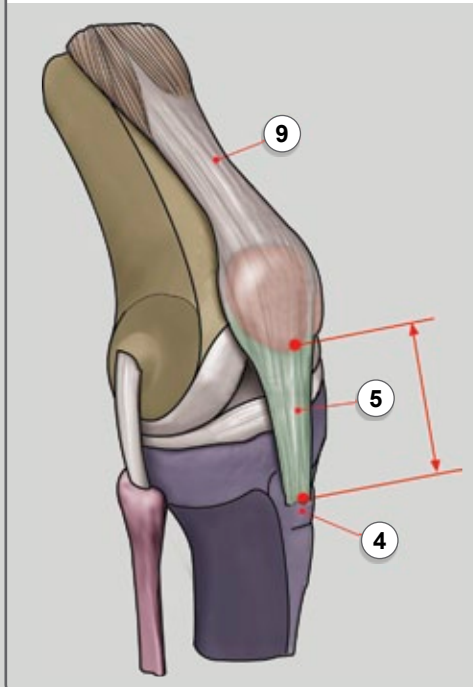


THE KNEE (WHAT ARE THESE BUMPS?)

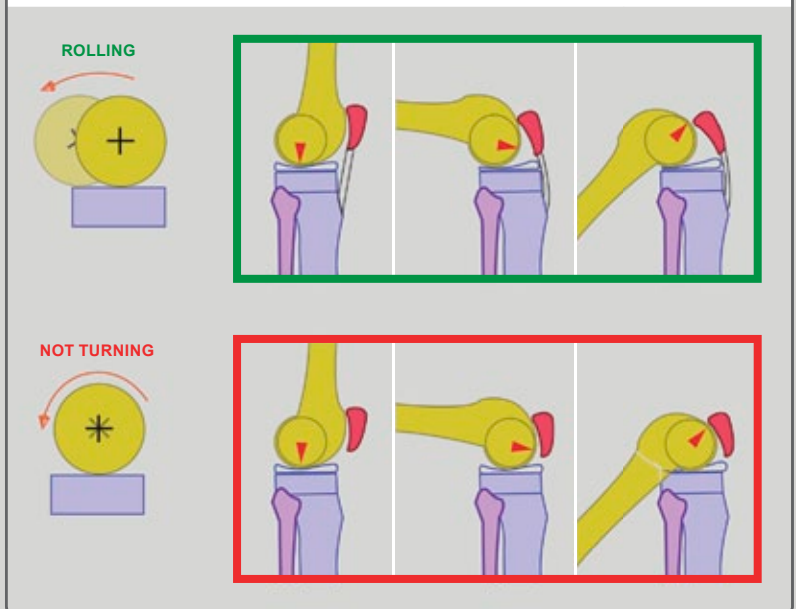


- | | | |
|-------------------------------|---------------------|-------------------------|
| 1 KNEE CAP (PATELLA) | 4 TIBIAL TUBEROSITY | 7 INFRAPATELLAR FAT PAD |
| 2 LATERAL EPICONDYLE OF FEMUR | 5 PATELLAR LIGAMENT | 8 VASTUS LATERALIS |
| 3 HEAD OF FIBULA | 6 VASTUS MEDIALIS | 9 QUADRICEPS TENDON |

PATELLAR LIGAMENT ⑤ DO NOT STRETCH LIKE TENDONS ⑨ SO THE DISTANCE BETWEEN KNEE CAP AND TIBIAL TUBEROSITY ④ REMAINS CONSISTENT.

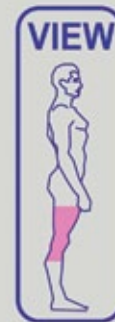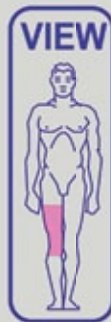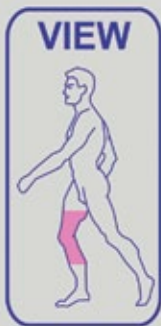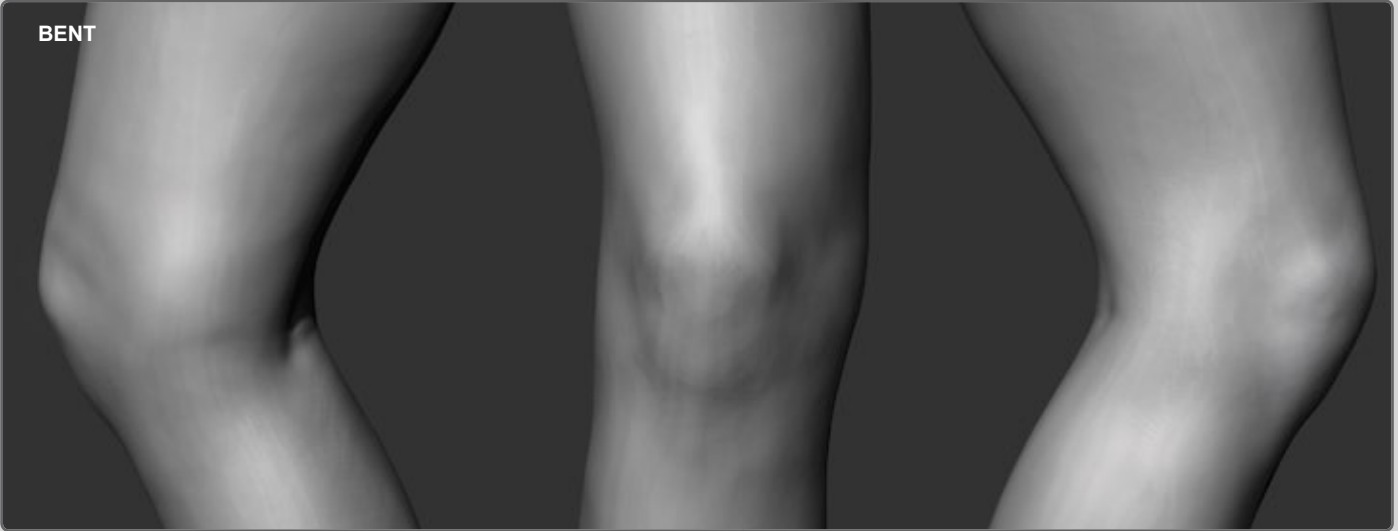


THE HEAD OF THE **FEMUR** IS **ROLLING** OVER THE TOP OF THE **TIBIA**, **NOT TURNING**.

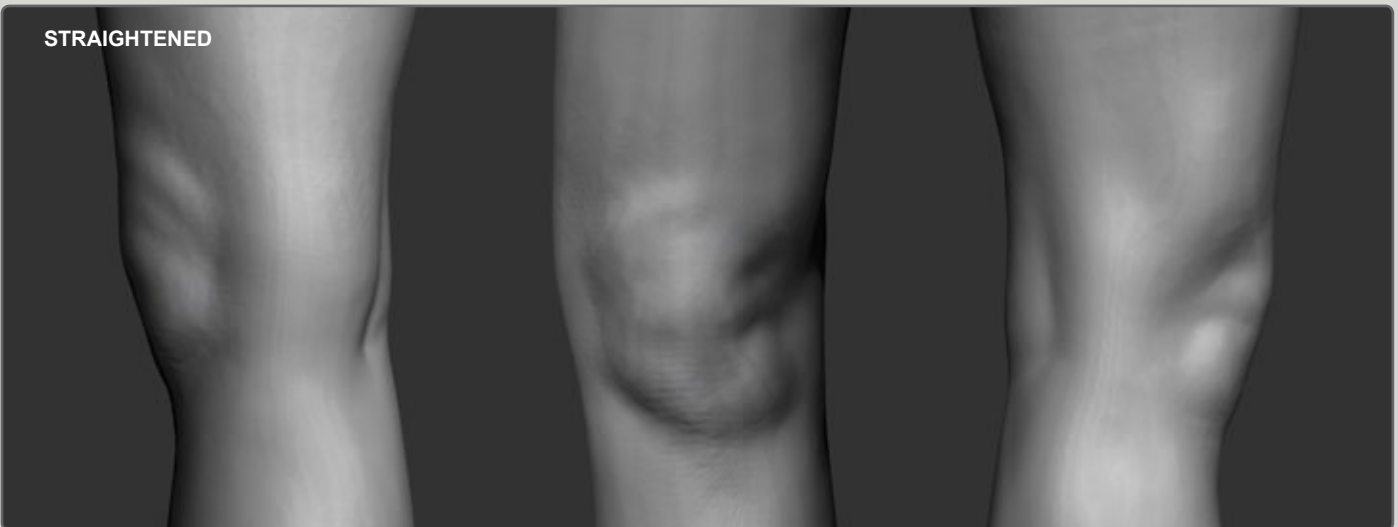


3D SCAN OF RIGHT KNEE

BENT

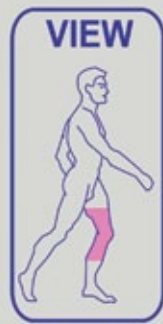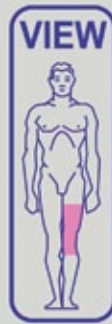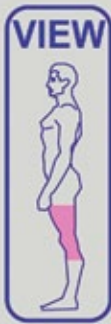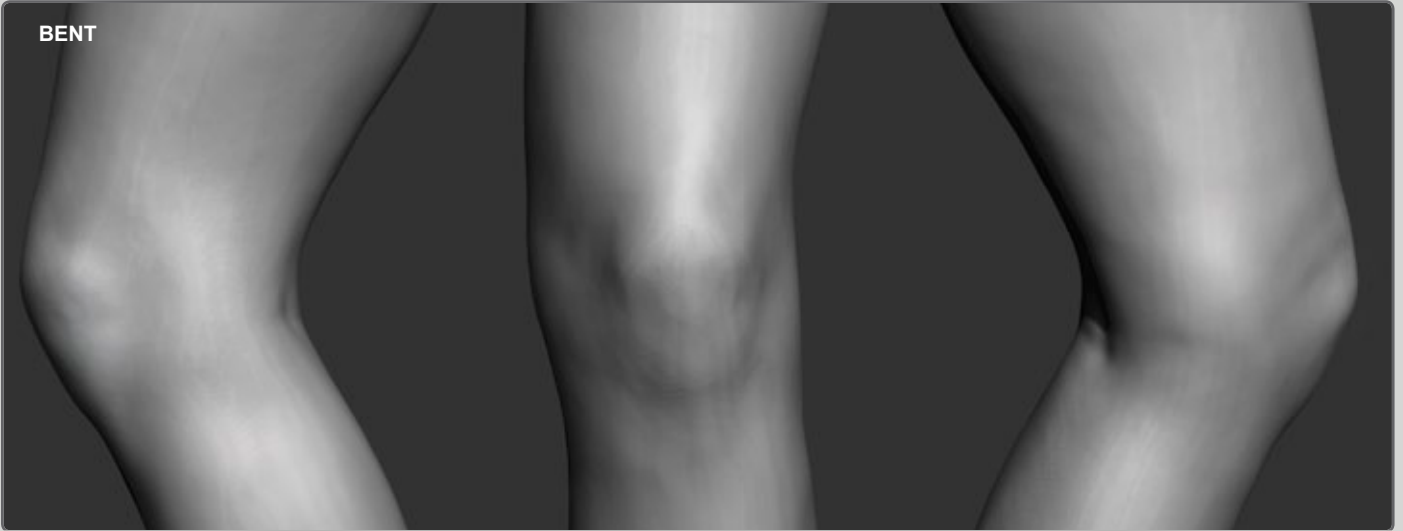


STRAIGHTENED

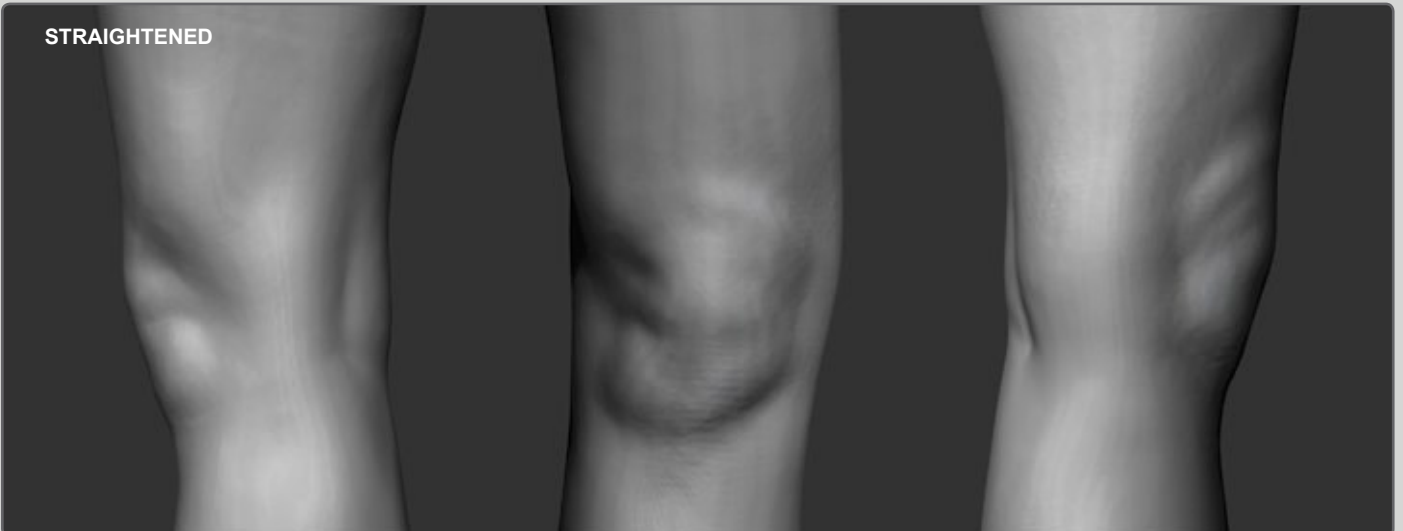


3D SCAN OF LEFT KNEE

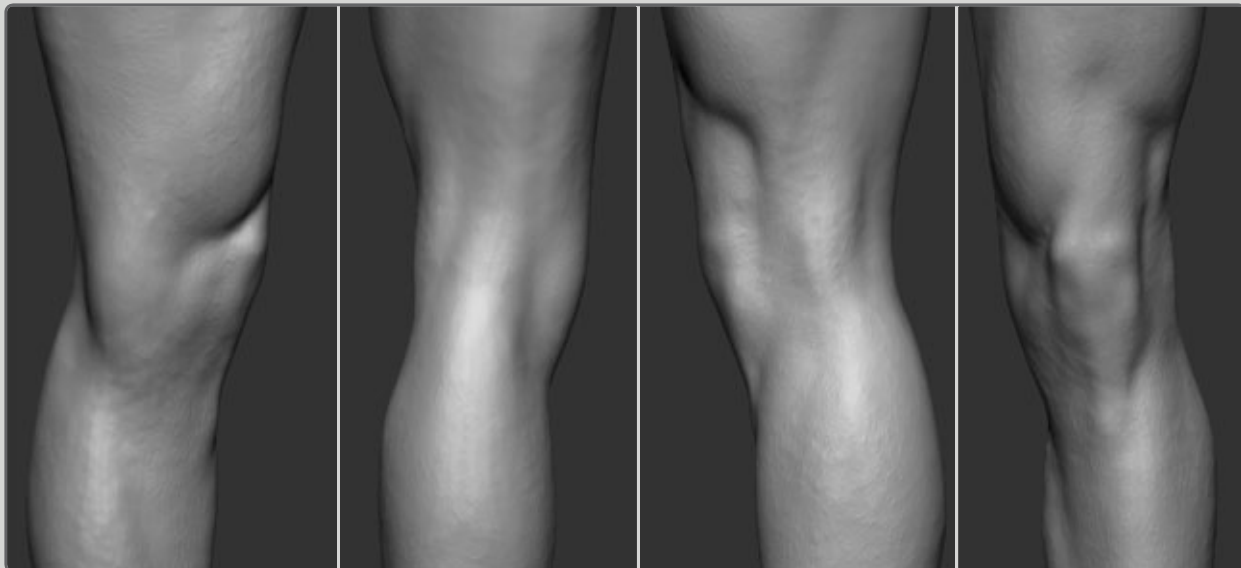
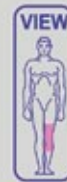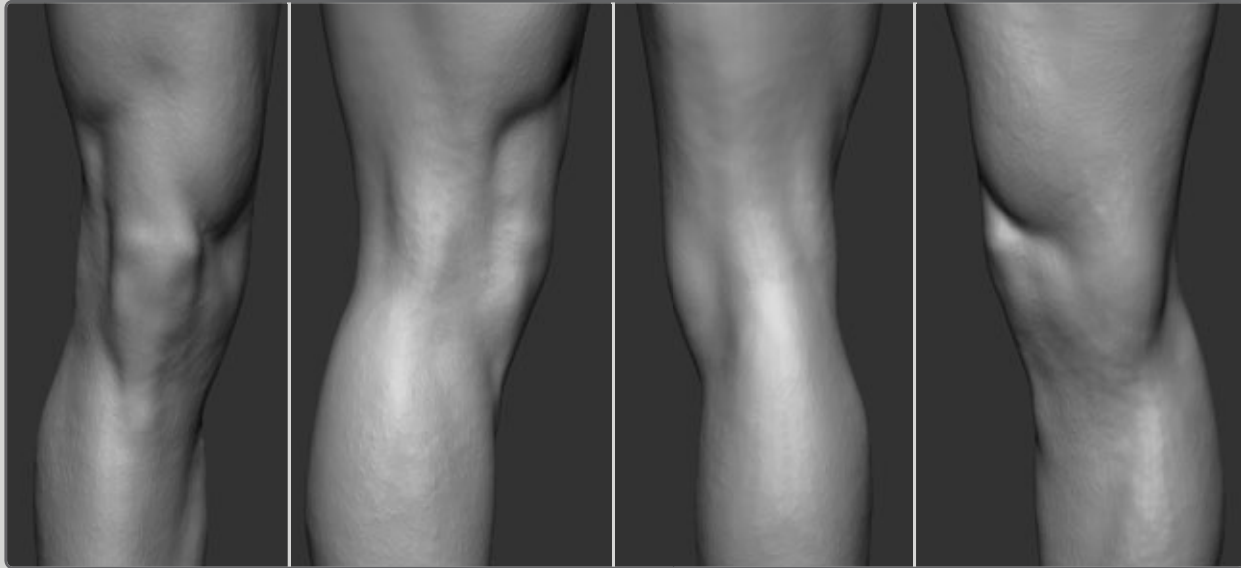
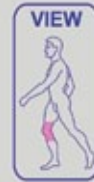BENT



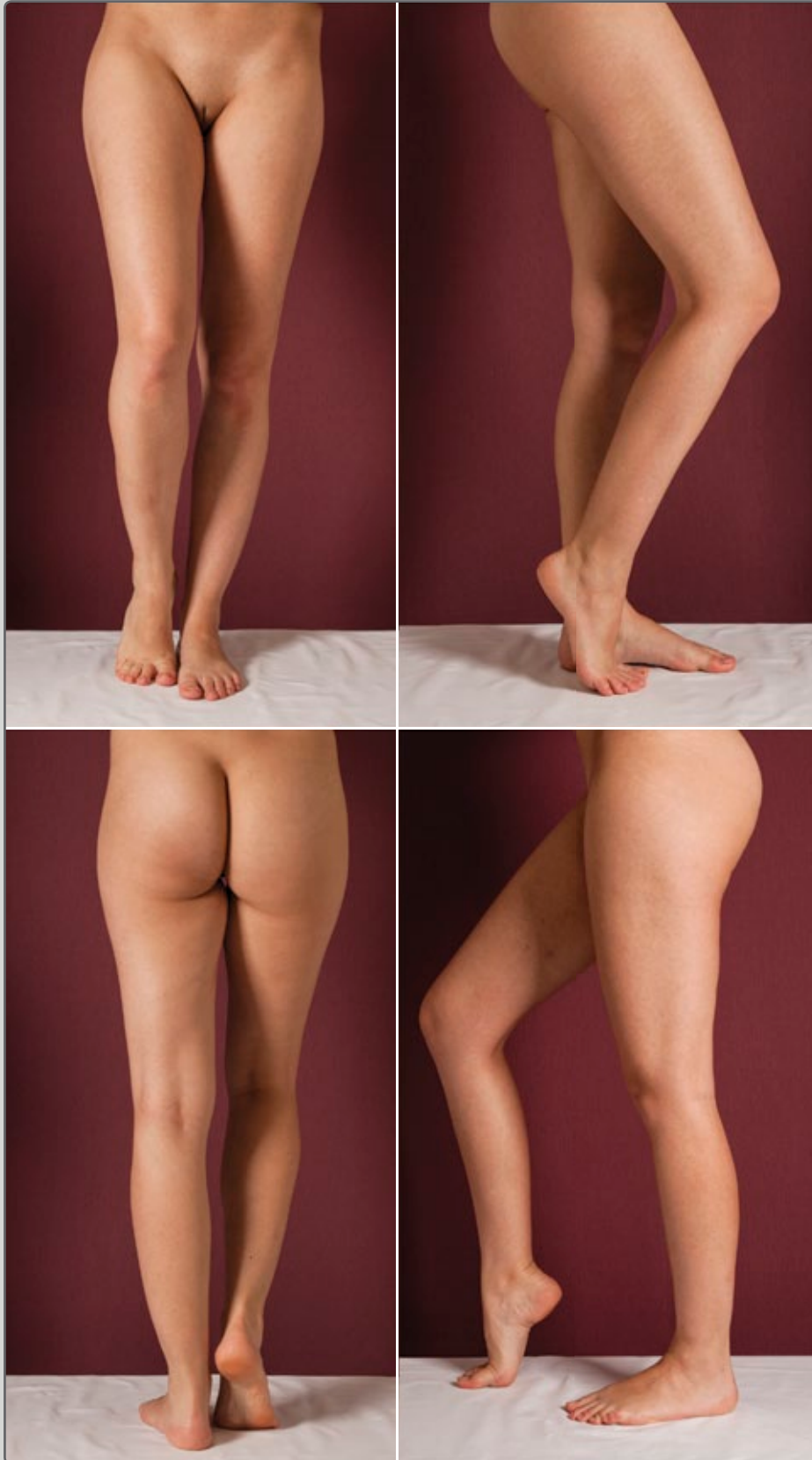STRAIGHTENED



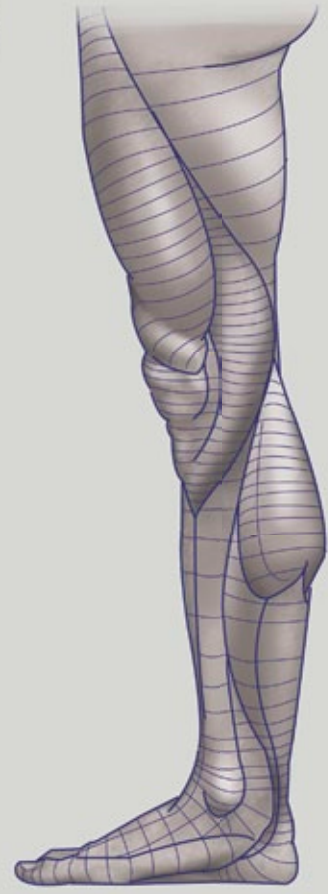
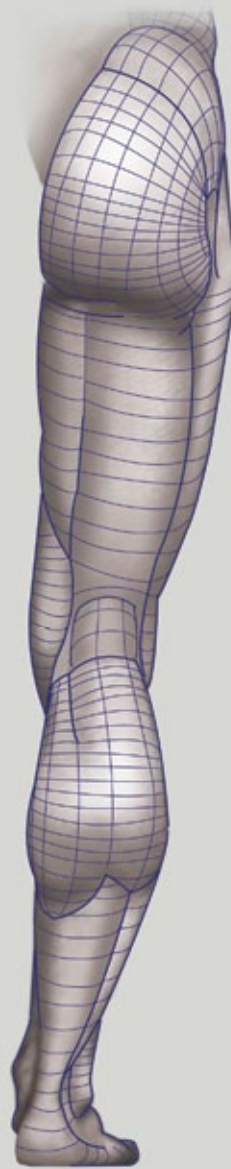
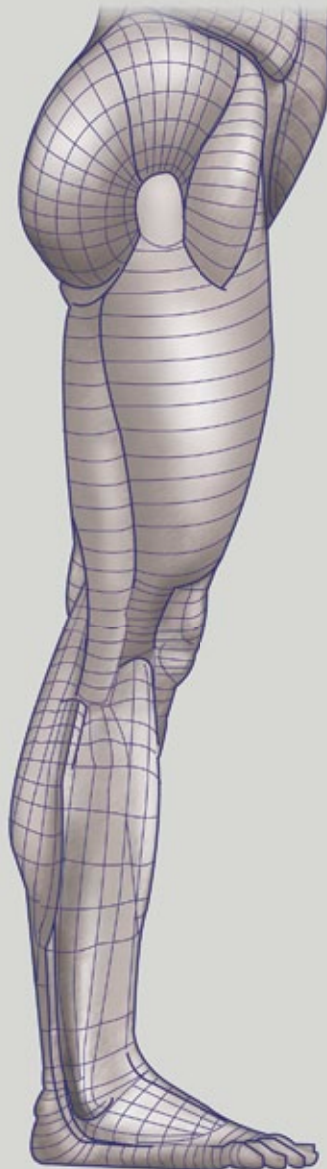
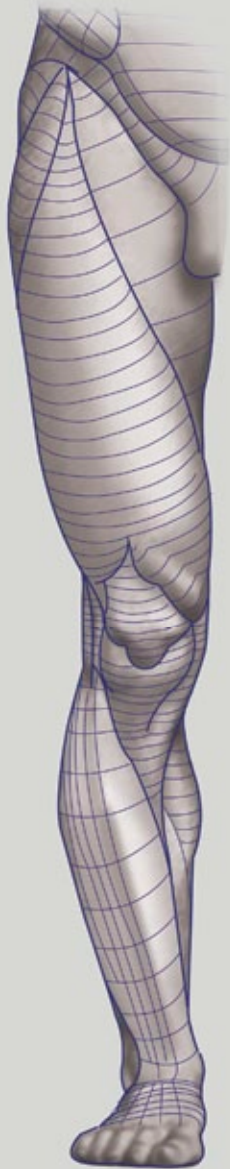
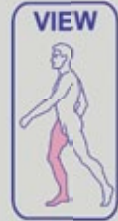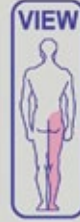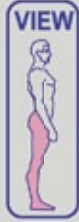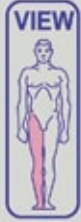3D SCAN OF LEFT AND RIGHT KNEES



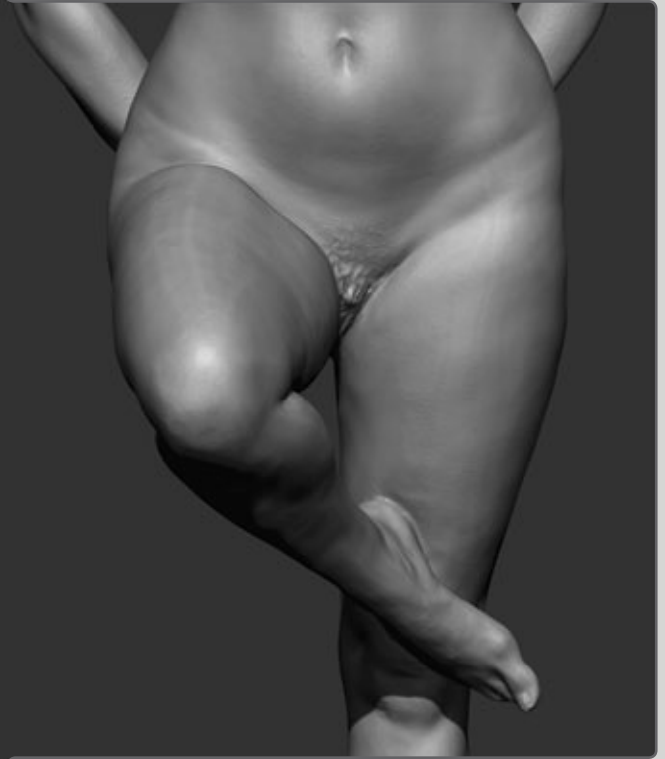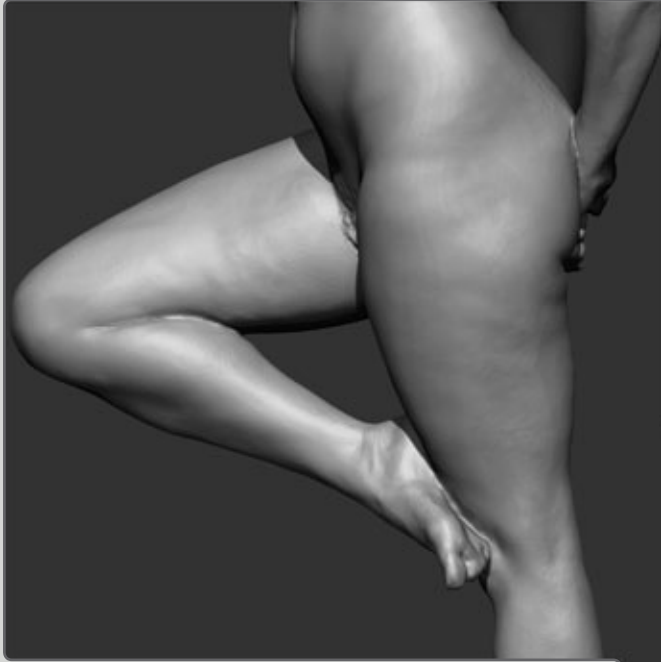FEMALE LEGS



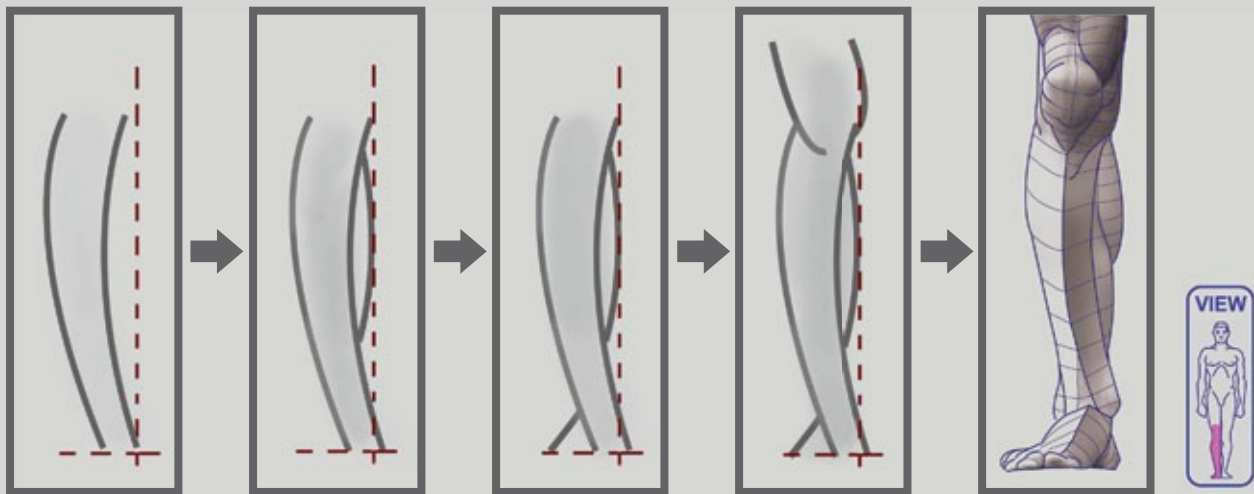
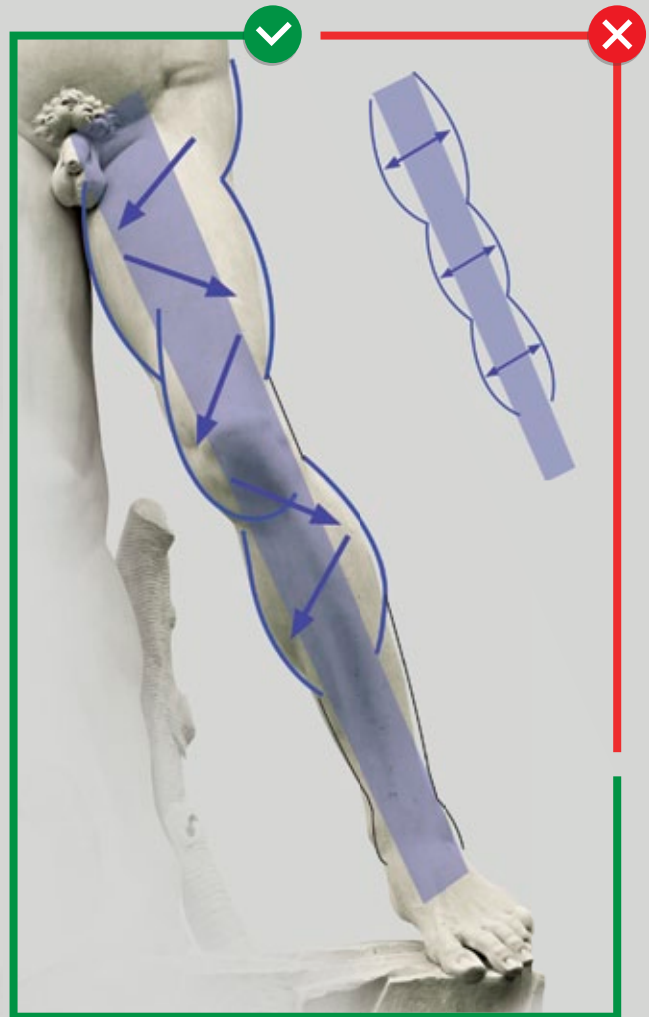
LEG SHAPES VIEWED FROM ALL SIDES



3D SCAN OF LOWER LIMB

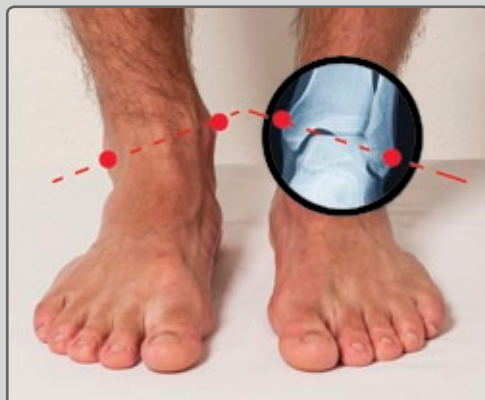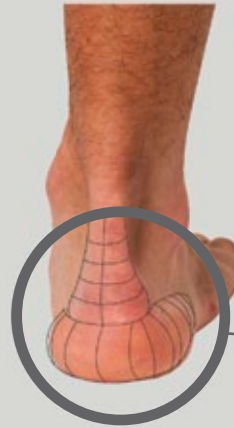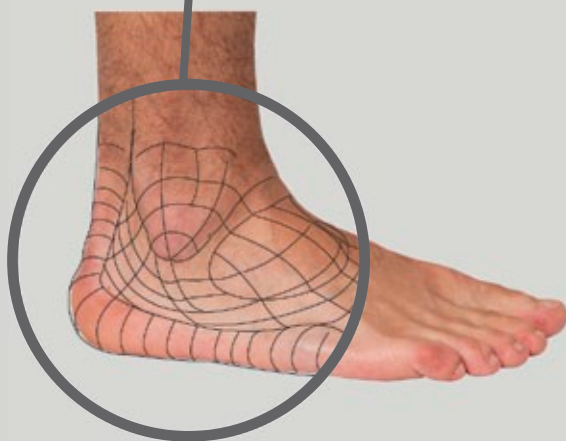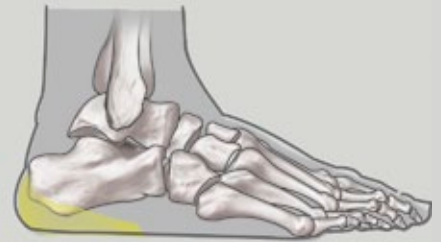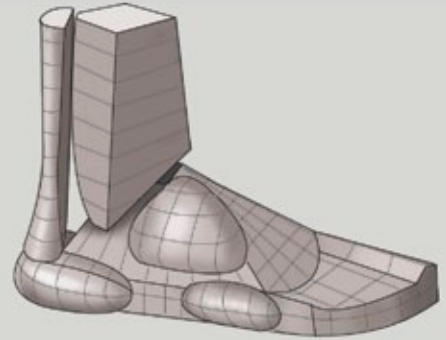


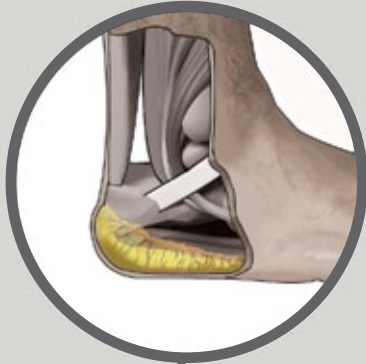MUSCLES TRAVERSING DOWN THE LOWER LIMB

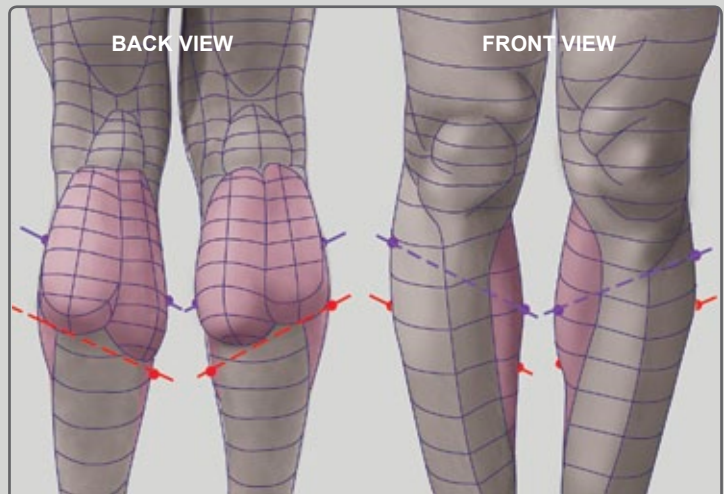


ADDITIONAL SHAPES OF THE LEG AND FOOT

HEEL IS MOSTLY SHAPED BY **FAT PAD**.

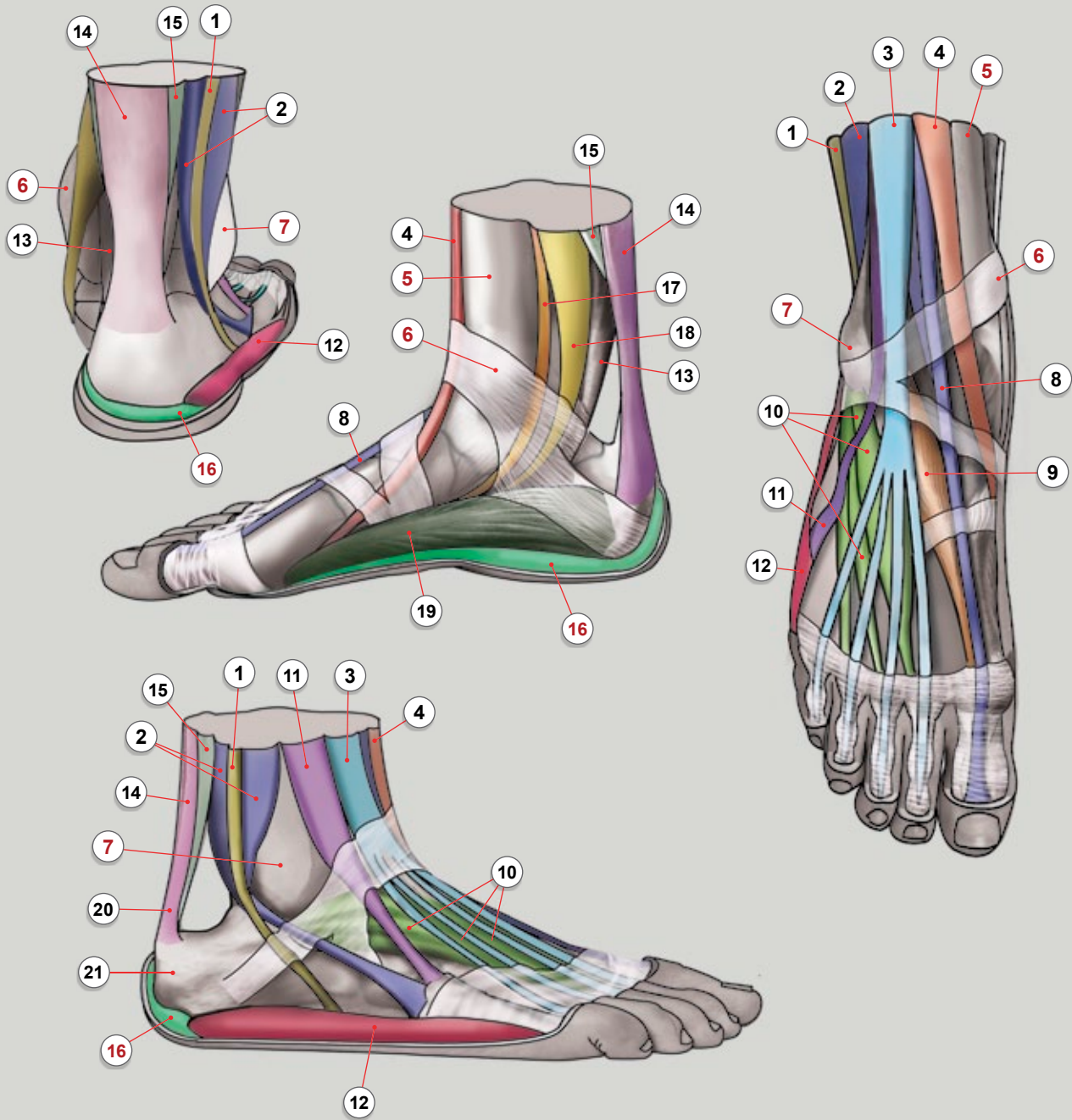

THE INNER ANKLE CURVE IS HIGHER THAN THE OUTER ANKLE CURVE.



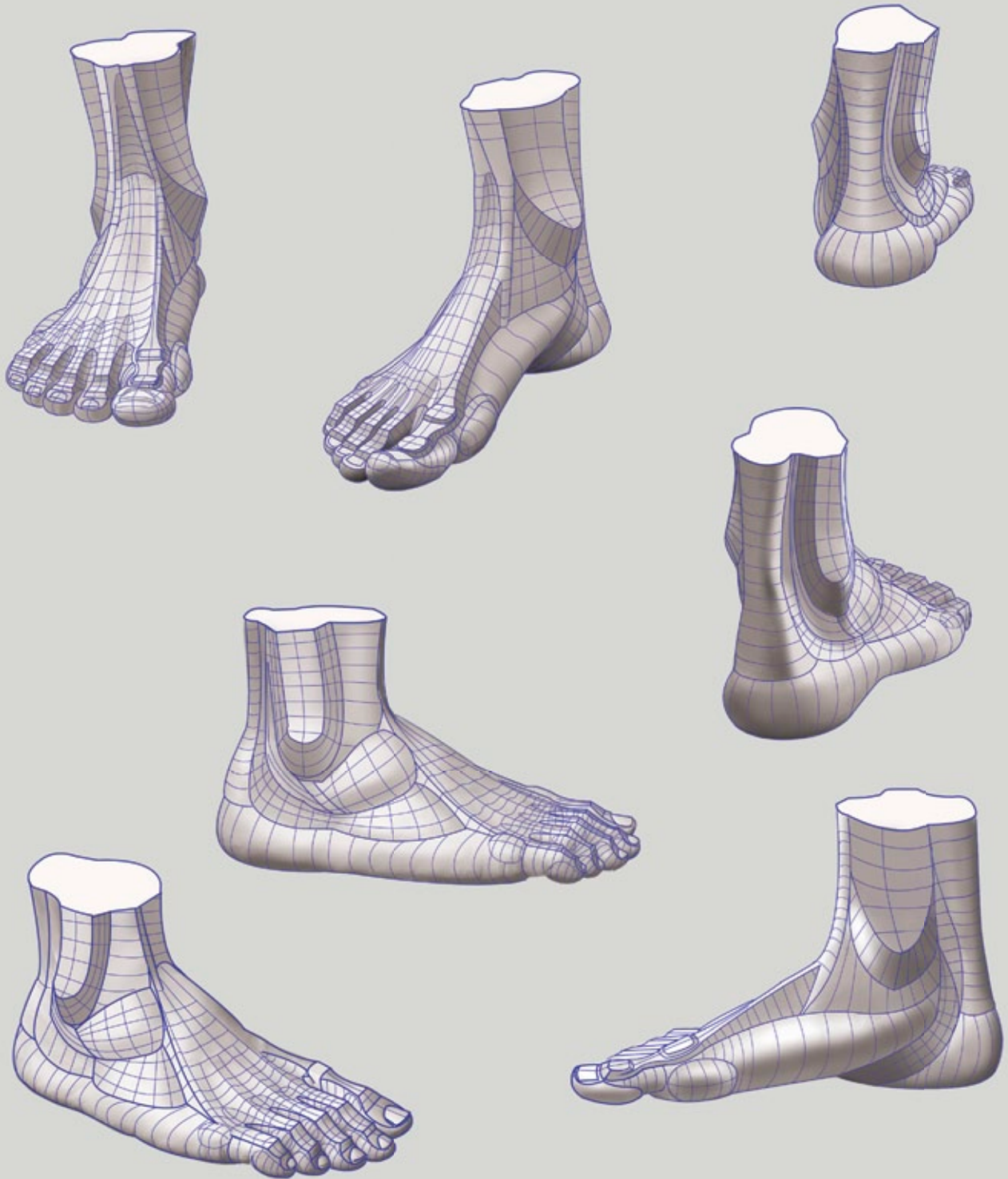INNER PORTIONS OF THE CALF MUSCLES ARE LOCATED LOWER AND SHAPES ARE MORE ROUND AND MASSIVE THAN THE OUTER PORTION.

FOOT MUSCLES



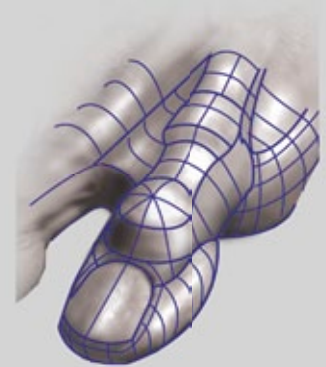
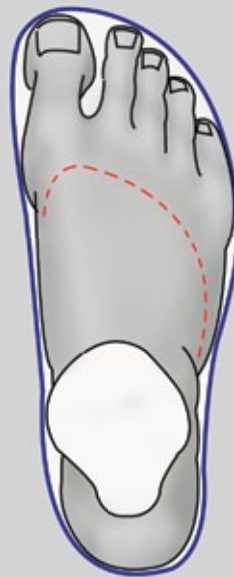
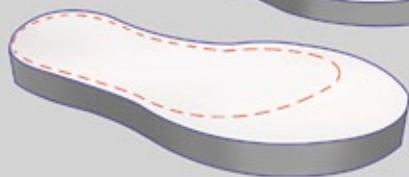
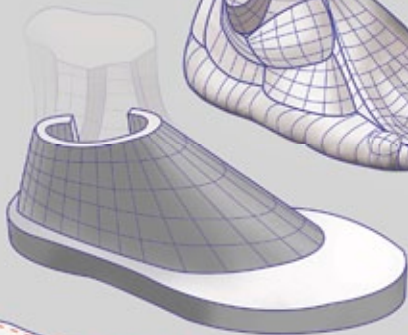
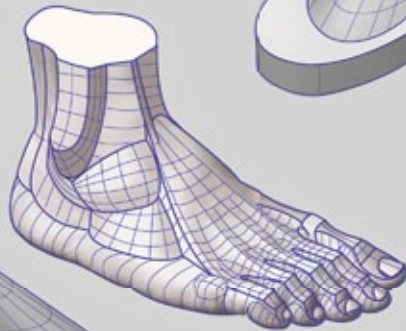
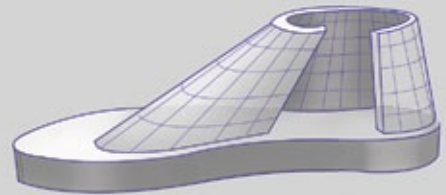
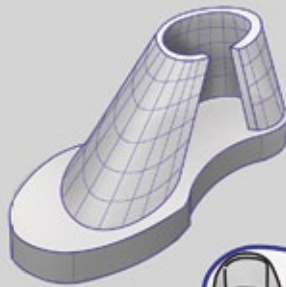
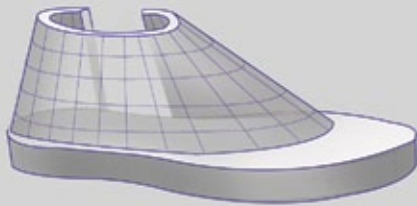
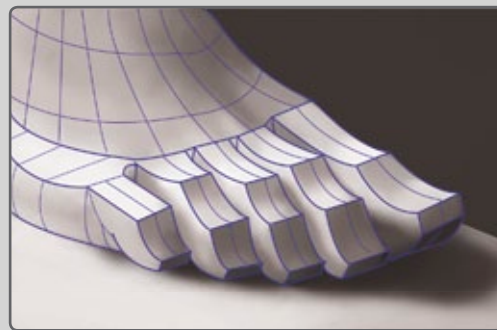
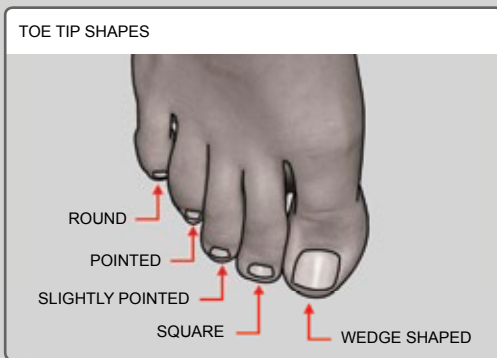
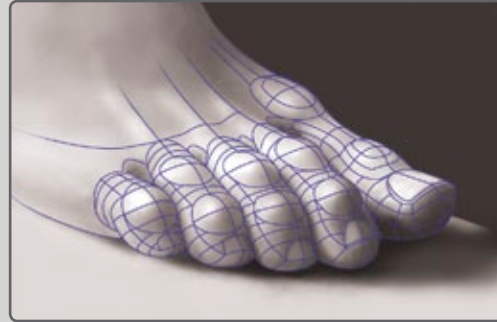
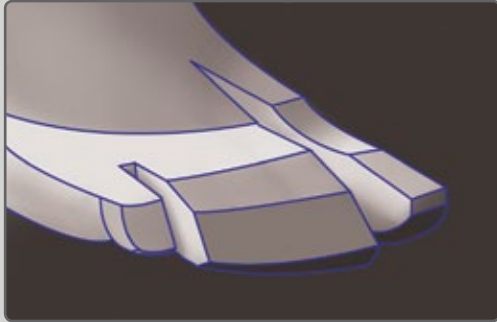
- | | | |
|--------------------------------|------------------------------|----------------------------|
| 1 PERONEUS LONGUS | 8 EXTENSOR HALLUCIS LONGUS | 15 SOLEUS |
| 2 PERONEUS BREVIS | 9 EXTENSOR HALLUCIS BREVIS | 16 FAT PAD |
| 3 EXTENSOR DIGITORUM LONGUS | 10 EXTENSOR DIGITORUM BREVIS | 17 TIBIALIS POSTERIOR |
| 4 TIBIALIS ANTERIOR | 11 PERONEUS TERTIUS | 18 FLEXOR DIGITORUM LONGUS |
| 5 MEDIAL SURFACE OF TIBIA BONE | 12 ABDUCTOR DIGITI MINIMI | 19 ABDUCTOR HALLUCIS |
| 6 MEDIAL ANKLE (M. MALLEOLUS) | 13 FLEXOR HALLUCIS LONGUS | 20 ACHILLES TENDON |
| 7 LATERAL ANKLE (L. MALLEOLUS) | 14 GASTROCNEMIUS | 21 CALCANEUS BONE |

FOOT SHAPES

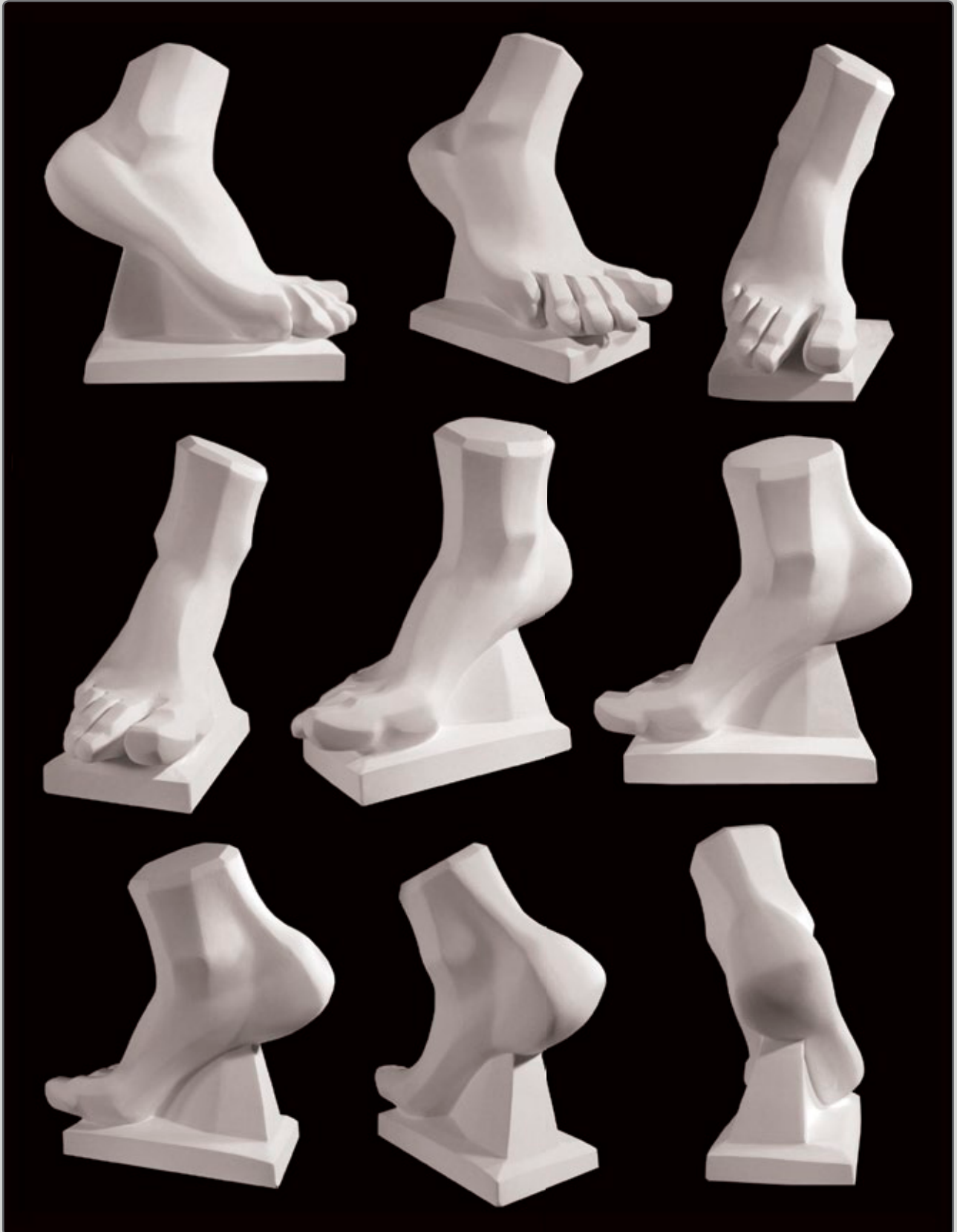


RIGHT FOOT

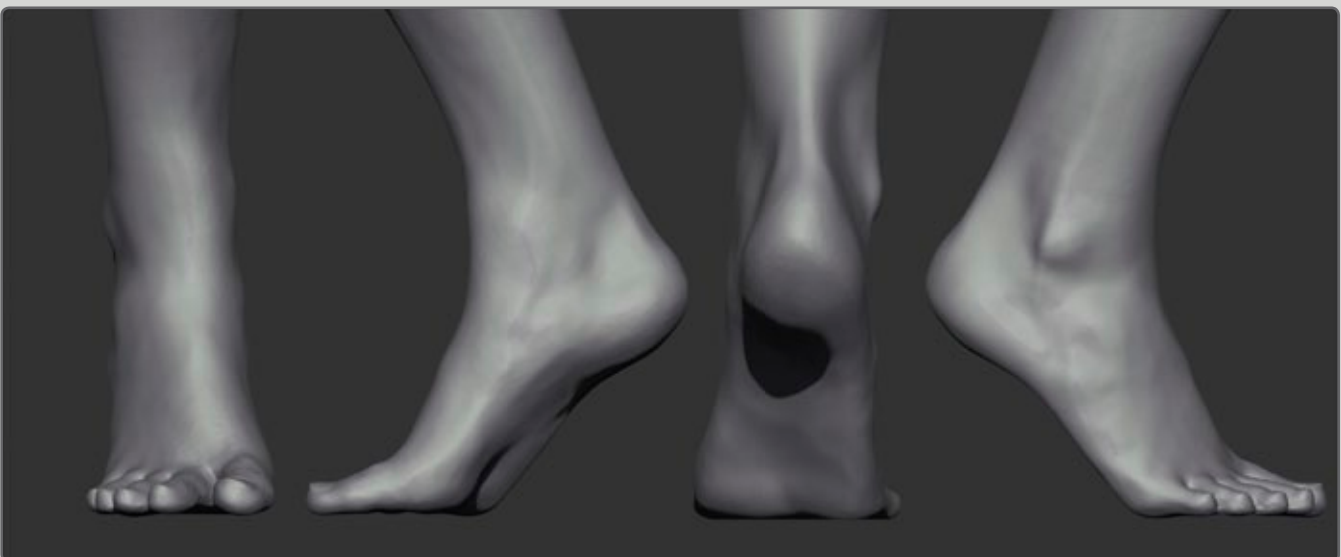
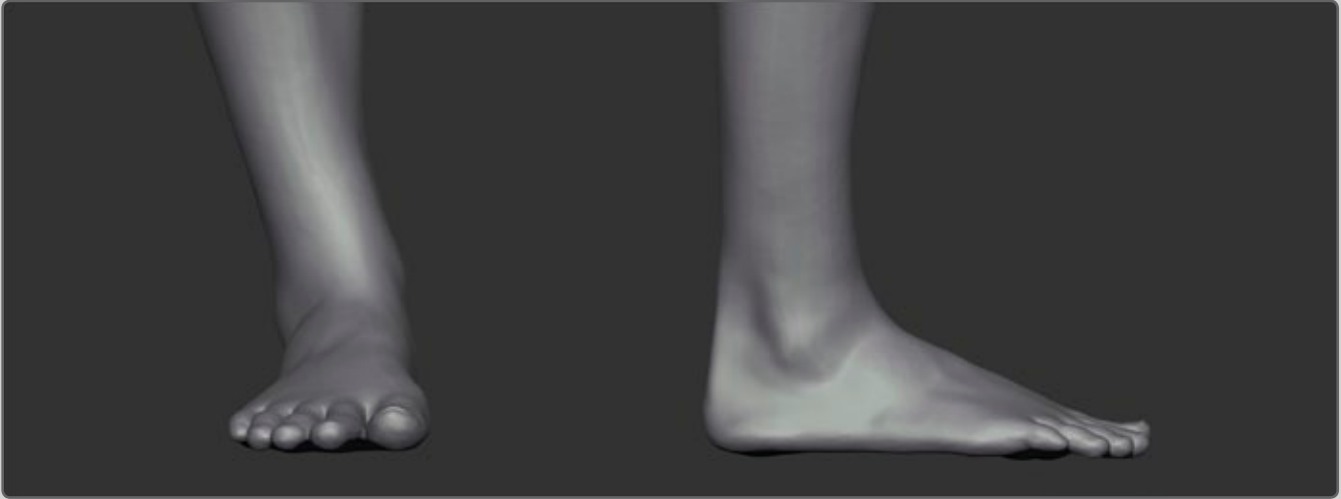
FOOT SHAPES AND FORMING A FOOT



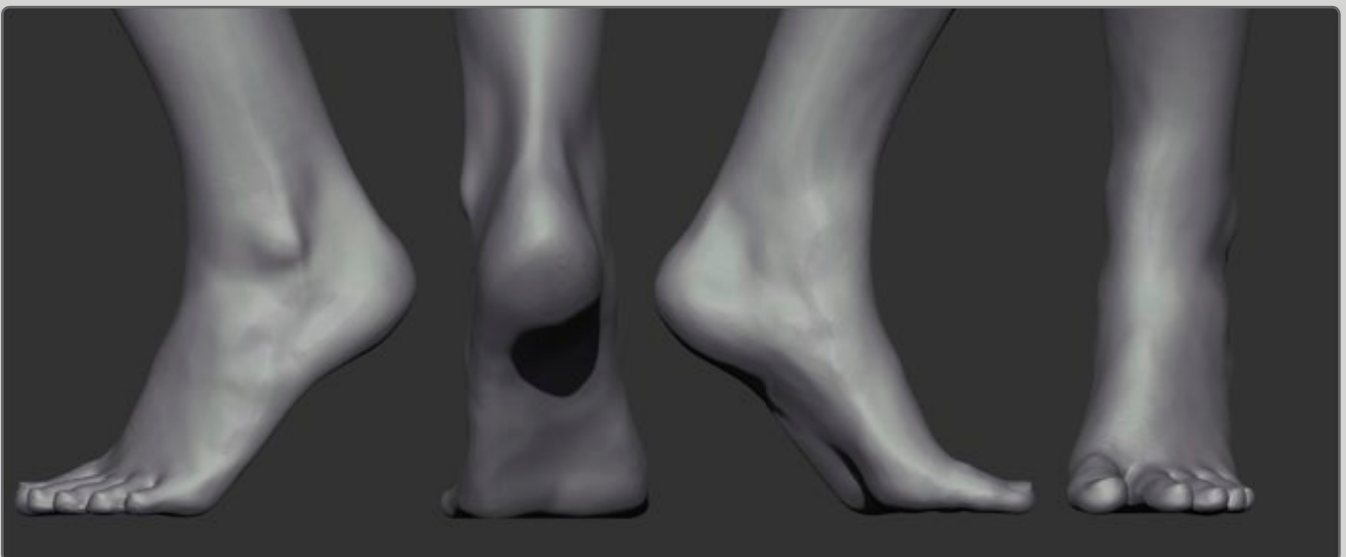
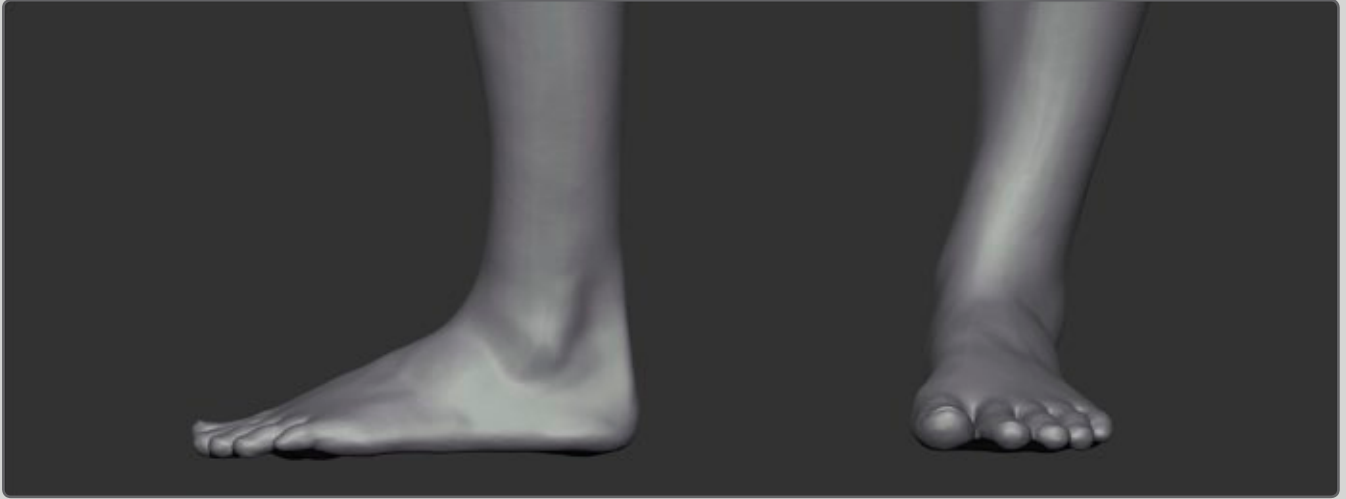
BLOCKING OUT A FOOT



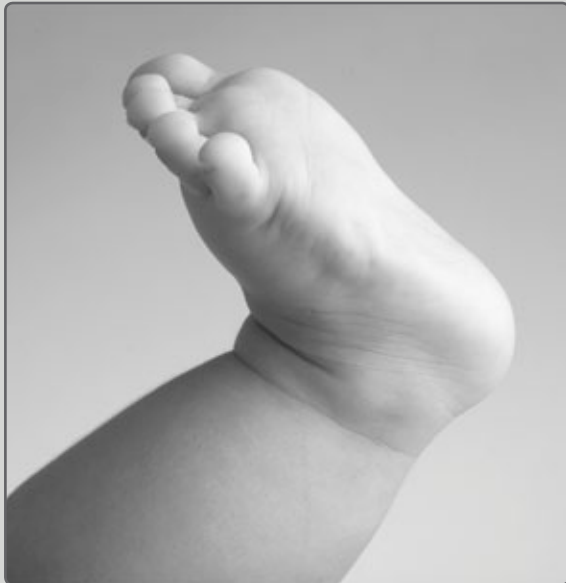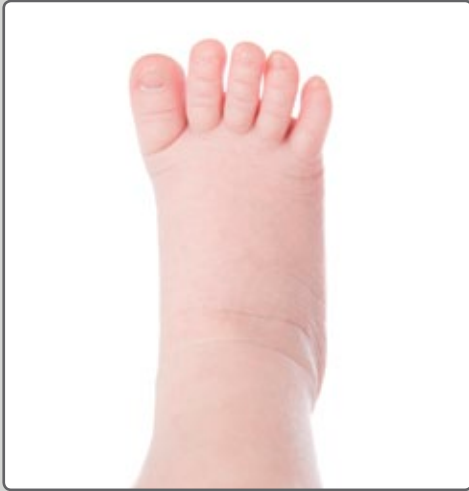3D SCAN OF RIGHT FOOT



3D SCAN OF LEFT FOOT



BABY FEET



INDEX

- "Adam's apple" 97
 "Rhombus of Michaelis" 55
 "S"-Shape 16, 33, 53
 A.S.I.S Anterior Superior Iliac Spine 10, 11, 26, 188, 189, 192, 193
 Abdomen 22, 28
 Abdominal wall fat pad 57, 58
 Achilles tendon 188, 189, 201, 216
 Acromion process 10,11,43
 Adductor tubercle of femur 198
 Anterior tibial condyle 202
 Areola 37
 Armpit 36
 Arms 14
 Bicipital aponeurosis 156
 Block-out 20,21, 54, 101, 106, 172
 Body shapes 13
 Bony landmarks 9
 Bony triangle 36
 Breast fat pad 57, 58
 Breasts 13, 37,38, 39,40
 Buttocks 13
 Chest 13
 Composition 15
 Contrapposto 16
 Coracoid process 156, 160
 Coronoid process of ulna 160, 166-168
 Costal Margin 11, 29
 Deltoid tuberosity of Humerus 43
 Ear 121
 Écorché 24
 Emotions 132-142
 Epicranial aponeurosis 95
 Extensor retinaculum 144, 145
 Eye 103-109
 Eyeball 103
 Eyebrows 103
 Fat accumulation 62
 Figure 25
 Flank fat pad 56, 57, 58, 59
 Foot 14, 216-222
 Forced pronation 153
 Forehead 12
 Glenohumeral joint 160
 Gluteal band 56, 59
 Greater trochanter 188, 189, 192, 194
 Hand 14
 Head 14
 Head of fibula 207
 Head units 19
 Hips 14,16,54
 Iliac crest 10,11,28, 53,54
 Iliac crest line 22
 Iliotibial band 188, 189
 Ilium 196
 Inferior gluteal fat extension 56, 58, 59
 Infraclavicular fossa 36
 Infraclavicular triangle 36
 Infraglenoid tubercle of scapula 158
 Infrapatellar fat pad 56, 57, 58, 207
 Inner thigh fat pad 57, 59
 ischial tuberosity 199
 Ishiopubic ramus 198
 Jawline 102, 110
 Jaws 12, 110
 Landmarks 9
 Laryngeal prominence 97
 Lateral epicondyle of femur 192, 207
 Lateral epicondyle of humerus 164
 Lateral gluteal fat pad 56, 58, 59
 Lateral malleolus (lateral ankle) 188, 189, 192, 215, 216
 Lateral tibial condyle 188, 189, 192, 207
 Lazy-"S" 17
 Legs 14,16
 Linea aspera 198, 199
 Lobules 37
 Lower anterior thigh fat pad 57, 58
 Lower back 55
 Mastoid process 94
 Medial epicondyle of femur 192
 Medial malleolus (medial ankle) 188, 189, 192, 205, 215, 216
 Medial tibial condyle 188, 189, 192
 Mouth 111-116
 Movable masses 18,19, 22
 Nail 145, 178, 179
 Navel 13
 Nipple 37,38,39
 Node 113
 Nose 122, 123
 Nostril 123
 Olecranon process of Ulna 158, 164
 Outer thigh fat pad 57, 58, 59
 P.S.I.S Posterior Superior Iliac Spine 10,11, 27, 189, 192, 193
 Palmar aponeurosis 166-168
 Parotid gland 97, 110
 Patellar ligament 188, 189, 207
 Pectineal line of femur 198
 Pectineal line of pubis 198
 Pectoral fat pad 56
 Pes anserinus 198, 199
 Popliteal fat pad 56, 58, 59
 Posterior gluteal fat pad 56, 58, 59
 Pronation 148, 149, 152, 165
 Proportions 19, 90-92, 126-130, 177
 Pubic crest 198
 Pubic fat pad 56, 57
 Pubic symphysis 54
 Quadriceps tendon 207
 Radial deviation (abduction) 180
 Radial sulcus 158
 Radial tuberosity 156
 Richer's band 188,189
 Root (Radix) 123
 Salivary gland 110
 Semipronation 151
 Septum 123
 Shoulder joint 52
 Shoulders 14
 Silhouette 15
 Skin 13, 37
 Skin Fat 13
 Subcutaneous fat pad 37,54, 55, 56, 57,58, 59, 194
 Subcutaneous points 9
 Supination 148, 149, 150, 165
 Supracondylar ridge 162
 Supraglenoid tuberosity 156
 Supraorbital ridges 12
 Symmetry 15
 Temporal line 12, 94, 102, 103
 Thumb 178, 179
 Thyroid gland 97
 Tibial tuberosity 188, 189, 192, 207
 Torso 10,11, 20, 21
 Trachea 97
 Tuberosity of ischium 198
 Ulnar deviation (adduction) 180
 Waist 14
 Wing (Alar) 123
 Wing of ilium 10, 11, 28
 Wrinkles 125
- BONES:**
- 7th Vertebrae 27, 118
 Bones of foot 187
 Bones of lower limbs 186
 Breastbone 9,11,34,96
 Calcaneus 187, 192, 216
 Capitate 146
 Chest bone 9
 Clavicle 9,10,11,26,27,33,34,35,36,45,96
 Collarbone 9,10,11,26,27,33,34,35,36,45,96
 Cuboid 187
 Distal phalanges 146, 187
 Femur 186, 196, 207
 Fibula 186, 205, 207
 Frontal 94
 Glabella 12
 Hamate 146
 Hand and wrist bones 146
 Head of Ulna 144, 145, 147, 180
 Heel bone 187, 192, 216
 Hipbone 9,10,11,12,26,27,28
 Humerus 36,43,52, 148, 155, 156, 158, 162, 169
 Hyoid 96, 97
 Intermediate cuneiform 187
 Knee cap (Patella) 186, 188, 189, 192, 196, 207
 Lateral cuneiform 187
 Lunate 146
 Mandible 94,96, 110
 Maxilla 94
 Medial cuneiform 187
 Medial epicondyle of Humerus 166-168
 Metacarpals 146
 Metatarsals 187
 Middle phalanges 146, 187
 Nasal 94
 Navicular 187
 Occipital 94
 Orbit 12, 103
 Parietal 94
 Pelvis 9,10,11,12,53, 193
 Phalanx 146
 Pisiform 144, 146, 167, 180
 Proximal phalanges 146, 187
 Radius 148, 155, 156, 158, 162, 169
 Rib cage 10,11,12,28
 Ribs 37,48

Scapula 9,10,11,26,27,89,96, 158
 Shoulderblade
 Skeleton 8,9,12
 Skull 12, 94, 98, 99
 Sphenoid 94
 Spine 10,11
 Spine of scapula 27
 Sternum 9,11,34,96
 Talus 187
 Temporal 94
 Thoracic cage 10,11,12,28
 Thorax 10,11,12,28
 Tibia 186, 196, 202, 205, 207
 Trapezium 146
 Trapezoid 146
 Triquetral 146
 Ulna 148, 155, 156, 158, 162, 169, 170, 175
 Zygomatic 94,95
 Zygomatic arch 95, 110

MUSCLES:

Abdominal muscles 28,29
 Abductor digiti minimi 144, 145, 216
 Abductor hallucis 216
 Abductor pollicis brevis 144, 145
 Abductor pollicis longus 27, 144, 145, 147, 169
 ABS 26, 28, 29
 Adductor longus 188, 189, 198
 Adductor magnus 188, 189, 198
 Adductor pollicis 144, 145
 Anconeus 27, 147, 164
 Biceps brachii 26,27,147, 155, 156, 157
 Biceps femoris 188, 189, 199
 Brachialis 26,27, 147, 160, 161
 Brachioradialis 26, 27, 144, 145, 147, 162, 163
 Broadest back muscle 26,27,50
 Buccinator 95
 Calf 188, 189, 201, 216
 Chest muscle 26,27,30,33,34,35,36,37,45
 Coracobrachialis 147, 160, 161
 Corrugator 95
 Cricothyroid 97
 Deltoid 26,27,30,32,33,34,36,42,43,44,45, 147
 Depressor anguli oris 95
 Depressor labii inferioris 95
 Digastric 97
 Dorsal interossei muscles 145
 Erector spinae 50
 Extensor carpi radialis brevis 27, 145, 147
 Extensor carpi radialis longus 27, 145, 147, 162, 163
 Extensor carpi ulnaris 27, 144, 145, 164
 Extensor digiti minimi 145, 147, 164
 Extensor digitorum 27, 145, 164
 Extensor digitorum brevis 216
 Extensor digitorum longus 188, 189, 202, 216
 Extensor hallucis brevis 216
 Extensor hallucis longus 188, 189, 216
 External oblique 26,27, 28, 30, 31, 53

Facial muscles 124
 Flank muscle 26, 27, 28, 30, 31, 53
 Flexor carpi radialis 26, 144, 145, 147, 166-168
 Flexor carpi ulnaris 27, 144, 145, 147, 166-168
 Flexor digiti minimi brevis 144, 145
 Flexor digitorum longus 188, 189, 216
 Flexor digitorum superficialis 144, 145, 147
 Flexor pollicis brevis 144,145, 147, 169
 Frontalis 95
 Gastrocnemius 188, 189, 201, 216
 Gluteus maximus 27, 188, 189
 Gluteus medius 188, 189
 Gracilis 188, 189, 198
 Hamstrings 199, 204
 Hand and wrist muscles 144, 145
 Head muscles 95
 Hyoglossus 97
 Iliopsoas 188, 189
 Infrapinatus 27, 52
 Internal abdominal oblique 28
 Latissimus dorsi 26, 27, 50
 Levator labii superioris 95
 Levator scapulae 97
 Lumbricals 144, 145
 Masseter 95,97, 110
 Mentalis 95
 Muscles of lower limb 188, 189
 Muscles of torso 26-33
 Mylohyoid 97
 Nasalis 95
 Neck muscles 96, 97
 Occipitalis 95
 Omohyoid 97
 Opponens pollicis 144, 145
 Orbicularis oculi 95
 Orbicularis oris 95
 Otto's muscle 95
 Palmaris brevis 144, 145
 Palmaris longus 144, 145, 147, 166-168
 Pectineus 188, 189, 198
 Pectoralis major 26, 27, 30, 33, 34, 35, 36, 37, 45
 Pectoralis minor 35, 37
 Peroneus brevis 188, 189, 203, 216
 Peroneus longus 188, 189, 203, 216
 Peroneus tertius 188, 189, 216
 Platysma 117
 Procerus 95
 Pronator teres 26, 147, 166-168
 Quadriceps 188, 189, 196
 Rectus abdominis 26, 28,29
 Rectus abdominis 28,29
 Rectus femoris 188, 189, 196, 207
 Rhomboid major 27
 Risorius 95
 Sartorius 188, 189, 197
 Saw muscle 26,48,49
 Scalenus anterior 97
 Scalenus medius 97
 Scalenus posterior 97
 Semimembranosus 188, 189, 199
 Semispinalis capitis 97
 Semitendinosus 188, 189, 199

Serratus anterior 26,48,49
 Six-pack 28,29
 Soleus 188, 189, 201, 216
 Splenius capitis 97
 Sternocleidomastoid 26,27,96,97, 118, 119, 120
 Sternohyoid 97
 Sternothyroid 97
 Stylohyoid 97
 Suprahyoid muscles 102
 Temporalis 95, 102, 110
 Tensor fasciae latae 188, 189
 Teres major 27, 50, 52
 Teres minor 27,52
 Tibialis anterior 188, 189, 202, 216
 Tibialis posterior 216
 Transversus abdominis 28
 Trapezius 26,27,30,32,33,46,96,97, 119, 120
 Triceps brachii 26,27,41, 147, 155, 158
 Vastus intermedius 196
 Vastus lateralis 188, 189, 196, 207
 Vastus medialis 188, 189, 196, 207
 Wrist extensors 149, 165, 175
 Wrist flexors 149, 165, 166-168, 175
 Zygomaticus major 95
 Zygomaticus minor 95

IMAGES CREDITS

(SHUTTERSTOCK)

Warren, Goldswain, 90142621, 90096421
Sebastian, Kaulitzki, 149965676
149965781, 149965727,
151423058, 130092965,
130092941, 149965790,
Jessmine, 117845515,
64484938, 64481641,
117466771, 117466276,
117466264, 117845521
Naturesports, 78467605
Bayanova, Svetlana, 111461918,
110833442
Hein, Nouwens, 96170264
videodocotr, 132651080
Jonathan, Feinstein, 55878313
Nomad, Soul, 93524935
Warren, Goldswain, 62395870
Vue, 40254340
Ronald Summers, 10960006
Ostila, 14865017
alett, 57482818
Kuttelvaserova Stuchelova,
102217774
Piotr, Marcinski, 66205318
Mykhaylo, Palinchak,
135266447
Shuravaya, 92796607,
DJTaylor, 127760321,
lekcoj, 132107012
Mykhaylo, Palinchak,
133078430
Inga, Marchuk, 148184015
oly, 127373738
doglikehorse, 82312213,
laroslav, Nelliubov, 87812053
Helder, Almeida, 73550245
MaleWitch, 48167611
Gusep, 110880
dreamerve, 113072752
Kafonia, Aliaksei, 132480443
Costazturza, 56400217
Tatiana, Makotra, 111593462
Sergey, Mironov, 64570630
Denis, Pepin, 975538
Chad, Zuber, 81691177
Joshua, Resnick, 8330860
George, Muresan, 85930732
tanislav, Fridkin, 71181355
Carlos, Caetano, 45122581
damato, 134224493
Lana, K, 90288790
Alan, Bailey, 126181058
yurok, 5410969
windu, 68560594
Syda, Productions, 90817505
Dedyukhin, Dmitry, 65411122
Subbotina, Anna, 125307737
ARENA, Creative, 53914663
YuryZhuravov, 79329139
AJP, 81447517
marcogarrincha, 111032450
Sofi, photo, 133387154
William, Perugini, 91137608,
91137608
Xiaojiao, Wang, 84857713
Robert, Kneschke, 46317160
Alan, Poulson, Photography,
39265951
Denis, Pepin, 50059336
Maksym, Bondarchuk,
85539439
YorkBerlin, 51940567
Alan, Bailey, 126179492
oly, 95054386, 98139272,
116560987, 115103842,
125102741, 94663945,
93807922, 94663954,
93808090, 94663906,
94663975, 126009794,
124797709, 93752899,
125153480, 111131864
Zdorov, Kirill, Vladimirovich,
33974851
marcogarrincha, 127177706
CREATISTIA, 8661502
William, Perugini, 83391154
Bojia, Andreu, 105517841
Creativemarc, 147231275
Aspen, Photo, 94440007
Sanzhar, Murzin, 72845692
Victor, Newman, 19802044
Gorich, 17694211
sam100, 472914, 472912,
712065, 712062, 717898,
717890, 717889, 717889,
717885, 717887
MARSIL, 5789050
Hein, Nouwens, 98545544
ostila, 56259355
Nomad, Soul, 80069689
Warren, Goldswain, 90142603
Aaron, Amat, 99071363
NinaMalyna, 93202033
Nomad, Soul, 102945767,
144129199
Yeko, Photo, Studio, 128487161
Bevan, Goldswain, 123900769

Dan, Kosmayer, 124890325,
124912316, 124898642,
124925690
Warren, Goldswain, 62323036,
62371285, 62444041
Dan, Kosmayer, 124320916,
124320919, 124321279,
124317997
schankz, 96468725
KULISH, VIKTORIIA,
123856489, 123856489
Aleksandr, Markin, 85582952
Marcell, Mizik, 125010791
Elena, Kharichkina, 52284313
Eky, Studio, 60572491,
5431071
Vladimir, Wrangel, 12441757
Janna, Bantan, 97383932
vishstudio, 54725959
iofoto, 3160102
O.L.J. Studio, 45691366
Oleg, Mit, 69238201
Viala, Vitally, 6010267
bikeriderlondon, 122456650,
122456653, 122456641,
122456647, 122456638
steve, estvanik, 90487690
Robert, Kneschke, 46430419
sezer66, 135003521
inxtil, 95080585
Khamidulin, 10911556
Vikacita, 102467513
eAlisa, 105596630, 105596633
Kalcutta, 140991940
carlo, dapino, 16832836
Louis, W, 19469767
Piotr, Marcinski, 90142303
Aaron, Amat, 66987235
Dmitry, Lobanov, 145526410
Sero, 143200726, 143200708
rem, 110345522
Vadym, Zaitsev, 117927676
julias, 142584553
Oleksii, Sagitov, 81766204
Praisang, 117990130
Dmitry, Naumov, 29436907
Stanislav, Popov, 62523448
nit, 112947532
Zurijeta, 112947532
inxtil, 95080585
schankz, 127089758
Praisang, 123171661
Sementer, 134986943
Hannamaria, 76297324
Dmitry, Naumov, 27592462
Olga, Nikonova, 12697919
Alexey, Losevich, 133365359
Nomad, Soul, 98375987
Photobac, 135651539
szefei, 112430531
Nate, Allred, 55656739
Thorsten, Schmitt, 89107843
Quan, Yin, 15798718
Vitalinka, 100348361
PavelAnFotodos, 10037467
SvetlanaFedoseyeva, 46941928
Flashon, Studio, 83828884
Giuseppe, R, 63399670
Khamidulin, Sergey, 67382611
Koroleva, Katerina, 59773162
Mike, Tan, 66141739
Hannamaria, 112791160
nikkos, 128463791
Oksana, Kuzmina, 124726813
Sarachai, 98262190
Flashon, Studio, 103998416
Luis, Louro, 78481036
In, Green, 136475681
Oleksii, Khamyz, 88582219
postoil, 82399513
Inga, Marchuk, 5254398
asylsun, 100493958
Max, Bukovski, 103574327,
115992457, 103574267,
103574327
Hannamaria, 76297324
Flashon, Studio, 84783586
Ana, Blazic, Pavlovic, 87949297
Velazquez277, 107279963
postoil, 90889808,
Bevan, Goldswain, 105417869
szefei, 98595605
serg, dibrova, 10613648,
129193622
Aaron, Amat, 93831046,
88359478
bikeriderlondon, 144915292,
144914482
AJP, 533997115
doglikehorse, 49778341,
49778338, 49778398
Timothy, Boomer, 74689858
Refat, 144808208, 52914331,
38227024, 38442484,
77810734
Zastolskiy, Victor, 40567864
Daniel, Gale, 13940824
Dundanim, 44063488

Alexander, Mak, 86350783
luxorphoto, 68239186
Elena, Ray, 661302
Zurijeta, 69116677
Kuttelvaserova, Stuchelova,
107349326
iodrakon, 1828294
Warren, Goldswain, 62371276,
62323000
Anna, Lurye, 62395804
Sergiy, Telesh, 62395804
Aleksandr, Todorovic,
61064692
AJP, 55389220
Forster, Forest, 33255931
Kuzma, 38378068, 63929794
ChameleonsEye, 115577692
Oleg, Golovnev, 147241340
Sandra.Matic, 129019715
Khamidulin, Sergey, 116857471
Ayakovlev, 4949932
Maksim, Shmeljov, 86482771
Zhernosek, FFMstudio.com,
103060244
iofoto, 3226404
Piotr, Marcinski, 31948714
44205058, 38194312,
98473775, 84929041
AXL, 31948714
Todd, Kuhns, 59770861,
59770870, 59770864
ArtFamily, 124432360
Lana, K, 93898561, 98120972,
100152506, 93898381,
93898378, 98120948,
93813823, 93813832,
98120945
Nomad, Soul, 113083900,
114014062
Ase, 99025028
iofoto, 3160808
Andrei, Shumskiy, 88876774
Jochen, Schoenfeld, 94676488
Astaforov, 68666050,
68666056, 68650279,
67821814, 67741320
George, Allen, Penton, 3257724
valdis, tomos, 60985117
Sergieiev, 84811939
Oleg, Mit, 67138873
Hermann, Danzmayr, 310347
jeka, 40329715
Shots, Studio, 116083300
vita, khorzhevka, 121731133
120892262, 120882310,
144497953
Elena, Kharichkina, 90098173
lablonskyi, Mykola, 110840702,
125974517, 91203760
O.L.J. Studio, 70157024
leolintang, 108579308
Kozachenko, Oleksandr,
114875779, 114875749,
114875752
matka, Wariata, 34116832
nanka, 13903318
Geo, Martinez, 274127
vishstudio, 69574723
stihii, 119687509, 141240655
Dundanim, 47032852
Cleomiu, 17586670
MAKENBOLJU, 148822124
David, Davis, 2098801
Kokhanchikov, 38159932
hartphotography, 49547803
Timur, Kulgarin, 34385119
Hugo, Felix, 136090493
Alan, Bailey, 126968855
Lana, Langlois, 65826652
nanka, 11785402
Christo, 59119813, 59119819,
59119807
Suzanne, Tucker, 1321449
Warren, Goldswain, 62371354
624443999
Dektofenak, 121368253
rangizzz, 125847749
Violand, 134275850
Dan, Kosmayer, 124784974,
124782820, 122024042,
122024002
oly, 98507627, 101007865,
98139272
Photobac, 76018261
Isantilli, 126522221
Jessmine, 96225569, 96198590
Fatseyeva, 98660858
Olinchuk, 148247585
Jkpargeter, 65487289
violetblue, 78869944,
131827028
Juriah, Mosin, 956664
somchai, 62692903
iko, 75874852, 76814590,
75874867, 76814665,
80006443
hartphotography, 51858520

Horst, Petzold, 94209688
Sergieiev, 82760317
ArturNyk, 131505737,
132891266
upthebanner, 59227513
Kletr, 88913938
bikeriderlondon, 122049238,
110933405, 147841997
Kletr, 129612107
Luis, Louro, 78226891
Kokhanchikov, 38159935
29712238, 51129436,
66129568, 30315178,
31617010
eelnoosiva, 138749075
ZouZou, 72063973
MaxFX, 42114472, 22119046
Kzenon, 129836039
Alan, Bailey, 126174785
postoil, 106193234, 93084466,
95135101
Boonsom, 92967964
Victor, V.Hoguns, Zhugin,
57337156, 56069317
Warren, Goldswain, 62326027
Hasloo, Group, Production,
Studio, 84060625
Kaponia, Aliaksei, 130919744
wtamas, 63709325
Elena, Kharichkina, 108823715
Valua, Vitally, 115693456,
4634093993, 21003097
David, David, 2077001,
2077089, 20776672, 2076667,
2076748, 2077331
Mikhail, Vorotnikov, 2429207
Bernhard, Richter, 28722796
simpleman, 95740441
Sergiy, Telesh, 79615684,
79636525, 79271062
Maxim, Kalmayko, 28977712
28977721, 70652293,
70606951, 120400272,
28977718
iko, 77772673, 97302827
William, Perugini, 84814474
bikeriderlondon, 149428529
Serhiy, Kobyakov, 71001646
icsnaps, 147786557, 147766070
Eugenio, Marongiu, 126027872
tommaso, lizzul, 106845431
ArtFamily, 124432360,
134849492
YanLue, 65835514
Sebastian, Kaulitzki, 130094879
vishstudio, 113660927
Dektofenak, 61714966
tommaso, lizzul, 17189454,
75189451, 134739695,
103418333, 68948665
Dmitry, Bruskov, 125408216
Dmitry, Bruskov, 125070723,
127487615, 127487612,
127487627
Sasharijeka, 52363684
vishstudio, 101073673,
58290025, 76555699
oly, 105117029, 123005791,
91811378, 123005701,
89863132, 95544481,
71358556
Louis, W, 13940698
Igor, Kireev, 71428998
FXQuadro, 71341019
luxora, 35682727
wang, song, 124547809
CURAPhotography, 1042753321
In, Green, 128661260
Mayer, George, 135668174,
146504588
Belovodchenko, Anton,
124849435
Dundanim, 27603112
Aaron, Amat, 83175736
alessandro0770, 75684934
Sebastian, Kaulitzki, 133427252
R, O, M, A, 100985506
DRAGONFLY, STUDIO,
90702166
Draw05, 136054685
Vladimir, Korostyushevskiy,
110612435
bikeriderlondon, 144403021,
144570887
Alexander, Image, 149135501
Uros, Jonic, 131892440
Belovodchenko, Anton,
130980335,
Robert, Kneschke, 46446019
margo, black, 104257925
CURAPhotography, 128052461
Sergey, Dubrov, 73364230
Lucky, Business, 94820398
Levichev, Dmitry, 52367506
Guryanov, Andrey, 121658866
Daniel, M, Nagy, 81984739
Vibrant, Image, Studio,

68242369
lablonskyi, Mykola, 68606581
Artgo, 69883066
Malakhova, Ganna, 132921032
Oksana, Kuzmina, 131219351,
124726813
greiss, design, 146514278
aniad, 66312775
Ocskay, Bence, 44899549
Kletr, 67947757, 76760608,
75166060
Eric, Issele, 3567765
Luis, Louro, 73300603
sunabesou, 138970757
eelnoosiva, 138807854
Chris, Harvey, 1773480
Andreas, Meyer, 31321123
Tinydevil, 94287730, 94287712
Spectral, Design, 66526930
CURAphotography, 79745983
Anetta, 41354335
Irisksa, 62809405
Tatyana, Vyc, 35406931
Ronald, van der, Beek, 5825719
Mihai, Simion, 15643963
SH, Vector, 137517479
vishstudio, 130162256,
72123028, 76555699,
127868365
holbox, 123446350
Aleksey, Klints, 46925731
conde, 47773348
Kamira, 52796635, 92579641
PerseoMedusa, 86306503
Chanclous, 9028370, 93048880
javarman, 46340962
gogh73, 148497206
conde, 49361215
Kletr, 76760611
irakite, 32486428
Malgorzata, Kistryn, 148989921
rebirth3d, 72389452
abxyz, 130948268
voyloydon, 44557759
ndphoto, 137194166, 137194163
GlebStok, 129528308
Katrina, Elena, 146677214
aastock, 132065747
LoloStok, 1249093899,
129728291
paffy, 109371149
lenetstan, 84422258
damato, 128977808
cristovao, 135674684
Fesus, Robert, 17154814
Baloncini, 58064004
ladjasavic, 9841456
Photobac, 106285127
William, Havenaar, 110823767
Sergieiev, 113493250
Sebastian, Kaulitzki, 126579557
Sementer, 144883762,
144883771
Dundanim, 25353145
Vasilchenko, Nikita, 95523337
vishstudio, 130300763,
142746520, 100875295,
127868369, 95061643,
95061445, 127868372
Philip, Date, 190015
Hein, Nouwens, 96170261
Sebastian, Kaulitzki, 120819521,
130094843
percom, 115599847
alexwhite, 125790008,
125789990, 144606533,
125789936, 127068665,
126343718, 127726292
Alexandr, Shebanov, 920178
Piotr, Marcinski, 74535925,
76533238, 40915099
Eldad, Carin, 135692660
Sergieiev, 104672387
Sebastian, Kaulitzki, 128575907,
128575973, 128575865,
128575868
leo, ello, calvetti, 89696491
decades3d, 128708983,
128697350
CLIPAREA, I, Custom, media,
130713542, 130713533
Sebastian, Kaulitzki, 128575298,
128575384, 130095269,
130095167, 128573051
Potapov, Alexander, 131849297,
Mariya, Ermolaeva, 118737772
gresli, 94395274
mexrix, 73744534
v.s.anandhakrishna, 116582779
Samuel, Micut, 93065095
pisapography, 107117294
Praisang, 120751945
imgagedb.com, 144366610
wonderisland, 116574748,
116574772, 140830465,
143865949
Michal, Vitek, 144927160
Nomad, Soul, 80397598

Mayer, George, 15244612
samodelkin8, 98868017,
7500972
Anton, Zabelskiy, 25114882,
25114888
Alexei, Tacu, 115821382,
115821379, 115821376,
115821376
Piotr, Marcinski, 84909685,
105628688, 38194330,
38194315, 85844866
AleX, Studio, Z, 132903422
Maslov, Dmitry, 53316211
iofoto, 3154664
gregg, Cerenzio, 183867
Serg, Zastavkin, 113626030
Sean, Nel, 145249483
Jeff, Thrower, 112401821,
Pavel, L, Photo, and, Video,
120235651
salajeon, 147467363
Bairachnyi, Dmitry, 70276336,
72068845, 69233110,
69447340
AXL, 98208059, 95739112
Maksim, Shmeljov, 52107052,
62671336, 63029314,
63747613
Piotr, Marcinski, 11652797,
118532794, 38194330,
38194315
Jeff, Thrower, 114156706,
114156715
Action, Sports, Photography,
56848450
lablonskyi, Mykola, 111343364,
111343376
Igor, Kireev, 92182354
Falcona, 107724995
vishstudio, 113504449,
142746529, 142746523,
142746520
AleX, Studio, Z, 128654051,
128654021
O.L.J. Studio, 65187949,
83170411, 54332347
Anetta, 48991999
InnervisionArt, 112247789,
140418397
Sergieiev, 138036872
FXQuadro, 136191587,
89394811
Petrenko, Andriy, 130469996
Andriy, Solovyov, 3601669
matka, Wariata, 9885190
Pressmaster, 4250929
4250938, 4250932
vishstudio, 42119887, 42119857,
105197285
Jessmine, 117890494
Anetta, 41354320, 48819106,
41421901, 48819091
Iakov, Filimonov, 44014663
lablonskyi, Mykola, 64748125
Igor, Kireev, 76388302,
82353619, 82353637
Pressmaster, 82368864
Catalin, Petolea, 8687866
oly, 89863132
T, Anderson, 93698323
CURAPhotography, 104513321
Stefania, Mohr, Photography,
105197285
Martin, Valigursky, 109132289
Vladimir, Wrangel, 115657222
Solovyova, Lyudmyla,
122970343
Luca, Elvira, 123976450
Hank, Shiffman, 129511613
138699461, 138699452,
138699491, 138822731
Anetta, 41421910
Dave, Kotinsky, 130505138
Ase, 98901398, 98901398
cristovao, 140156585
Alend, 141052373
rangizzz, 141067915
Undrey, 140790025
Guryanov, Andrey, 140540572
Hank, Shiffman, 141654913,
141654919
Kruglov, Orda, 143080630,
144070609
Kiselev, Andrey, Valerevich,
143238061
sassysock, 143635654
hemail, 144680255, 144680264,
145542805, 145542811,
145542817
Guryanov, Andrey, 145681490
Vibrant, Image, Studio,
145034443
PutlichD, 144048916,
144048889
Kiselev, Andrey, Valerevich,
144438340
Syda, Productions, 144887467



Anatomy for Sculptors
is a product of Exonicus LLC,
a multi-talented international team of
sculptors, graphic designers, photographers,
programmers, and artists of all backgrounds.

Our expertise spans from small-scale single projects to
multiple large-scale public events and corporate clients.

We develop, organize and execute projects of our own.

We also partner with companies to provide them with services which
include illustration, web coding, photography, and graphic design for
trade shows, retail promotions, marketing campaigns, conferences,
festivals and fairs, movie premiers, grand openings, and corporate
team-building events.

For more information, visit our website:
www.exonicus.com

ULDIS ZARINS
WITH
SANDIS KONDRATS

ANATOMY FOR SCULPTORS

UNDERSTANDING THE HUMAN FIGURE

Knowing all the muscles doesn't mean understanding its form!

Are you searching for an anatomy book with clear images and little text?
Do you have trouble beginning to model figures? Are you looking for clear reference images and are fed up with browsing the web? Do you want to learn the shapes and apply the know-how immediately to your project rather than reading endless texts about muscles and bones?

**” THIS IS THE MOST EASY-TO-USE
HUMAN ANATOMY GUIDE FOR ARTISTS,
EXPLAINING THE HUMAN BODY
IN A SIMPLE MANNER.**

The book contains keys to figuring out construction in a direct, easy-to-follow, and highly visual manner. Art students, 3D sculptors and illustrators alike will find this manual a practical foundation upon which to build their knowledge of anatomy – an essential background for anyone wishing to draw or sculpt easily and with confidence!

In this book you will find the most the important muscles, functions and actions of the human body. Over 1000 drawings illustrate the range from simple anatomy studies to more complex tutorials. More than 250 photos have been drawn over, revealing the muscles.

The author is award-winning professional sculptor with real life experience.